

Case Report

국소 겔질스테로이드 주사 후 발생한 지방위축증

충북대학교 의과대학 신경과학교실

김인하 · 이혜림 · 이상수

Two Cases of Lipoatrophy after Local Corticosteroid Injection

Inha Kim, Hye Lim Lee, Sang-Soo Lee

Department of Neurology, Chungbuk National University College of Medicine, Cheongju, Korea

The adverse effects of systemic steroid medications are well known, whereas those of local steroid injections are unclear even to clinicians. We report two cases of localized lipoatrophy and depigmentation following local steroid injection. Although the incidence of soft tissue atrophy after local steroid injection is rare, it will increase in proportion to the frequency of the procedure. All clinicians, even those who do not perform steroid injections, should be aware of the occurrence of this cosmetically disturbing adverse effect. (Korean J Clin Neurophysiol 2015;17:91-94)

Key Words: Corticosteroid, Lipoatrophy, Triamcinolone

Received 31 July 2015; received in revised form 25 November 2015; accepted 30 November 2015.

Local corticosteroid injections are frequently included as treatment options in clinical guidelines in the field of musculoskeletal disorders, such as rheumatic arthritis, synovitis, bursitis, epicondylitis, ligament sprain, tendinitis, neuromas, ganglion cysts, entrapment syndromes, fasciitis, acute athletic injuries, and back pain.¹⁻³ In general, the adverse effects of systemic corticosteroid treatment are well known to the public, whereas those of local corticosteroid injection, which have remarkably increased in use, are not relatively familiar even to clinicians. Ignorance of such adverse effects can be a potential threat to misdiagnosis. We describe two women who suffered disfiguring subcutaneous atrophy and depigmentation from a

triamcinolone injection given for local soft tissue pain.

Case Report

1. Patient 1

A 43-year-old woman was referred to our clinic with a 4-month history of depressed skin and numbness on the back of the right hand. She had a local triamcinolone injection around the right first metacarpal joint to alleviate pain from a right radial collateral ligament injury 4 months ago. Examination revealed atrophy of the skin, hypopigmentation, and hypoaesthesia in the right first dorsal interosseous area without intrinsic hand muscle weakness (Fig. 1). Electrodiagnostic studies were obtained to exclude a neuropathy like an ulnar nerve lesion. Nerve conduction study and needle electromyography revealed no abnormalities. Based on the history of a local steroid injection with normal electrophysiological studies, a clinical diagnosis of a post-injection localized lipoatrophy and

Address for correspondence;

Sang-Soo Lee

Department of Neurology, Chungbuk National University College of Medicine, 1 Chungdae-ro Seowon-Gu, Cheongju 28644, Korea

Tel: +82-43-269-6336 Fax: +82-43-275-7591

E-mail: pnsdoctor@gmail.com

Copyright 2015 by The Korean Society of Clinical Neurophysiology

This is an Open Access article distributed under the terms of the Creative Commons Attribution Non-Commercial License (<http://creativecommons.org/licenses/by-nc/3.0>) which permits unrestricted non-commercial use, distribution, and reproduction in any medium, provided the original work is properly cited.

depigmentation was made. The soft tissue atrophy resolved a year later without specific treatment.

2. Patient 2

An 18-year-old female visited our neurology clinic with a 3-month history of wasting in her left medial foot. Her major

was Korean traditional dance and she had spent about 10 hours a day for practicing. Despite the wasting of her left foot, she had no difficulty dancing as before. She had been treated for a presumed plantar fasciitis with local triamcinolone injection around the medial sole of her left foot 4 months ago. Examination revealed remarkable thin skin, tissue atrophy, and

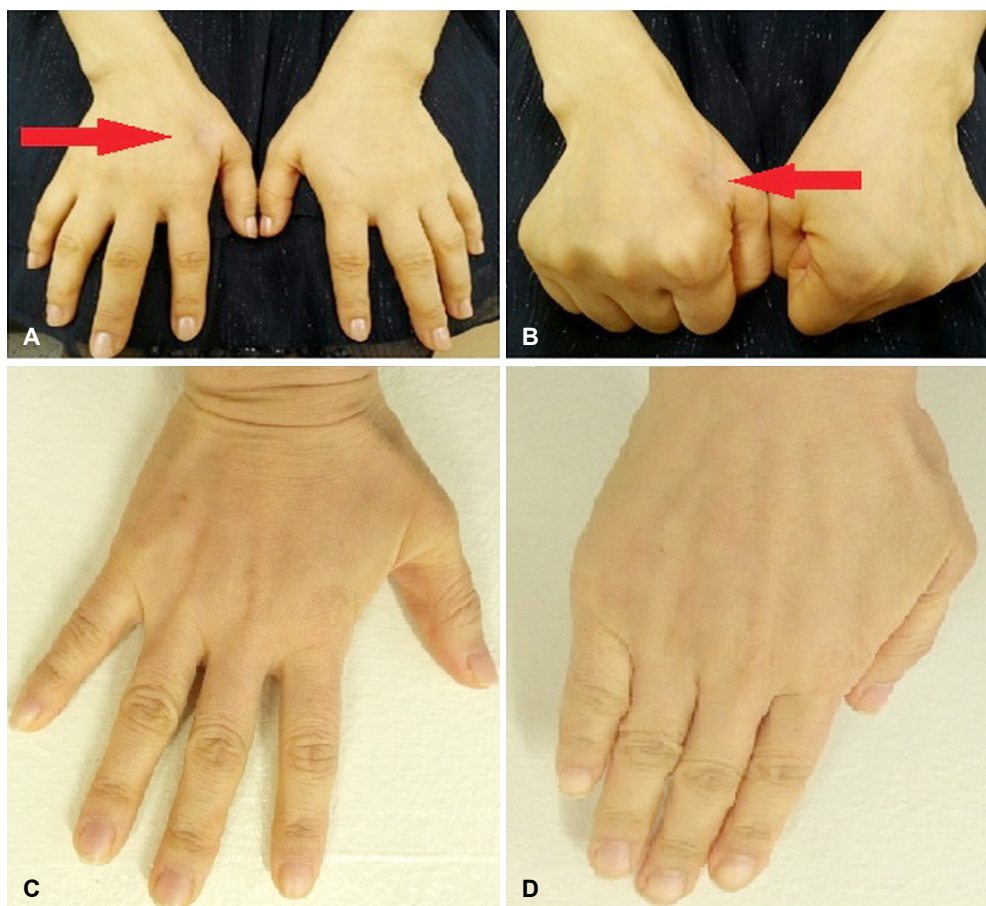


Figure 1. Appearance of steroid induced atrophy and hypopigmentation (arrow) of the right dorsum of hand after triamcinolone injection (A, B). Spontaneously improved skin lesion a year later (C, D).

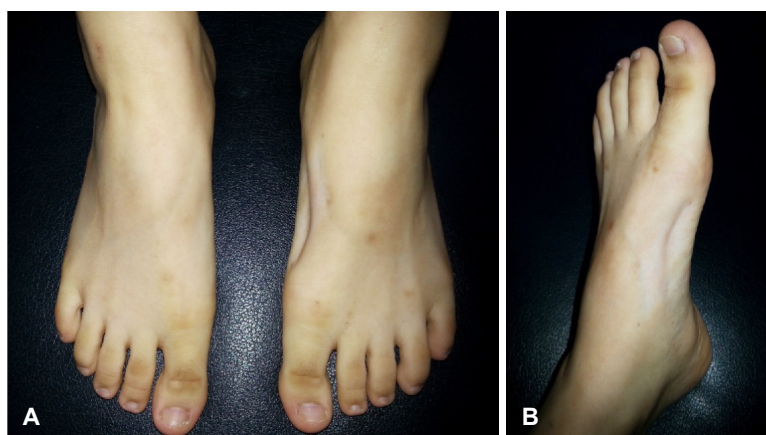


Figure 2. Appearance of steroid induced atrophy and hypopigmentation of the left medial foot after triamcinolone injection (A, B).

depigmentation between the navicular prominence and sole (Fig. 2). Motor and sensory examinations were normal. Electrodiagnostic studies were performed but found no distal tibial neuropathy. Needle electromyography disclosed no abnormalities. Like the previous case, a clinical diagnosis of steroid-induced local lipoatrophy and depigmentation was made. Two years after the last injection, the atrophy remained unaltered without weakness.

Conclusion

Steroid injection has been a well-established medical procedure in treating various pathological conditions with proven efficacy. Injectable steroids are easy to administer, allow direct delivery to the pathologic site, and result in decreased systemic side effects. However, a review of the literature revealed many cases of transient or permanent skin and subcutaneous atrophy following local injections of corticosteroid in the treatment of different lesions.¹⁻⁴ Although subcutaneous atrophy and depigmentation after local corticosteroid injection have been variably reported from 0.6-40%,^{2,3} it will increase in proportion to the frequency of the procedure. The incidence, extent, and time course of subcutaneous atrophy seem to depend on the type, solubility, and concentration of the corticosteroid preparation and the depth and anatomical level of the injection.^{1,4,5} Skin atrophy may occur more often with triamcinolone than with hydrocortisone use. It generally appears in 2 weeks to 4 months and resolves 6 to 30 months later in the majority of cases.⁶

The precise cause of the dermal atrophy produced by corticosteroids is unknown. Several mechanisms have been suggested. The most accepted mechanism is the lymphatic spread of the corticosteroid suspension and resultant atrophy of the dermal and epidermal tissues.^{7,8} Cells and tissues are constantly bathed in interstitial fluid in order to maintain tissue homeostasis. The majority of the water, ions, and other freely diffusible small molecules exit via the venous capillary bed, whereas the lymphatics remove macromolecules and large proteins. Flow within lymphatic vessels is unidirectional because of a valve system and low pressure in the lymphatic lumen.⁹ In the presence of normal or low concentrations of corticosteroids, most of the corticosteroid is bound to plasma proteins, corticosteroid-binding globulin, or albumin. However, when the steroid concen-

tration increases, the protein binding capacity is exceeded and a fraction of the steroid exists in the free state, allowing it to enter cells and mediate corticosteroid effects. Triamcinolone acetate is a macromolecule, microcrystalline ester that dissolves slowly in order to achieve a prolonged effect.¹⁰ Therefore, it is postulated that triamcinolone acetate suspended crystals enter and spread along lymphatic channels thus causing the linear ray distribution pattern. Another proposed mechanism is a corticosteroid-induced vasoconstriction, especially when administered locally in high concentrations. This enhanced vasoconstriction may facilitate local thrombosis or embolization and capillary closure with resultant local tissue hypoxia. These effects then produce local tissue atrophy, or, in extreme cases, necrosis.¹¹ Histologic study showed activated macrophages engulfing segments of altered adipose and stromal tissue.⁴ Molecular in vivo study suggested that dexamethasone interferes with both the synthesis and degradation of type I collagen, and more drastically, type III collagen, which provides the molecular basis for skin atrophy caused by glucocorticoid treatment.⁵ The mechanism of steroid-induced hypopigmentation, however, is not well understood, but a decrease in melanocyte function rather than actual loss of melanocytes was suggested.¹² Patients with darker skin are at greater risk of depigmentation.

There is a remarkable female predominance in other series of patients with lipoatrophy after corticosteroid injection including ours. It is difficult to explain immunologically. Lipoatrophy seems to be more obviously visible in women, in whom there is more subcutaneous fat tissue available for dramatic changes.¹³

Many clinicians classify these dermal adverse effects as 'trivial' and leave them out of consideration because lipoatrophy improves or completely heals naturally within a year in the majority of patients. However, patients need to be told about the potential for rare but cosmetically significant cutaneous complications when consenting for such procedures. Moreover, clinicians who do not perform local corticosteroid injections should be familiar with the iatrogenic lipoatrophy and depigmentation that can occur, to prevent misdiagnosis of peripheral nerve lesions in neurology clinic without taking a detailed history.

REFERENCES

1. Cole BJ, Schumacher HR Jr. Injectable corticosteroids in modern practice. *J Am Acad Orthop Surg* 2005;13:37-46.

2. Kumar N, Newman RJ. Complications of intra- and peri-articular steroid injections. *Br J Gen Pract* 1999;49:465-466.
3. Price R, Sinclair H, Heinrich I, Gibson T. Local injection treatment of tennis elbow-hydrocortisone, triamcinolone and lignocaine compared. *Rheumatol* 1991;30:39-44.
4. Ahmed I. Post-injection involutional lipoatrophy: ultrastructural evidence for an activated macrophage phenotype and macrophage related involution of adipocytes. *Am J Dermatopathol* 2006;28: 334-337.
5. Oishi Y, Fu ZW, Ohnuki Y, Kato H, Noguchi T. Molecular basis of the alteration in skin collagen metabolism in response to in vivo dexamethasone treatment: effects on the synthesis of collagen type I and III, collagenase, and tissue inhibitors of metalloproteinases. *Br J Dermatol* 2002;147: 859-868.
6. Schetman D, Hambrick GW Jr, Wilson CE. Cutaneous changes following local injection of triamcinolone. *Arch Dermatol* 1963; 88:820-828.
7. Firooz A, Tehranchi-Nia Z, Ahmed AR. Benefits and risks of intralesional corticosteroid injection in the treatment of dermatological diseases. *Clin Exp Dermatol* 1995;20:363-370.
8. Say EA, Shields CL, Bianciotto C, Shields JA. Perilymphatic subcutaneous fat atrophy and cutaneous depigmentation after periocular triamcinolone acetonide injection in a child. *J AAPOS* 2011; 15:107-108.
9. Ryan TJ, Mortimer PS, Jones RL. Lymphatics of the skin. Neglected but important. *Int J Dermatol* 1986;25:411-419.
10. Chembolli L, Rai R, Srinivas CR. Depigmentation along lymphatic channels following intralesional corticosteroid injection. *Indian J Dermatol* 2008;53:210-211.
11. Droste PJ, Ellis FD, Sondhi N, Helveston EM. Linear subcutaneous fat atrophy after corticosteroid injection of periocular hemangiomas. *Am J Ophthalmol* 1988;105:65-69.
12. Venkatesan P, Fangman WL. Linear hypopigmentation and cutaneous atrophy following intra-articular steroid injections for de Quervain's tendonitis. *J Drugs Dermatol* 2009;8:492-493.
13. Reeves WG, Allen BR, Tattersall RB. Insulin-induced lipoatrophy: evidence for an immune pathogenesis. *Br Med J* 1980;280:1500-1503.