

## Spontaneous Lumbar Artery Bleeding and Retroperitoneal Hematoma in a Patient Treated with Continuous Renal Replacement Therapy

Jin Kyung Park, M.D.<sup>1</sup>, Sung Ho Kim, M.D.<sup>1</sup>, Hee Jin Kim, M.D.<sup>2</sup>, and Duk Hyun Lee, M.D.<sup>1</sup>

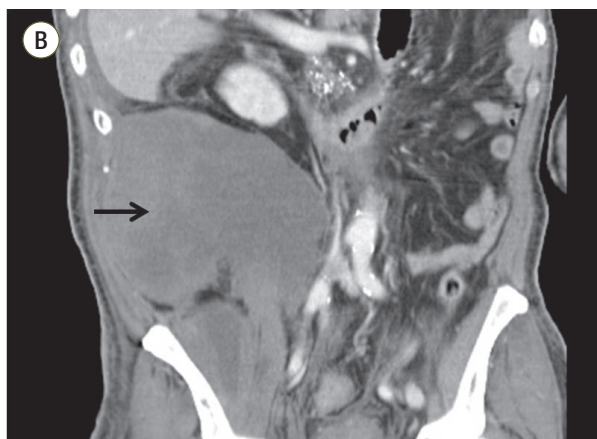
<sup>1</sup>Department of Internal Medicine, <sup>2</sup>Department of Radiology, Daegu Fatima Hospital, Daegu, Korea

2015 November 30(4):318-322 / <http://dx.doi.org/10.4266/kjccm.2015.30.4.318>

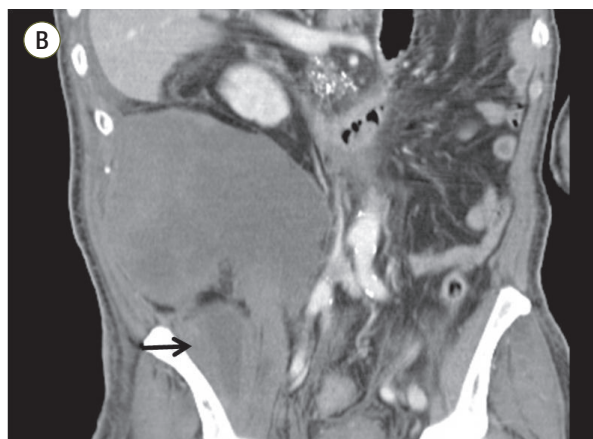
We found an error in this article. The Fig. 2B should be corrected as following:

In this article, on page 319, Fig. 2B has an error. The position of its arrow was wrong.  
We present the correct figure as below:

**Before correction**



**After correction**



We apologize for any inconvenience that may have caused.