

## Persistent Left Superior Vena Cava Detected Incidentally after Pulmonary Artery Catheterization

Hyun Jeong Lee, M.D.<sup>\*</sup>, Namoo Kim, M.D.<sup>\*</sup>, Hyelin Lee, M.D.<sup>\*</sup>, Jae Kwang Shim, M.D.<sup>\*†</sup>,  
and Jong Wook Song, M.D., Ph.D.<sup>\*†</sup>

<sup>\*</sup>Department of Anesthesiology and Pain Medicine, <sup>†</sup>Anesthesia and Pain Research Institute, Yonsei University College of Medicine, Seoul, Korea

We present a case of pulmonary artery catheter (PAC) placement through the right internal jugular vein, bridging vein and coronary sinus in a patient with previously unrecognized persistent left superior vena cava (LSVC) and diminutive right superior vena cava. A 61-year-old male patient was scheduled for mitral valve repair for regurgitation. Preoperative transthoracic echocardiography revealed dilated coronary sinus, but no further evaluations were performed. During advancement of the PAC, right ventricular and pulmonary arterial pressure tracing was observed at 50 and 60 cm, respectively. Transesophageal echocardiography ruled out intra-cardiac knotting and revealed the presence of the PAC in the LSVC, entering the right ventricle from the coronary sinus. Diminutive right superior vena cava was observed after sternotomy. The PAC was left in place for 2 days postoperatively without any complications. This case emphasizes that the possibility of LSVC and associated anomalies should always be ruled out in patients with dilated coronary sinus.

**Key Words:** catheterization, Swan-Ganz; vascular malformations; vena cava, superior.

Persistent left superior vena cava (LSVC) is a common anomaly of the thoracic venous system with incidences of 0.3–0.5% in general population and 3–10% in patients with congenital heart disease.[1] Persistent LSVC is usually asymptomatic and found incidentally during imaging study or cardiovascular procedure. Catheterization into the right side of heart is challenging in patients with persistent LSVC, particularly when a left subclavian vein is chosen for a vascular access site. Since most of the patients with persistent LSVC also have a normal right superior vena cava (RSVC), catheterization through right internal jugular vein is seldom complicating. However, in rare instances, regression of a caudal right superior cardinal vein during embryological development leads to persistent LSVC with absent RSVC.[2]

We present a case of pulmonary artery catheter (PAC) placement through right internal jugular vein, bridging vein and coronary sinus in patient with previously unrecognized persistent LSVC and diminutive right superior vena cava.

### Case Report

A 61-year-old male patient was scheduled for mitral valve repair due to regurgitation under cardiopulmonary bypass. He was 169 cm tall and weighed 69 kg. The patient's prior history was unremarkable except hypertension for which he received calcium channel blocker and beta blocker. His

Received on July 14, 2014    Revised on December 27, 2014

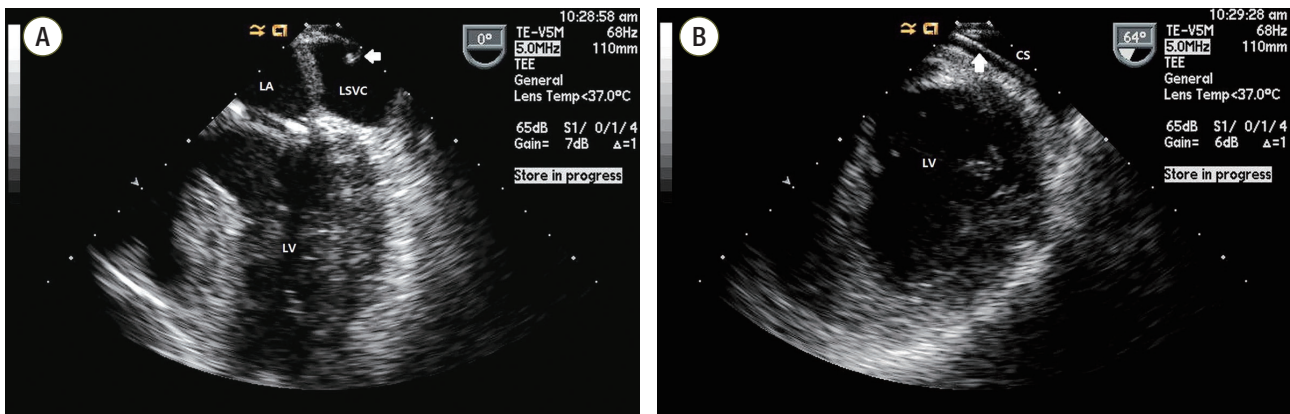
Accepted on December 27, 2014

**Correspondence to:** Jong Wook Song, Department of Anesthesiology and Pain Medicine, Anesthesia and Pain Research Institute, Yonsei University College of Medicine, 50 Yonsei-ro, Seodaemun-gu, Seoul 120-752, Korea  
Tel: +82-2-2228-8515, Fax: +82-2-364-2951  
E-mail: SJW72331@yuhs.ac

\*No potential conflict of interest relevant to this article was reported.

© This is an Open Access article distributed under the terms of the Creative Commons Attribution Non-Commercial License (<http://creativecommons.org/licenses/by-nc/3.0/>) which permits unrestricted non-commercial use, distribution, and reproduction in any medium, provided the original work is properly cited.

Copyright © 2015 The Korean Society of Critical Care Medicine

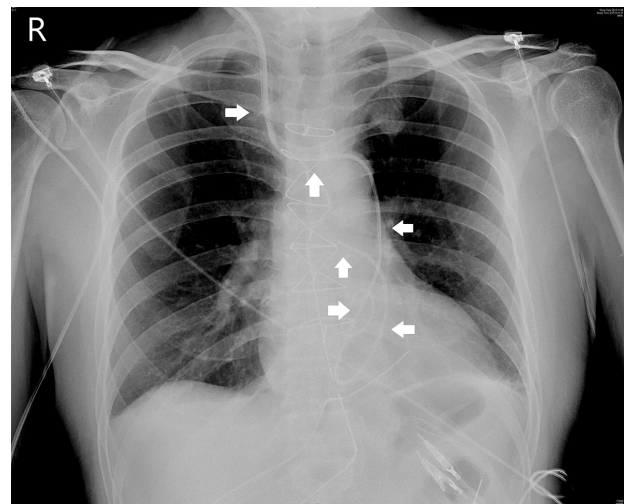


**Fig. 1.** Transesophageal echocardiography revealed the presence of the pulmonary artery catheter (white arrow) in the left superior vena cava (A) and coronary sinus (B). LA: left atrium; LV: left ventricle; LSVC: left superior vena cava; TEE: transthoracic echocardiography; CS: coronary sinus.

transthoracic echocardiography (TTE) showed prolapse of posterior mitral leaflet (mainly P2) and chordae rupture with eccentric severe mitral valve regurgitation of grade IV and dilated coronary sinus ( $2.6 \times 1.5$  cm). No congenital anomaly or intracardiac shunt were detected on TTE. Pre-operative TEE also showed no intracardiac mass or shunt. Chest X-ray and laboratory tests were within normal range. Electrocardiogram and holter test showed sinus rhythm with occasional premature atrial complexes. Preoperative coronary angiography revealed 70% luminal narrowing of first diagonal branch.

After anesthetic induction, PAC was inserted via multi-lumen central venous access catheter placed in the right internal jugular vein. During advancement of PAC, right ventricular and pulmonary arterial pressure tracing was observed at 50 and 60 cm, respectively. There was no significant resistance during the advancement of PAC. After the placement of PAC, TEE was inserted. TEE ruled out intracardiac knotting and revealed PAC in the LSVC, entering the right ventricle from the coronary sinus (Fig. 1A and Fig. 1B), and surgery was performed as planned. Mixed venous oxygen partial pressure and saturation were 46.9 mmHg and 82.3%, respectively, whereas the systemic arterial oxygen partial pressure and saturation were 212 mmHg and 99.9%, respectively, at an inspired oxygen fraction of 40% with air.

During the insertion of venous drainage cannula, diminutive RSVC was found and thus superior vena cava cannula was placed at the right atrium. After completion of surgery, weaning from cardiopulmonary bypass was uneventful.



**Fig. 2.** Postoperative chest x-ray showed the unusual path of the pulmonary artery catheter (white arrows), suggesting that the catheter passed through the right internal jugular vein, bridging vein, left superior vena cava, coronary sinus, right ventricle and pulmonary artery. R: right.

Postoperative chest x-ray showed unusual path of PAC, suggesting the catheter was passing through right internal jugular vein, bridging vein, LSVC, coronary sinus, right ventricle and pulmonary artery (Fig. 2).

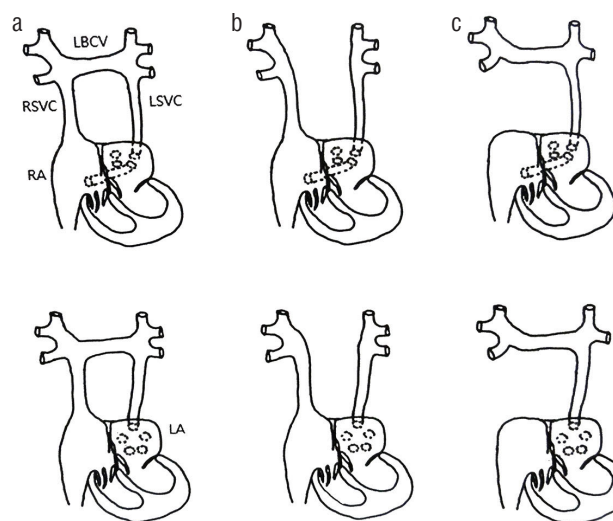
After the operation, he came into the intensive care unit (ICU) with the PAC placed. In the ICU, hemodynamic parameters were stable including pulmonary artery pressure and cardiac output. The drugs, such as dobutamine and milrinone was infused for several hours. Dobutamine started doses of  $4.88 \mu\text{g/kg/min}$  and were tapered after 6 hours, and

milrinone started doses of 0.49  $\mu$ g/kg/min and were tapered after 18 hours. The PAC was left in place for 24 hours post-operatively without any complications and removed. The next day of the operation, he was transferred to the general ward and discharged 10 days after operation.

## Discussion

Being a common congenital anomaly of the venous system, diagnosis of persistent LSVC is usually done incidentally during cardiovascular imaging study or surgery. A dilated coronary sinus on echocardiography suggests presence of persistent LSVC. Other causes of a coronary sinus dilatation includes elevated right atrial pressure and various abnormal venous communications such as partial anomalous pulmonary venous return, coronary arterio-venous fistula, and unroofed coronary sinus.[3] Echocardiography with bilateral agitated saline test can confirm the diagnosis of persistent LSVC. In normal patients with single RSVC, agitated saline bubbles injected from either left or right arm veins are firstly observed in the right atrium and subsequently in the right ventricle. As the bubbles disappear during the passage through pulmonary circulation, they are not detected in the coronary sinus. In case of persistent LSVC, agitated saline bubbles injected through a left arm vein firstly appear in the coronary sinus, followed by the right atrium and ventricle. In patients with persistent LSVC with absent RSVC, saline bubbles from both arm veins can be seen firstly in the coronary sinus. Agitated saline test is also useful for detecting unroofed coronary sinus. Other imaging modalities including angiography, magnetic resonance imaging or multislice computed tomography can be helpful for diagnosis of persistent LSVC and other accompanied anomaly of cardiovascular system.[4]

Persistent LSVC itself has usually no hemodynamic significance. However, the presence of persistent LSVC may have practical implications especially in the cardiac surgical setting. Without the beforehand knowledge of the complete vascular anatomy, the introduction of PAC may not be possible. Moreover, an attempt to insert a catheter and its manipulation in coronary sinus can result in life threatening condition such as angina, arrhythmia, cardiac tamponade and even cardiac arrest.[5] Also, persistent LSVC is a rela-



**Fig. 3.** Various presentations of persistent left superior vena cava. LBCV: left brachiocephalic vein; RSVC: right superior vena cava; LSVC: left superior vena cava; RA: right atrium; LA: left atrium.

tive contraindication to the injection of retrograde cardioplegia because of insufficient myocardial perfusion either with or without the presence of unroofed coronary sinus. The persistent LSVC can be clamped during the administration of retrograde cardioplegia, however, there may be some steal of cardioplegia solution through an accessory vein. During heart transplantation surgery, the coronary sinus should be dissected carefully to permit re-anastomosis of persistent LSVC to right atrium.[6,7]

Despite the technical difficulties and potential complications, the presence of persistent LSVC does not preclude the catheterization into right side of the heart, because of its various presentation (Fig. 3). Since majority of the patients with persistent LSVC have normal RSVC, vascular access via right internal jugular vein is seldom complicating. However, in patients with persistent LSVC with absent or diminutive RSVC such as this patient, introducing a catheter into right side of the heart via right internal jugular vein may be particularly challenging, or even impossible. In our patient, preoperative echocardiographic examination revealed dilated coronary sinus without any evidence of elevated right atrial pressure or congenital cardiac anomalies, suggesting a presence of persistent LSVC. However, further evaluation in that regard such as agitated saline test or magnetic resonance imaging was not performed in this case, be-

cause mitral valve repair does not require administration of retrograde cardioplegia and complete exclusion of venous drainage into right atrium during cardiopulmonary bypass. In addition, introducing PAC was attempted via right internal jugular vein because the incidence of persistent LSVC with absent or diminutive RSVC is quite rare and access via right internal jugular vein is relatively easier than left internal jugular vein. Fortunately, there was no significant resistance during the advancement of PAC through the acute angle between right internal jugular vein and bridging brachiocephalic vein, coronary sinus and its narrow opening into right atrium. However, the insertion of PAC through the vascular access site on right side is supposed to be extremely difficult in patients with persistent LSVC with absent or diminutive RSVC, and insertion via the left internal jugular vein might be more favorable.

Various problems have been encountered in patients with persistent LSVC according to the types. Arrhythmias may occur with a persistent LSVC and an absent RSVC. These include variable atrioventricular (AV) block or complete heart block, probably because the AV node in the embryo that originates at the junction of the left cardinal vein and the sinus venous is abnormal when the RSVC is absent.[8] In addition, the isolated persistent LSVC commonly enters the right atrium through an enlarged coronary sinus. It may rarely drain into the left atrium and causes cyanosis. Isolated persistent LSVC is most often detected incidentally when cardiac catheterization is performed from the arm, especially on the left arm. If the right superior cava is absent, the passage of the catheter into the right atrium is generally difficult by this approach. It is even more difficult to pass the catheter into the right ventricle.[9]

In such a context, it may be recommended that patients with dilated coronary sinus should undergo diagnostic evaluation for a presence of persistent LSVC before cardiac surgery. Furthermore, awareness of the presence of venous drainage anomaly may be also useful for assessing the risks and benefits of PAC insertion as well as choosing a proper vascular access site.[10-13]

In conclusion, a presence of persistent LSVC with absent or diminutive RSVC potentially complicates placement of PAC especially when right internal jugular vein is chosen for a vascular access site. This case emphasizes that the presence of LSVC and its associated anomalies should al-

ways be sought in patients with dilated coronary sinus.

## References

- 1) Giuliani-Poncini C, Perez MH, Cotting J, Hurni M, Sekarski N, Pfammatter JP, et al: Persistent left superior vena cava in cardiac congenital surgery. *Pediatr Cardiol* 2014; 35: 71-6.
- 2) Erdoğan M, Karakaş P, Uygur F, Meşe B, Yamak B, Bozkir MG: Persistent left superior vena cava: the anatomical and surgical importance. *West Indian Med J* 2007; 56: 72-6.
- 3) Voci P, Luzzi G, Agati L: Diagnosis of persistent left superior vena cava by multiplane transesophageal echocardiography. *Cardiologia* 1995; 40: 273-5.
- 4) Goyal SK, Punnam SR, Verma G, Ruberg FL: Persistent left superior vena cava: a case report and review of literature. *Cardiovasc Ultrasound* 2008; 6: 50.
- 5) Konvicka JJ, Villamaria FJ: Images in anesthesia: anesthetic implications of persistent left superior vena cava. *Can J Anaesth* 2005; 52: 805.
- 6) Nsah EN, Moore GW, Hutchins GM: Pathogenesis of persistent left superior vena cava with a coronary sinus connection. *Pediatr Pathol* 1991; 11: 261-9.
- 7) Oosawa M, Sakai A, Abe M, Hanayama N, Lin ZB, Kodera K: Repeat open heart surgery in a case associated with persistent left superior vena cava: a method of simple occlusion of L-SVC using an alternative extra-pericardial approach and retrograde cardioplegia. *Kyobu Geka* 1995; 48: 741-4.
- 8) Dhar P, Kaufman B, Doerfler M, Dadic P: Unusual course of a pulmonary artery catheter. *J Cardiothorac Vasc Anesth* 1998; 12: 487-9.
- 9) Huang SK: Persistent left superior vena cava in a man with ventricular fibrillation. *Chest* 1986; 89: 155-7.
- 10) Menéndez B, García del Valle S, Marcos RC, Azofra J, Gomez-Arnau J: Left superior vena cava: a vascular abnormality discovered following pulmonary artery catheterization. *Can J Anaesth* 1996; 43: 626-8.
- 11) Rose ME, Gross L, Protos A: Transvenous pacemaker implantation by way of an anomalous left superior vena cava. *J Thorac Cardiovasc Surg* 1971; 62: 965-6.
- 12) Roberts DH, Bellamy CM, Ramsdale DR: Implantation

of a dual chamber pacemaker in a patient with persistent left superior vena cava. *Int J Cardiol* 1992; 36: 242-3.

13) Meijboom WB, Vanderheyden M: Biventricular pacing

and persistent left superior vena cava. Case report and review of the literature. *Acta Cardiol* 2002; 57: 287-90.