

Direction of the J-Tip of the Guidewire to Decrease the Malposition Rate of an Internal Jugular Vein Catheter

Byeong jun Ahn, M.D., Sung Uk Cho, M.D., Won Joon Jeong, M.D., Yeon Ho You, M.D., Seung Ryu, M.D.,
Jin Woong Lee, M.D., In Sool Yoo, M.D., and Yong chul Cho, M.D.

Department of Emergency Medicine, College of Medicine, Chungnam National University Hospital, Daejeon, Korea

Background: We hypothesized that the direction of the J-tip of the guidewire during insertion into the internal jugular vein (IJV) might determine its ultimate location.

Methods: In this study, 300 patients between the ages of 18 and 99 years who required central venous catheterization via IJV in the emergency department enrolled for randomization. IJV catheterization was successful in 285 of 300 patients. An independent operator randomly prefixed the direction of the J-tip of the guidewire to one of three directions. Based on the direction of the J-tip, patients were allocated into three groups: the J-tip medial-directed group (Group A), the lateral-directed group (Group B), or the downward-directed group (Group C). Postoperative chest radiography was performed on all patients in order to visualize the location of the catheter tip. A catheter is considered malpositioned if it is not located in the superior vena cava or right atrium.

Results: Of the total malpositioned catheter tips (8 of 285; 2.8%), the majority (5 of 8; 62.5%) entered the contralateral subclavian vein, 2 (25.0%) were complicated by looping, and 1 (12.5%) entered the ipsilateral subclavian vein. According to the direction of the J-tip of the guidewire, the incidence of malpositioning of the catheter tip was 4 of 92 in Group A (4.3%), 4 of 96 in Group B (4.2%), and there were no malpositions in Group C. There were no significant differences among the three groups ($p = 0.114$).

Conclusions: The direction of the J-tip of the guidewire had no statistically significant effect on incidence of malpositioned tips.

Key Words: catheterization, central venous; jugular vein; malposition.

Introduction

Central venous catheterization (CVC) is a common and important procedure for the clinical management of many patients, especially in the emergency department (ED) or intensive care unit (ICU). It allows resuscitation for intravascular depletion and access for vasoactive medications and antibiotics, and it provides a means for hemodynamic monitoring and pacing.[1,2] The placement of central venous catheters is a technically challenging procedure. The most common cause of early malfunctioning of the central venous catheter is related to malpositioning.[3] Misplacement of a central venous catheter tip may result in incorrect venous pressure readings or serious complications such as vascular erosion and thrombosis.[4]

Several techniques have been suggested to prevent malpositioning of the catheter. The direction of the guidewire J-tip was associated with misplacement of a central venous catheter, and it was reported that the rate of misplacement was increased in subclavian venous catheterization, which used the J-tip directed cephalad.[5-8] However, there has been little research on the influence of the direction of the J-tip on the

Received on August 11, 2015 Revised on September 21, 2015

Accepted on September 23, 2015

Correspondence to: Yong chul Cho, Department of Emergency Medicine, College of Medicine, Chungnam National University Hospital, 282 Munhwa-ro, Jung-gu, Daejeon 35015, Korea
Tel: +82-42-280-8007, Fax: +82-42-280-8082
E-mail: boxter73@cnuh.co.kr

*No potential conflict of interest relevant to this article was reported.

© This is an Open Access article distributed under the terms of the Creative Commons Attribution Non-Commercial License (<http://creativecommons.org/licenses/by-nc/3.0/>) which permits unrestricted non-commercial use, distribution, and reproduction in any medium, provided the original work is properly cited.

Copyright © 2015 The Korean Society of Critical Care Medicine

placement of internal jugular vein (IJV) catheter.

Thus, we hypothesized that the direction of the J-tip of the guidewire during its insertion via IJV might determine its ultimate location.

Materials and Methods

1) Study design and setting

In this prospective randomized controlled study, patients between the ages of 18 and 99 years who required CVC via IJV at ED of the tertiary teaching hospital throughout January to December 2014 were included (Fig. 1). This study was approved by the institutional review board of our institution, and informed consent was obtained from all patients.

2) Selection of participants

Indications for central venous access in the ED included

difficult peripheral vascular access and a need for invasive hemodynamic monitoring, delivery of inotropic medications or antibiotics, and delivery of fluids and blood when no other access was available. Patients with neck deformities or significant coagulopathy were excluded. Based on the direction of the J-tip (Fig. 2), patients were divided into three groups: the J-tip medial directed group (Group A), or lateral directed group (Group B), or downward directed group (Group C), by using a block randomization technique. Randomization was determined with random number tables, and allocation assignments were concealed in sealed envelopes. The operator became aware of the direction of the J-tip of the guidewire only after enrollment. At the end of the procedure, the operator recorded the data on a preformatted data collection sheet. Data included patient details, operator and experience levels, the reason for insertion of the CVC, and any complications.

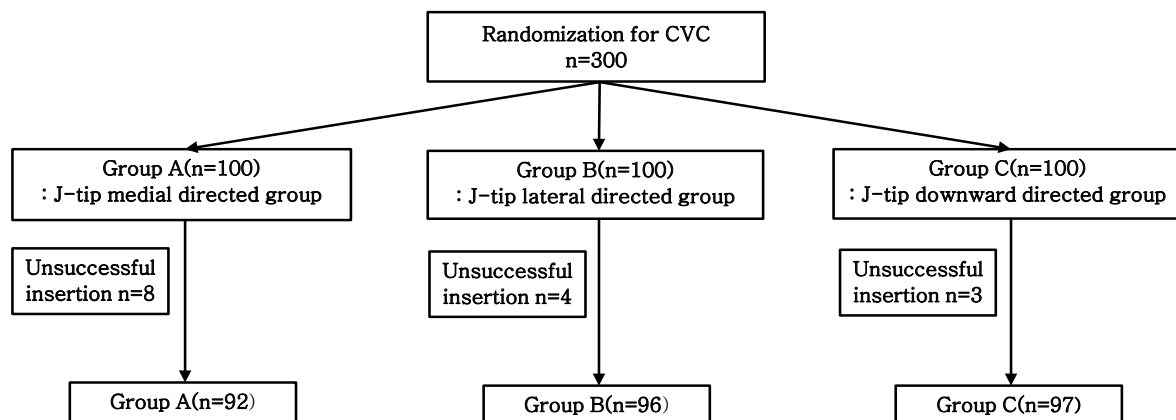


Fig. 1. Flow chart of enrolled patients in this study. Group A; the J-tip medial directed group, Group B; the J-tip lateral directed group, Group C; the J-tip downward directed group. CVC: central venous catheterization.

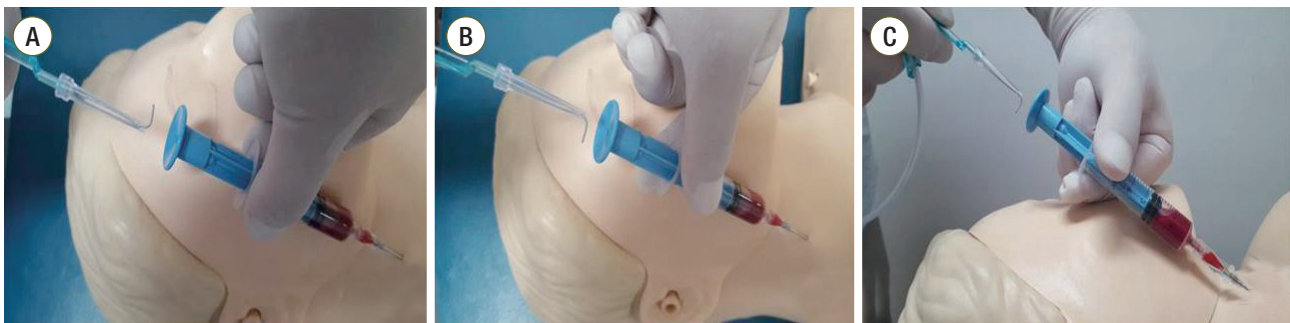

Fig. 2. Three different directions of the J-tip of the guidewire in central venous catheterization using the right internal jugular vein. (A) The J-tip medial-directed group (Group A), (B) the J-tip lateral-directed group (Group B), (C) the J-tip downward-directed group (Group C).

3) Intervention

Operators were either emergency physicians or residents working in the ED. Experienced operators were defined as those who had successfully performed more than 25 traditional landmark IJV catheterizations without supervision, and inexperienced operators were those who had performed fewer than 25 traditional landmark IJV catheterizations.[9] There were 16 operators, with 10 experienced and 6 inexperienced. Selection of the blood vessel (right IJV or left IJV) has been inserted at the discretion of the operator

Under full aseptic conditions, the patient was placed in the supine position and a local anesthetic was used at the venipuncture site. The IJV (right or left) was punctured using an 18-gauge needle. The free aspiration of non-pulsatile venous blood confirmed correct needle placement into jugular vein. An independent operator prefixed the directions of the J-tip of the guidewire to three directions in random fashion using presealed envelopes for the three groups studied. For insertion of the guidewire, the introducer needle was removed and the track to the IJV puncture was enlarged using the dilator. Subsequently, a double lumen catheter (7F) was passed over the guidewire and the fixed at the 15 to 18 cm mark. Free aspiration of blood through the catheter reconfirmed correct placement of the tip of catheter into the vein. The catheterization was performed using a double lumen central venous catheter with a J-tip of spring guidewire (Prime-s, Sungwon Medical, Cheongju, Korea). This consists of an 18-gauge needle introducer, a 0.032 inch diameter, 60 cm spring guidewire with J-tip, and a 7.0 French, 20 cm double lumen catheter with integrated dilator. Before commencement of the study, operators were educated about methods of study for an hour. Postoperative chest radiography was performed on all patients to visualize mechanical complication such as pneumothorax or hemothorax, and the location of the catheter tip. A malpositioned catheter is de-

fined as at a location other than the superior vena cava (SVC) or right atrium.

4) Statistical analysis

All data were analyzed by the IBM SPSS Statistics 19 program (IBM Corp., Chicago, IL, USA). The Kruskal-wallis test was used to compare mean values among the three groups, and a χ^2 or Fisher's exact test was performed to compare the discrete variables. The calculated value of $p < 0.05$ was considered statistically significant.

Using a predicted malpositioning rate, based on previous literature, of a proportion incidence (5.3%), a power of 80% and $p < 0.05$, the calculated sample size was 118 in each group.[2] However, given the evidence in other critical care settings for malposition of IJV catheterizations, an interim analysis, based on malpositioning rate, was planned once study numbers over 91 were obtained. Finally, our study was required over 99 cases in each group, considering 10% dropout.

Results

Of the 300 patients enrolled for randomization, IJV catheterization was successful in 285 of 300 patients. The 15 patients in whom IJV puncture or advancement of the guidewire failed were excluded from the study. Each group was comparable with respect to age, gender, and mechanical complications. There was one complication of a pneumothorax (Table 1). The incidence of malpositioning was significantly lower in insertion via right IJV than left (1.7% vs. 8.2%, $p = 0.032$). Experienced operators successfully inserted an IJV catheter in 164 of 169 (97.4%) cases compared with 113 of 116 (97.0%) cases in the inexperienced group. The effect of operator was not statistically significant

Table 1. Overall characteristics of enrolled patients

Characteristics	Group A (n = 92)	Group B (n = 96)	Group C (n = 97)	p-value
Age, yr	69 (25)	75 (15)	72 (19)	0.093
Male	56 (60.9)	63 (65.6)	59 (60.8)	0.735
Complication of CVC	1 (0.4)	0 (0)	0 (0)	0.323

Value are presented as median (interquartile range) and n (%). Group A; the J-tip medial directed group, Group B; the J-tip lateral directed group, Group C; the J-tip downward directed group. p value refer to difference between groups using Kruskal-wallis and Chi-Square or Fisher's exact test.

CVC: central venous catheterization.

Table 2. Incidence of catheter malposition according to operation experience and vessels

	Correct position	Malposition	p-value
Operator experience			
Inexperienced	164 (97.4)	5 (2.6)	> 0.9*
Experienced	113 (97.0)	3 (3.0)	
Hand dominance			
Right-handed operator	260 (97.0)	8 (3.0)	0.608 [†]
Left-handed operator	17 (100)	0 (0)	
Insertion vessel			
Right IJV	232 (98.3)	4 (1.7)	0.032 [‡]
Left IJV	45 (91.8)	4 (8.2)	

Data are presented as n (%).

*p > 0.9 vs. inexperienced, experienced; [†]p = 0.608 vs. right-handed operator, left-handed operator; [‡]p = 0.032 vs. right IJV vs. left IJV.

IVJ: internal jugular vein.

Table 3. Incidence of catheter malposition according to direction of the J-tip of the guidewire for each group

	Group A (n = 92)	Group B (n = 96)	Group C (n = 97)	p-value
Position of central catheter tip				
Correct position	88 (95.7)	92 (95.8)	97 (100)	0.114*
Malposition	4 (4.3)	4 (4.2)	0 (0)	
Type of malposition				
Loop formation	1 (1.1)	1 (1.1)	0 (0)	
Ipsilateral SCV	0 (0)	1 (1.1)	0 (0)	
Contralateral SCV or brachiocephalic vein	3 (3.3)	2 (2.2)	0 (0)	

Data are presented as n (%).

Group A; the J-tip medial directed group, Group B; the J-tip lateral directed group, Group C; the J-tip downward directed group.

SCV: subclavian vein.

*p = 0.114 vs. group A, group B, and group C.

difference (p > 0.9) (Table 2).

Of the total malpositioned (defined as located other than the SVC or right atrium) catheter tips (8 of 285; 2.8%), the majority of these catheters (5 of 8; 62.5%) entered the contralateral subclavian vein, 2 of 8 (25.0%) catheters were complicated by looping, and 1 of 8 (12.5%) entered the ipsilateral subclavian vein (Table 3) (Fig. 3).

According to the direction of the J-tip of the guidewire, the incidence of malposition of the tip of catheter was in the J-tip medial directed group (4 of 92; 4.3%), and the J-tip lateral directed group (4 of 96; 4.2%). There were no malpositions in the J-tip downward group. In the three groups, there was no significant difference in statistics (p = 0.114) (Table 3).

For the malpositioned IJV catheterizations, access was obtained in the contralateral IJV, subclavian, or femoral vein.

Discussion

Previous studies have made an effort to reduce the malpositioning of subclavian venous catheterization.[1,4-8] But related research usually focuses on the subclavian vein and not the IJV because the frequency of malpositioning on subclavian vein is probably higher than that of the IJV (5.3% vs. 9.3%, relative risk 0.66 [0.44-0.99]). The anatomical sites, most commonly used by clinicians, are subclavian vein and IJV.[10] The IJV has low incidence of malpositioning and there is no difference in mechanical complication, compared to subclavian vein.[2] However, little research has been studied for malposition in the IJV catheterization. In this prospective study, we sought to determine whether the direction of the J-tip of the guidewire influenced malpositioning during IJV catheterization.

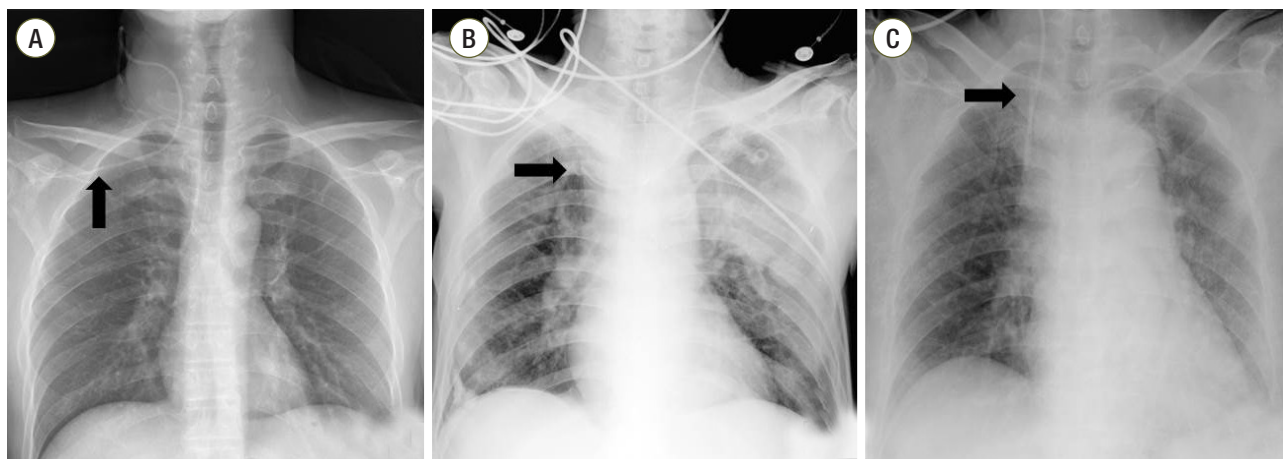


Fig. 3. Malpositioned tips of the central venous catheter (black arrow) shown in chest X-ray anteroposterior view. (A) Ipsilateral insertion into the axillary vein via the right SCV, (B) Contralateral insertion into the right SCV, (C) Loop formation in the SVC. SCV: subclavian vein; SVC: superior vena cava.

The “J” tip helps to prevent the guidewire from catching against the luminal wall of the vein. The J-tip of the guidewire is thus preferred over the straight tip, being less traumatic and easier to negotiate past acute angulations. [11] Some studies have reported that the direction of J-tip has a crucial role in the incidence of malpositioning. Tripathi et al.[7] state that there is significant difference in the incidence of malpositioning (each 43% and 3%; $p < 0.05$) between the J-tip directed groups cephalad and caudad in the placement of catheters via the right subclavian vein. They insisted that the simple measurement of directing the guidewire for the J-tip caudad significantly reduced the risk of misplacement into the ipsilateral IJV in right subclavian catheterization. However, Oh et al.[4] showed that there is no significant difference in the incidence of malpositioning (each 11% and 7%; $p = 0.639$) between landmark and ultrasound guidance groups while keeping the J-tip directed cephalad. As previously suggested,[4] we also showed that the direction of J-tip was not correlated with the incidence of malpositioning ($p = 0.114$). However, our results showed that the J-tip medial and lateral directed groups in each of 4 cases (4.3%, 4.2%), but not the J-tip downward group, experienced in malpositioning. In the IJV, in contrast to the subclavian vein, the direction of the J-tip was not related to the incidence of malpositioning. In addition, it was more prevalent in the left IJV, compared to the right IJV (1.7% vs. 8.2%, $p = 0.032$). Consistent with our results, previous studies also showed that the incidence of malpositioning in right

IJV catheterizations was less common than in the left IJV. [12,13]

It has been known that the incidence of complications was dependent on the technical aspects of the procedure. [14] However, our study, consistent with previous reports, shows that the incidence of malpositioning in “junior”-level procedures was not different from those in “expert”-level procedures.[9]

In this study, the overall incidence of malpositioning was 8 of 285 (2.8%). It is a lower incidence than in other studies (5.3% to 18.9%) which performed IJV catheterization using by landmark.[2,15,16]

There were some limitations to our study. First, it did not consider possible impacts (e.g. thrombosis, vascular anomaly) on the malpositioning, other than the direction of the J-tip. Second, although the initial direction of J-tip is important to the determination of its ultimate location, there is still a possibility for rotation on inside veins.[4] Third, this study defined ‘malpositioning’ as the tip of catheters located other than SVC or right atrium, whereas Vesely[17] recommended it be located on the crista terminalis as their junction. Fourth, the enrolled number of patients may be too small to draw a statistically powerful conclusion. Based on our study, of a proportion incidence (2.8%), a power of 80% and $p < 0.05$, the calculated sample size was 279 in the J-tip downward directed group (Group C) and 279 in other directed groups (Group A and B) to prove the significant differences between the J-tip downward directed group with

other directed groups. Further large study is necessary to confirm this result.

Last, this study did not include the J-tip upward-directed group. However, the J-tip upward direction was not preferred by operators because it is difficult to proceed in the upward direction using the structure of the guidewire dispenser.

We demonstrated that malpositions are more common after left IJV catheterization than right that the direction of J-tip of guidewire does not statistically significant effect on incidence of malpositioned CVC tips.

ORCID

Won Joon Jeong <http://orcid.org/0000-0002-6320-230X>

References

- 1) Miller AH, Roth BA, Mills TJ, Woody JR, Longmor CE, Foster B: Ultrasound guidance versus landmark technique for the placement of central venous catheters in the emergency department. *Acad Emerg Med* 2002; 9: 800-5.
- 2) Ruesch S, Walder B, Tramèr MR: Complications of central venous catheters: internal jugular versus subclavian access--a systematic review. *Crit Care Med* 2002; 30: 454-60.
- 3) Boardman P, Hughes JP: Radiological evaluation and management of malfunctioning central venous catheters. *Clin Radiol* 1998; 53: 10-6.
- 4) Oh AY, Jeon YT, Choi EJ, Ryu JH, Hang JW, Park HP, et al: The influence of the direction of J-tip on placement of a subclavian catheter: real time ultrasound-guided cannulation versus landmark method, a randomized controlled trial. *BMC Anesthesiology* 2014; 14: 11.
- 5) Sanchez R, Halck S, Walther-Lasen S, Heslet L: Misplacement of subclavian venous catheters: importance of head position and choice of puncture site. *Br J Anaesth* 1990; 64: 632-3.
- 6) Kang M, Ryu HG, Son IS, Bahk JH: Influence of shoulder position on central venous catheter tip location during infraclavicular subclavian approach. *Br J Anaesth* 2011; 106: 344-7.
- 7) Tripathi M, Dubey PK, Ambesh SP: Direction of the J-tip of the guidewire, in seldinger technique, is a significant factor in misplacement of subclavian vein catheter: a randomized, controlled study. *Anesth Analg* 2005; 100: 21-4.
- 8) Ahn H, Kim G, Cho B, Jeong W, Yoo Y, Ryu S, et al: How to decrease the malposition rate of central venous catheterization: real-time ultrasound-guided reposition. *Korean J Crit Care Med* 2013; 28: 280-6.
- 9) Leung J, Duffy M, Finckh A: Real-time ultrasonographically-guided internal jugular vein catheterization in the emergency department increases success rates and reduces complications: a randomized, prospective study. *Ann Emerg Med* 2006; 48: 540-7.
- 10) Felleiter P, Gustorff B, Lierz P, Hörauf K: Use of electrocardiographic placement control of central venous catheters in Austria. *Acta Med Austriaca* 1999; 26: 109-13.
- 11) Wang HE, Sweeney TA: Subclavian central venous catheterization complicated by guidewire looping and entrapment. *J Emerg Med* 1999; 17: 721-4.
- 12) Maffessanti M, Bortolotto P, Kette F: Malpositions and complications following central venous catheterization in relation to the access site. *Radiol Med* 1988; 75: 609-12.
- 13) Muhm M, Sunder-Plassmann G, Apsner R, Pernerstorfer T, Rajek A, Lassingg A, et al: Malposition of central venous catheters. Incidence, management and preventive practices. *Wien Klin Wochenschr* 1997; 109: 400-5.
- 14) Bagwell CE, Salzberg AM, Sonnino RE, Haynes JH: Potentially lethal complications of central venous catheter placement. *J Pediatr Surg* 2000; 35: 709-13.
- 15) McGee WT, Ackerman BL, Rouben LR, Prasad VM, Bandi V, Mallory DL: Accurate placement of central venous catheters: a prospective, randomized, multicenter trial. *Crit Care Med* 1993; 21: 1118-23.
- 16) Peres PW: Positioning central venous catheters--a prospective survey. *Anaesth Intensive Care* 1990; 18: 536-9.
- 17) Vesely TM: Central venous catheter tip position: a continuing controversy. *J Vasc Interv Radiol* 2003; 14: 527-34.