

Successful tracheal intubation using fiberoptic bronchoscope via an I-gelTM supraglottic airway in a pediatric patient with Goldenhar syndrome

-A case report-

Young-Lok Kim, Da-Mi Seo, Kwang-Seok Shim, Eun-Ju Kim, Ji-Hyang Lee, Sang-Gon Lee, and Jong-Seouk Ban

Department of Anesthesiology and Pain Medicine, Daegu Fatima Hospital, Daegu, Korea

The I-gelTM is a single-use supraglottic airway device introduced in 2007 which features a non-inflatable cuff and allows passage of a tracheal tube owing to its large diameter and short length of the airway tube. In this case, the authors experienced a difficult airway management on a 4-year-old boy with underlying Goldenhar syndrome who underwent a tonsillectomy. Intubation using a laryngoscope was unsuccessful at the first attempt. In the following attempt, we used the I-gelTM supraglottic airway for ventilation and were able to achieve successful intubation with a cuffed tube by using fiberoptic bronchoscope through the I-gelTM supraglottic airway. The authors suggest that I-gelTM is a useful device for ventilation and it has many advantages for tracheal intubation in pediatric patients with difficult airway. (Korean J Anesthesiol 2013; 65: 61-65)

Key Words: Airway management, Fiberoptic bronchoscope, Goldenhar syndrome, Laryngeal mask airway, Pediatric.

A pediatric patient who is expected difficulties in airway management requires different methods of management compared with an adult patient. Awake intubation is difficult due to poor cooperation, and LMA FastrachTM can be used only in adults. Therefore, fiberoptic bronchoscopic intubation through a supraglottic airway device can be the standard management method. The authors have experienced failed intubation using

a laryngoscope in a 4-year-old boy diagnosed with Goldenhar syndrome. However, ventilation using the I-gelTM supraglottic airway device (I-gelTM) and fiberoptic bronchoscopic intubation through the I-gelTM was successful. To our knowledge, there are no known cases of successful intubation through I-gelTM in pediatric patients. In this article, we report the case along with relevant references to the literature.

Received: July 25, 2012. Revised: August 17, 2012. Accepted: August 22, 2012.

Corresponding author: Da-Mi Seo, M.D., Department of Anesthesiology and Pain Medicine, Daegu Fatima Hospital, 576-31, Sinam-dong, Dong-gu, Daegu 701-600, Korea. Tel: 82-53-940-7434, Fax: 82-53-954-7417, E-mail: jamais_vu@naver.com

© This is an open-access article distributed under the terms of the Creative Commons Attribution Non-Commercial License (<http://creativecommons.org/licenses/by-nc/3.0/>), which permits unrestricted non-commercial use, distribution, and reproduction in any medium, provided the original work is properly cited.

Case Report

A 4-year-old boy (55 months, 16.3 kg, 102 cm) was diagnosed with chronic hypertrophic tonsillitis and adenoid vegetation due to severe stertorous breathing and sleep apnea, and he was hospitalized in the otorhinolaryngology department for tonsillectomy and adenoidectomy. Preoperative laboratory tests, electrocardiogram, and chest radiology were unremarkable. However, the patient had severe stertorous breathing and recently developed mild dry coughing two days prior to surgery. According to the preoperative interview with the guardian one day before the surgery, the patient was born via cesarean section due to breech presentation weighing at 3.5 kg and had no specific medical history. An intramuscular injection of 0.25 mg atropine was given as premedication 30 minutes prior to entering the operating room. The patient's guardian was in attendance in the waiting room for psychological stabilization.

When we approached the patient for induction of anesthesia, malformation was found on the right side of the patient's face. When asked once again about the patient's medical history, it was found that the patient was diagnosed with congenital auricular atresia after birth, and hearing test conducted 3

months after birth confirmed hearing loss of the right ear. Later, the patient was diagnosed with Goldenhar syndrome accompanying partial loss of the right auricle, conjunctival dermoid, and oral atresia. The right side of the patient's face was less developed compared with the left, thus making his face asymmetric. The auricle was undeveloped, with only a partial earlobe remaining in his right ear (Fig. 1). The Mallampati oral opening view was unavailable due to agitation of the patient, and the patient presented irregular dentition. The patient was sitting on the bed due to dyspnea that occurs in a lying position. While the guardian remained to help stabilize the patient, ketamine (2 mg/kg) was administered to induce anesthesia. With spontaneous breathing intact, the patient was taken to the operating room.

In the waiting room, pulse oxygen saturation was measured at 98% in a sitting position. However, after ketamine was given for induction of anesthesia, pulse oxygen saturation fell to 94% in the operating room with the spontaneous breathing intact. Other vital signs showed blood pressure of 125/85 mmHg and heart rate of 170 beats/min. Preoxygenation was performed, and 0.6 mg/kg of rocuronium and 1 µg/kg of fentanyl were administered intravenously. Manual ventilation was attempted

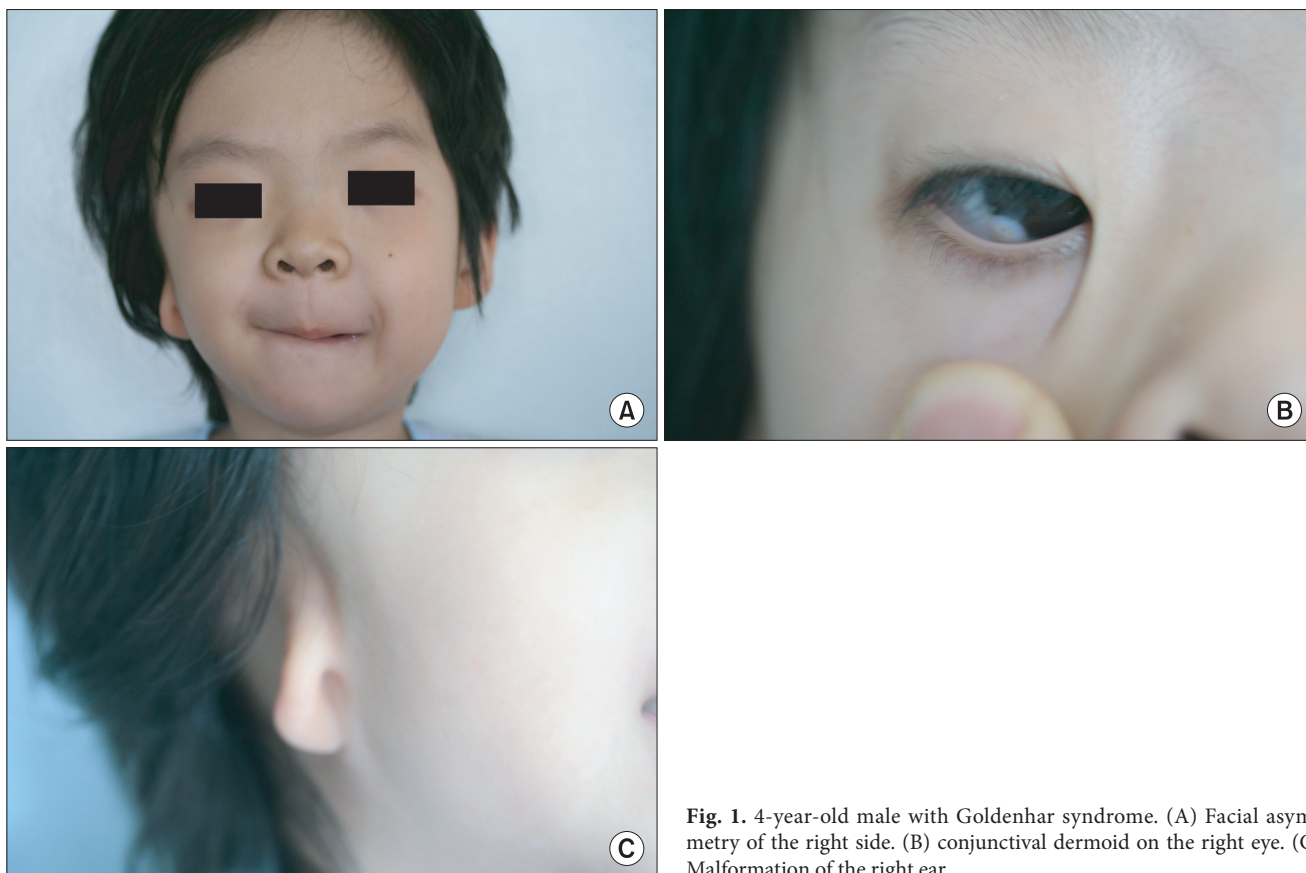


Fig. 1. 4-year-old male with Goldenhar syndrome. (A) Facial asymmetry of the right side. (B) conjunctival dermoid on the right eye. (C) Malformation of the right ear.

using a mask, but the mask did not fit due to facial deformity. For effective manual ventilation, gauze was filled in the buccal area to achieve the best possible fit for the mask. Oral airway was inserted and an open airway was maintained using both hands, and then manual ventilation was attempted with the help of an assistant.

A skilled anesthesiologist used a #2 Macintosh curved laryngoscope blade to lift the epiglottis with an assistant manipulating the larynx, but failed to check the glottic opening. With a 4.5 mm cuffed tube (Mallinckrodt, Covidien, Ireland) and a stylet, the authors used blind technique for intubation, but it was unsuccessful. A video laryngoscope (GlideScope & GVL 4, Verathon Medical, Canada) was used in the following attempt, but even entering the glottis was difficult due to the narrow oral cavity. Thus, a supraglottic airway device (I-gel™ size 2, Intersurgical, Lithuania) was inserted for proper ventilation. Then a bronchoscope (LF-DP, Olympus, Tokyo, Japan) was inserted through I-gel™ for visualization of the glottic opening, a part of which was shown on the upper side of a the bronchoscopic view. By lifting the mandible and applying pressure on the cricoid cartilage, the authors moved the glottic opening to the center of the the bronchoscopic view. After deciding to attempt fiberoptic bronchoscopic intubation, adequate ventilation was performed. A cuffed 4.5 mm tube was covered with lubricant, and fiberoptic bronchoscopic intubation was performed through a laryngeal mask airway. The tube was placed in a proper depth by checking the carina (Fig. 2). In order to remove the I-gel™ while maintaining the tube, first, the connecting part at the proximal end of the tube was removed. Then, a tube exchanger (Airway exchanger catheter, Cook, Canada), which was thicker than the tube, was used to secure the tube in place. Finally, the I-gel™ was removed (Fig. 3). After

cuff ballooning, the tube's connecting part and the respiratory circuit were connected. The authors checked the depth of the tube through a stethoscope and conducted mechanical ventilation.

During the surgery, 1.5 and 2.5 L/min of O₂ and air were administered, respectively. Anesthesia was maintained with sevoflurane 2.0–2.5 vol%. Vital signs were maintained, as follows: blood pressure 115–130/70–85 mmHg, heart rate 140–170/min, pulse oxygen saturation 98–100%, and capnogram 32–41 mmHg. The operation was finished after 75 minutes. After the spontaneous breathing of the patient was recovered, 0.004 mg/kg glycopyrrolate and 0.2 mg/kg pyridostigmine was injected intravenously. Then, the patient was extubated and moved to the recovery room. Severe stridor and even transient apnea occurred while the patient was lying in the recovery room. When 5 L/min of oxygen was supplied by a mask, pulse oxygen saturation was up to 98%, but it fell to 84–88% during room air respiration. The patient did not feel much discomfort because he had long been adapted to low oxygen saturation. After being stabilized for 2 hours in the recovery room, the patient was supplied with 2 L/min of oxygen through a nasal cannula and transferred back to the patient's room. Total operative time and anesthesia time were 75 minutes and 105 minutes, respectively, and 80 ml of Hartman solution was administered. On the fourth day following the surgery, the patient was discharged without any further problems.

Discussion

Goldenhar syndrome, also known as oculoauriculovertebral dysplasia (OAVD), was reported by Goldenhar in 1952. It is a congenital defect characterized by preauricular appendages,

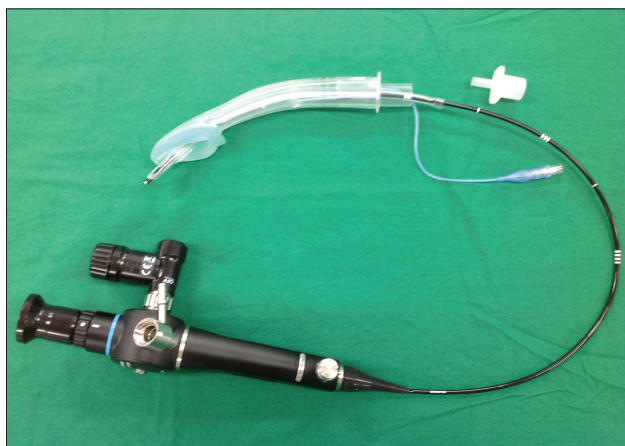


Fig. 2. Setting of ID 4.5 mm cuffed tracheal tube over a fiberoptic bronchoscope through an size 2 I-gel™.

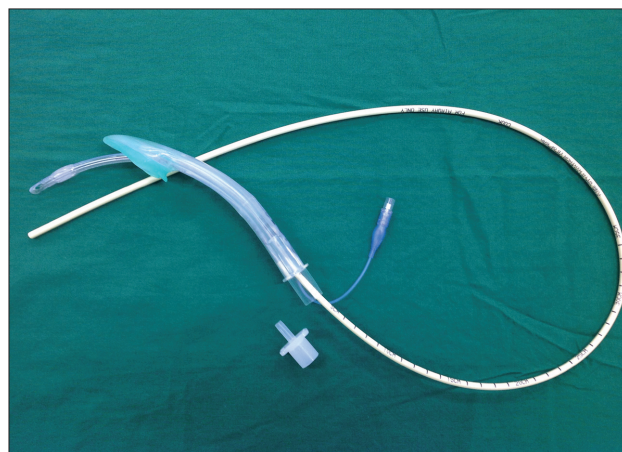


Fig. 3. The proximal end of the tracheal tube is held by a tube exchanger larger than inner diameter of the tracheal tube to prevent accidental dislocation of the tracheal tube while I-gel™ is withdrawn.

blinded fistulas, epibulbar dermoid, and vertebral anomalies. In particular, difficult ventilation and airway are expected due to hemifacial microsomia, microgenia, mandibular hypoplasia, and vertebral anomalies. Thus, patients with Goldenhar syndrome require careful airway management [1,2].

Several cases have been reported in which difficult airway occurred or was expected in children diagnosed with Goldenhar syndrome. Various methods were attempted for airway management. There is a report on successful intubation in a 4.5-year-old child with Goldenhar syndrome and associated mandibular hypoplasia by using a straight blade and a 4.0 mm tube after a failed attempt using a curved blade and a 4.5 mm tube [3]. Another case reported successful general anesthesia using a laryngeal mask airway (LMA) without intubation during ophthalmic surgery in a 10-year-old Goldenhar syndrome patient complicated with severe microsomia [4]. There is also a case of successful fiberoptic bronchoscopic intubation in a 6-year-old patient with right facial deformity and occipitocervical fusion [5]. In addition, one case reported a successful pediatric fiberoptic bronchoscopic intubation through an LMA during a planned tracheostomy for respiratory failure in a 19-day-old infant (3.6 kg) while the infant was awake [6]. It was also reported, in a case in which airway obstruction occurred after extubation in a 4-month-old baby, that an open airway was maintained using an LMA [7].

Airway management can be difficult during anesthesia in children with Goldenhar syndrome, and various methods have been attempted. An LMA is considered a very useful device for airway management [4,6,7]. Also, an LMA can be used as a passage for intubation, as evidenced by Johnson's use of an LMA as an method of airway management to administer anesthesia to an infant in tracheostomy.

In our case, a traditional approach to intubation was attempted but did not succeed. Thus, a supraglottic airway device was inserted, in line with the ASA guidelines [8,9]. This device enabled adequate airway management so that proper ventilation was possible without gas leakage. Also, the authors succeeded in intubation by using an I-gel™ instead of an LMA. This method has not yet been reported in pediatric patients, but several cases reported successful intubation using an I-gel™ on adults. Emmerich and Tiesmeier [10] reported a case in which fiberoptic bronchoscopic intubation succeeded using a 6.5 mm tube and a size 5 I-gel™, after a failed fiberoptic bronchoscopic intubation, in a 69-year-old patient who was expected to have a difficult airway. Campbell et al. [11] failed in intubation in a 54-year-old patient by using a laryngoscope; a size 4 Classic LMA was then inserted, but failed to achieve adequate ventilation. When a size 4 I-gel™ was used, adequate ventilation was achieved, and fiberoptic bronchoscopic intubation was successful using a 7.0 mm tube. Sharma et al. [12] attempted 2 intubations through a laryngoscope in a teenage

boy for general anesthesia but failed in both attempts. Then he inserted a size 4 Classic LMA and achieved adequate ventilation but twice failed in fiberoptic bronchoscopic intubation. When he attempted fiberoptic bronchoscopic intubation by replacing the size 4 LMA with a size 4 I-gel™, intubation was successful. As these cases and other reports suggest, an I-gel™ allows stable airway management when ventilation is difficult to achieve through a mask airway or when intubation itself is difficult. In addition, an I-gel™ can function as a guide for a bronchoscope. An I-gel™, therefore, can be used as a passage for intubation.

However, LMAs show some shortcomings compared with I-gel™. First, LMAs have limits in using cuffed tubes. According to recently published reports, Lee et al. [13] succeeded in fiberoptic bronchoscopic intubation through an LMA in two patients, ages 6 and 24, who were expected to have difficult airways. He used a size 2.5 Classic LMA and uncuffed 4.5 mm tube for the 6-year-old patient and a size 3.0 LMA and uncuffed 4.5 mm tube for the 24-year-old patient. Likewise, intubation is possible through an LMA, but uncuffed tubes were used for the ease of LMA removal after intubation. Also, when using size 2.5 and smaller LMAs, the pilot area of cuffed tubes cannot pass the LMA. In our case, as a tonsillectomy was planned, a cuffed tube had to be used for intubation. We succeeded in intubation by using a cuffed tube and a size 2.0 I-gel™. Also, LMAs such as size 2 LMA Classic™ and size 1.5 LMA Unique™, commonly used for pediatric patients, has more dense aperture bars in the mask bowl compared with larger LMAs (Fig. 4). This can be a hindrance when a bronchoscope or tubes pass. Therefore, a size 2.0 I-gel™ is more useful than LMAs of the same or smaller size in pediatric intraoral surgeries that require the use of cuffed tubes.

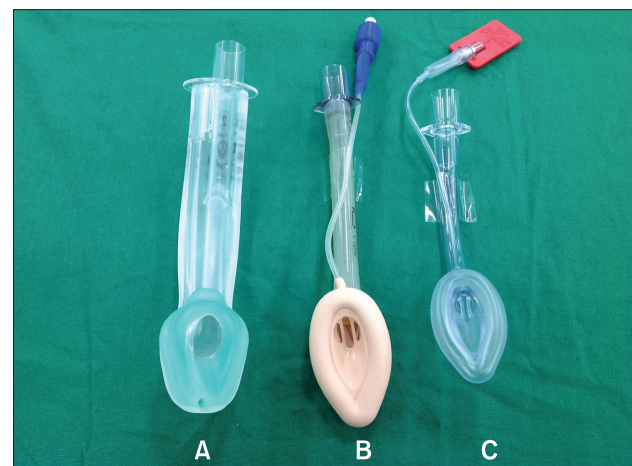


Fig. 4. Supraglottic airways used for pediatric airway management. (A) Size 2 I-gel™, (B) Size 2 LMA Classic™, (C) Size 1.5 LMA Unique™. While (B) LMA Classic™, and (C) LMA Unique™, both have aperture bars, (A) I-gel™, lacks an aperture bar but instead has a wider stem.

However, the use of an I-gel™ does not address all of the problems associated with LMAs. The Mallinckrodt tubes' pilot cannot pass I-gels of size 1.5 and smaller, similar to size 2 and smaller LMAs. Therefore, if possible, it is desirable to use an uncuffed tube in infants in which a size 1.5 I-gel™ is used. If a surgery that requires the use of cuffed tubes is planned, it is worth considering the use of an uncuffed tube first to intubate and then replacing it later through a tube exchanger. In this case, it was not easy to remove an I-gel™ after intubation while maintaining the tube in place. To prevent the tube from being removed when I-gel™ was removed, the authors used the tube exchanger, thicker than the tube, in order to secure the tube in place. However, the pilot part of the tube overlapped with the tube exchanger and could not pass. Thus, the authors pulled back the I-gel™ until the part of the tube was exposed in the oral cavity, secured the tube in place with forceps, and removed the I-gel™ completely. It was successful, but the authors slightly fell into a disorder at the time. It appears that, for this process to be safer and easier, a longer pediatric tube is necessary, and

covering the whole tube with lubricant is necessary. Similar to the authors' opinion, Mauch et al. [14] reported that the use of a smaller supraglottic airway device and uncuffed tube had advantages and expected that an extended tube would produce more desirable results.

In conclusion, difficult airway management is expected in pediatric patients with facial deformity such as Goldenhar syndrome. Thus, meticulous evaluation and planning are required before performing anesthesia. Supraglottic airway devices can be useful for proper ventilation when difficulties occur in airway management after induction of anesthesia. Also, the use of an I-gel™ for fiberoptic bronchoscopic intubation has benefits due to its structural characteristics. In particular, it is more beneficial in pediatric intraoral surgeries that require the use of cuffed tubes. However, additional research and the development of more suitable devices are necessary for broader application. Nevertheless, it is recommended as an alternative when other methods fail.

References

1. Feingold M, Baum J. Goldenhar's syndrome. *Am J Dis Child* 1978; 132: 136-8.
2. Madan R, Trikha A, Venkataraman RK, Batra R, Kalia P. Goldenhar's syndrome: an analysis of anesthetic management. A retrospective study of seventeen cases. *Anaesthesia* 1990; 45: 49-52.
3. Altintas F, Cakmakcaya OS. General anesthesia for a child with Goldenhar syndrome. *Paediatr Anaesth* 2005; 15: 529-30.
4. Sukhupragarn W, Rosenblatt WH. Airway management in a patient with Goldenhar syndrome: a case report. *J Clin Anesth* 2008; 20: 214-7.
5. Ozlü O, Simşek S, Alaçakır H, Yiğitkanlı K. Goldenhar syndrome and intubation with the fiberoptic bronchoscope. *Paediatr Anaesth* 2008; 18: 793-4.
6. Johnson CM, Sims C. Awake fiberoptic intubation via a laryngeal mask in an infant with Goldenhar's syndrome. *Anaesth Intensive Care* 1994; 22: 194-7.
7. Jeon MS, Seo KS, Kim HJ, Yum KW. Emergency airway management using a laryngeal mask airway (LMA) following extubation in an infant with a congenital facial anomaly -A case report-. *Korean J Anesthesiol* 2008; 54: 569-72.
8. Practice guidelines for management of the difficult airway: an updated report by the American Society of Anesthesiologists Task Force on Management of the Difficult Airway. *Anesthesiology* 2003; 98: 1269-77.
9. Weiss M, Engelhardt T. Proposal for the management of the unexpected difficult pediatric airway. *Paediatr Anaesth* 2010; 20: 454-64.
10. Emmerich M, Tiesmeier J. The I-gel supraglottic airway: a useful tool in case of difficult fiberoptic intubation. *Minerva Anesthesiol* 2012; 78: 1169-70.
11. Campbell J, Michalek P, Deighan M. I-gel supraglottic airway for rescue airway management and as a conduit for tracheal intubation in a patient with acute respiratory failure. *Resuscitation* 2009; 80: 963.
12. Sharma S, Scott S, Rogers R, Popat M. The i-gel airway for ventilation and rescue intubation. *Anaesthesia* 2007; 62: 419-20.
13. Lee JJ, Lim BG, Lee MK, Kong MH, Kim KJ, Lee JY. Fiberoptic intubation through a laryngeal mask airway as a management of difficult airway due to the fusion of the entire cervical spine. *Korean J Anesthesiol* 2012; 62: 272-6.
14. Mauch J, Haas T, Weiss M. Distance from the laryngeal mask grip to endotracheal tube tip. A crucial point during fiberoptic intubation in children. *Anaesthesist* 2012; 61: 123-8.