

## 전이성 전립선암 환자에서 발생한 2가지 형태의 응고병증

임인수, 이길호<sup>1</sup>단국대학교 의과대학 진단검사의학과, <sup>1</sup>단국대학교 비뇨기과 교실

## Two Different Coagulopathy Episodes in a Single Patient with Metastatic Prostate Cancer

Insoo Rheem, Gilho Lee<sup>1</sup>Departments of Laboratory Medicine and <sup>1</sup>Urology, Dankook University Medical College, Cheonan, Korea

We reported a case of two different episodes of critical coagulopathy in a single patient with metastatic prostate cancer (mPC). The patient initially visited the emergency room with a huge left retroperitoneal hematoma, high serum prostate-specific antigen level, and signs of acute disseminated intravenous coagulation (DIC) from mPC. With blood product replacement and anti-androgen therapy, the DIC-related symptoms and signs were relieved. During the follow-up, he was treated with docetaxel chemotherapy for hormone refractory PC. Four years later, he visited the emergency room again with relapsed coagulopathy and severe anemia that were not replaced with blood products. The laboratory findings were consistent with thrombotic thrombocytopenic purpura rather than DIC. A satisfactory recovery was achieved with a new cycle of docetaxel chemotherapy. Differentiation of the coagulopathies in PC is difficult; therefore, we describe the different features of two overlapping coagulopathies, which will be helpful in deciding on urgent treatment.

**Keywords:** Disseminated intravascular coagulation; Hemolytic anemia; Prostatic neoplasm

**Received:** 8 April, 2015**Revised:** 16 April, 2015**Accepted:** 16 April, 2015

Copyright © 2015, Korean Association of Urogenital Tract Infection and Inflammation. All rights reserved.



This is an open access article distributed under the terms of the Creative Commons Attribution Non-Commercial License (<http://creativecommons.org/licenses/by-nc/4.0>) which permits unrestricted non-commercial use, distribution, and reproduction in any medium, provided the original work is properly cited..

**Correspondence to:** Gilho Lee <http://orcid.org/0000-0002-9253-6245>

Department of Urology, Dankook University Medical College, 119 Dandae-ro, Dongnam-gu, Cheonan 330-714, Korea

Tel: +82-41-550-3963, Fax: +82-41-551-6630

E-mail: multiorigins@yahoo.com

Coagulopathy is a well-known characteristic of advanced prostate cancer (PC).<sup>1-8</sup> The serious manifestations of PC related coagulopathy vary from disseminated intravenous coagulation (DIC) to thrombotic thrombocytopenic purpura (TTP).<sup>1-8</sup> It is important to diagnose correctly and treat appropriately between DIC and TTP because the clinical features of DIC and TTP are overlapped or similar.<sup>2,3,7</sup> We

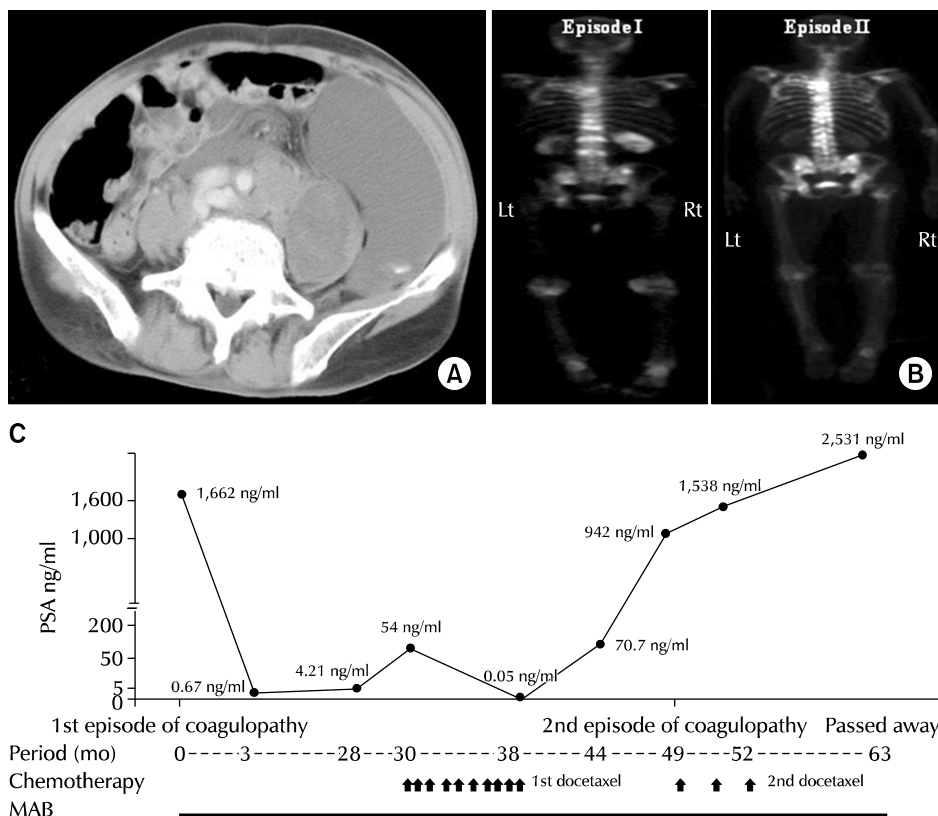
report a rare case with different types of coagulopathies in a metastatic PC (mPC) patient- initial DIC associated coagulopathy and later TTP associated coagulopathy.

## CASE REPORT

A 67-year-old man was admitted to emergency room

(ER) because of sudden left abdominal pain. An initial computed tomography revealed a large left side retroperitoneal hematoma and multiple lymph node enlargements (Fig. 1A). The laboratory findings were consistent with PC associated with DIC (Table 1). Prostate biopsy revealed 4+3 prostate adenocarcinoma, and bone scan revealed multiple bone metastases (episode I; Fig. 1B). With blood replacement therapy and maximal androgen

blockade (MAB) therapy, the DIC-related symptoms were relieved and serum prostate-specific antigen (PSA) levels were continuously decreasing and the nadir was 0.67 ng/ml. Two years later, while continuous MAB therapy, the levels of PSA were steadily increased to 54.65 ng/ml. Under the impression of hormone refractory PC, he was administrated 75 mg/m<sup>2</sup> docetaxel chemotherapy for 10 cycles. The PSA nadir after chemotherapy reached 0.05 ng/ml after the last



**Fig. 1.** (A) Computed tomography scan at the 1st episode of coagulopathy demonstrated left retroperitoneal hematoma with contrast medium extravasation and multiple lymph node enlargements around aorta and inferior vena cava. (B) Radionuclide bone scan revealed multiple bone metastases at the 1st episode of coagulopathy. Bone scan at the 2nd episode showed more aggravated bone metastatic lesions than the previous episodes. (C) Clinical course and the levels of serum PSA during the follow up. Arrows for docetaxel chemotherapy, PSA, and MAB. PSA: prostate-specific antigen, MAB: maximal androgen blockade, Lt: left, Rt: right.

**Table 1.** Laboratory findings between the coagulatory episodes

Parameter	Episode I	Episode II	Reference
Hemoglobin (g/dl)	4.4	2.8	13-17
Platelet (/μl)	$74 \times 10^3$	$83 \times 10^3$	$130-400 \times 10^3$
WBC (/μl)	12,900	10,190	$4-10 \times 10^3$
Nucleated red blood cell	Neg	$4/100$ WBC <sup>1</sup>	Neg
Metamyelocytes (%)	Neg	2	Neg
Myelocyte (%)	Neg	1	Neg
Activated partial thromboplastin time (sec)	55.7	32.5	22.5-36
Prothrombin time (sec)	23.3	15.4	11-13
Internal normalized ratio	2.57	1.4	0-1.2
Fibrinogen (mg/dl)	125	161	146-374
Lactate dehydrogenase (U/L)	935	1,661	240-480
Total bilirubin (mg/dl)	1.7	0.99	0.2-1.1
D-dimer (ng/ml)	>15,000	>500	0-250
Prostate-specific antigen (ng/ml)	1,662	942	<4
Serum creatinine (mg/dl)	1.8	1.1	0.7-1.2
Serum anterior posterior (IU/L)	142	110	40-129

WBC: white blood cell, Neg: negative.

cycle. However, one year after the chemotherapy, the patient visited the ER again with dizziness and general weakness. We could not find any physical evidence of internal or external active bleeding sites as seen at first episode of coagulopathy. The laboratory findings are shown in Table 1. In additions, peripheral blood smear revealed reticulocytosis (14.0%), normocytic normochromic anemia with poikilocytosis, and schistocytosis. The serum levels of albumin, protein, aspartate aminotransferase, and alanine aminotransferase were within normal ranges. Bone scan showed more aggravated bone metastatic lesions than the previous episode (episode II; Fig. 1B). Despite aggressive intervention, severe anemia continued, and the general conditions and laboratory findings worsened. A clinical diagnosis of PC associated TTP/microangiopathic hemolytic anemia was made and the patient was started on repeated 75 mg/m<sup>2</sup> docetaxel chemotherapy. After the first cycle of repeated chemotherapy, there was a rise of hemoglobin to 11.5 g/dl, platelets to 233,000/ $\mu$ l, and decrease of lactic dehydrogenase to 837 U/L. We treated the patient every 3 weeks for a total of 3 cycles. While the hematologic parameters were improved after the new cycle of chemotherapy, the PSA levels were continuously elevated (Fig. 1C). Eleven months after the 2nd chemotherapy, the patient passed away with mPC.

## DISCUSSION

While DIC has been frequently reported in PC evolution, PC related TTP is a very rare phenomenon. DIC is characterized by uncontrolled activation of clotting and fibrinolytic pathways, resulting in uncontrolled consumption of coagulation factors and diffuse intravascular deposition of clots. While TTP is characterized by five signs (thrombocytopenia, microangiopathic hemolytic anemia, neurological abnormalities, renal failure, and fever), only a minority of patients with TTP have all 5 signs.<sup>1</sup> In reality, the clinical criteria for TTP have been limited to thrombocytopenia and hemolytic anemia without an alternative explanation.<sup>4</sup> Unfortunately, the life-threatening DIC and TTP occasionally shared overlapping clinical and laboratory features, and no single laboratory test differentiates enough to definitely diagnose two coagulopathies.<sup>7</sup> Generally, TTP patients showed less severe or borderline results for prothrombin time, partial thromboplastin time

and D-dimer levels than DIC patients.<sup>3,4</sup> This patient revealed severe anemia without evidences of internal or external bleeding which could not be replaced with massive blood replacement therapy. The presence of schistocytes on the peripheral blood smear is another evidence of microangiopathic hemolytic anemia to make a diagnosis for TTP.<sup>8</sup>

The therapeutic cornerstone of DIC and TTP is treatment of the underlying disorder.<sup>7</sup> A common and serious error in the management of neoplasia associated acute coagulopathy is to waste time trying to correct abnormal laboratory values by giving blood product infusions prior to treating the underlying malignancy.<sup>7</sup> Delaying definitive treatment for underlying diseases can cause the patients to fall into vicious cycles and progress to multiorgan dysfunction syndrome. It is a general principle that acute DIC in cancer may present as brisk spontaneous internal hemorrhage, requiring urgent blood product replacement. While the acute DIC signs were temporarily improved with blood product replacement, the complete conversions of abnormal coagulation laboratory findings were achieved with anti-androgen therapy in this patient. However in case of TTP, the massive blood replacement cannot correct hematological laboratory findings. Even though this patient received 12 packed red blood cell transfusion during 2nd episode, the hemoglobin levels could not be sustained and dropped into 5.2 g/dl within 5 days. The transfused blood may be destroyed in peripheral blood vessel in microangiopathic hemolysis mechanism in TTP. Recently, the appropriate treatment of neoplasia associated microangiopathic hemolysis is management of the underlying cancer.<sup>3</sup> It is a general rule that docetaxel chemotherapy is a mainstay for reversal of DIC in hormonal refractory PC patients.<sup>9</sup> However, fewer studies reported successful treatment and PSA reduction with docetaxel chemotherapy in TTP patients with hormonal refractory PC.<sup>5</sup> In addition, most of the reported patients were cases of hormonal resistant and docetaxel naïve PC.<sup>5</sup> Furthermore, our patient was unique as TTP manifestations were improved with a new cycle of the same docetaxel chemotherapy. Interestingly, while the coagulopathy was improved with a new cycle of chemotherapy, the serum PSA levels did not decrease.

We cannot find any clinical report about the management for PC associated TTP patients who had received docetaxel

chemotherapy for hormonal resistant PC. We think it is a first case in two different coagulopathies in a patient with mPC who was successfully treated of the TTP manifestations with a new cycle of docetaxel chemotherapy.

In conclusion, coagulation disorders are frequently associated with mPC. If not appropriated with early aggressive management, the patients compromise short-term prognosis. It is very important that urologists and oncologists understand the mechanisms of PC-related coagulopathies, differentiate the coagulation disorders, and manage the manifestation with the specific treatment.

## CONFLICT OF INTEREST

No potential conflict of interest relevant to this article was reported.

## REFERENCES

1. de la Fouchardière C, Flechon A, Droz JP. Coagulopathy in prostate cancer. *Neth J Med* 2003;61:347-54.
2. Doll DC, Kerr DM, Greenberg BR. Acute gastrointestinal bleeding as the presenting manifestation of prostate cancer. *Cancer* 1986;58:1374-7.
3. Pinto F, Brescia A, Sacco E, Volpe A, Gardi M, Gulino G, et al. Disseminated intravascular coagulation secondary to metastatic prostate cancer: case report and review of the literature. *Arch Ital Urol Androl* 2009;81:212-4.
4. Park YA, Waldrum MR, Marques MB. Platelet count and prothrombin time help distinguish thrombotic thrombocytopenic purpura-hemolytic uremic syndrome from disseminated intravascular coagulation in adults. *Am J Clin Pathol* 2010;133:460-5.
5. Caramello V, Dovio A, Caraci P, Berruti A, Angeli A. Thrombotic thrombocytopenic purpura in advanced prostate cancer: case report and published work review. *Int J Urol* 2007;14:150-2.
6. Marcoullis G, Abebe L, Jain D, Talusan R, Bhagwati N, Wiernik PH. Microangiopathic hemolysis refractory to plasmapheresis responding to docetaxel and cisplatin: a case report. *Med Oncol* 2002;19:189-92.
7. Labelle CA, Kitchens CS. Disseminated intravascular coagulation: treat the cause, not the lab values. *Cleve Clin J Med* 2005;72:377-8.
8. Rizzo C, Rizzo S, Scirè E, Di Bona D, Ingrassia C, Franco G, et al. Thrombotic thrombocytopenic purpura: a review of the literature in the light of our experience with plasma exchange. *Blood Transfus* 2012;10:521-32.
9. Hyman DM, Soff GA, Kampel LJ. Disseminated intravascular coagulation with excessive fibrinolysis in prostate cancer: a case series and review of the literature. *Oncology* 2011;81:119-25.