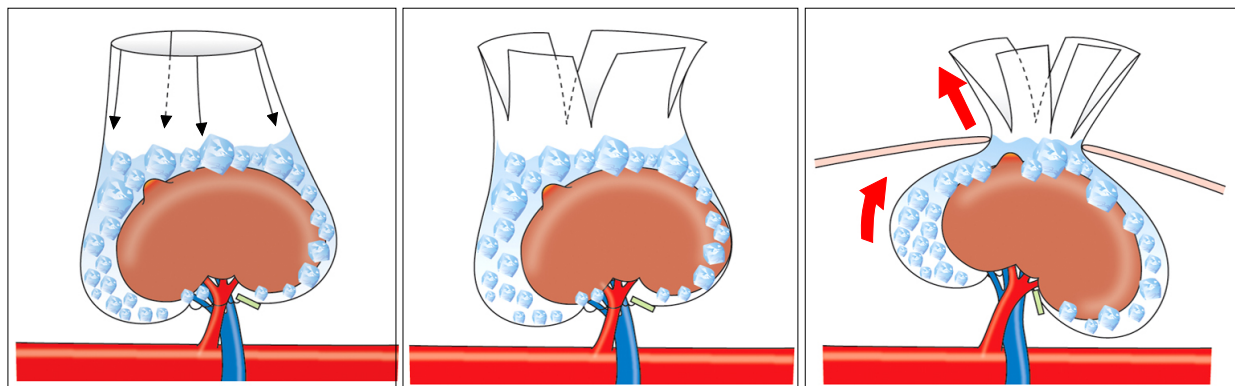


□ Erratum □

Tumor Exposure and Cold Ischemia Using a LapSac[®] in Partial Nephrectomy by Video-Assisted Minilaparotomy Surgery (VAMS)

[Korean Journal of Urology 2009;50(8):774-779]

Fig. 1 on page 775 should be corrected so that the adrenal gland is not included in the LapSac[®].
(This figure was chosen as the cover artwork of that issue.)



The Korean Journal of Urology apologizes to its readers for this editorial error.

*DOI of review article: doi: 10.4111/kju.2009.50.8.774.