

Urachal Xanthogranuloma: Laparoscopic Excision with Minimal Incision

Sungchan Park, Young Hwan Ji, Sang Hyeon Cheon, Young Min Kim¹,
Kyung Hyun Moon

From the Departments of Urology and ¹Pathology, Ulsan University Hospital,
University of Ulsan College of Medicine, Ulsan, Korea

Urachal xanthogranuloma is an extremely rare disease. A 23-year-old man presented with severe lower abdominal pain and voiding frequency. Computed tomography revealed a urachal mass with bladder invasion, which was suspected to be a urachal carcinoma or abscess. Laparoscopic urachal resection was performed with a minimal incision. Histopathologic examination identified the mass as a urachal xanthogranuloma. (*Korean J Urol* 2009;50:714-717)

Key Words: Urachal cyst, Xanthogranulomatous pyelonephritis, Laparoscopy

Korean Journal of Urology
Vol. 50 No. 7: 714-717, July 2009

DOI: 10.4111/kju.2009.50.7.714

Received : March 5, 2009

Accepted : June 29, 2009

Correspondence to: Kyung Hyun Moon
Department of Urology, Ulsan
University Hospital, University of
Ulsan College of Medicine, 290-3,
Jeonha-dong, Dong-gu, Ulsan
682-714, Korea
TEL: 052-250-7190
FAX: 052-250-7198
E-mail: urofirst@uuh.ulsan.kr

© The Korean Urological Association, 2009

Urachal xanthogranuloma is an extremely rare disease. To the best of our knowledge, about 18 cases have been reported with respect to urachal xanthogranuloma in a meticulous search of the PubMed database up to 2008.¹⁻⁵ This is the first case in Korea and the first trial of laparoscopic excision through a minimal incision.

Computed tomography findings of xanthogranulomatous urachitis resemble those of urachal carcinoma and, although rare, this entity should be included in the differential diagnosis of urachal masses.³ Therefore, surgical excision and histologic examination are required to differentiate a urachal carcinoma from xanthogranulomatous inflammation of the urachus.⁴ We report a patient with urachal xanthogranuloma who underwent laparoscopic surgery with a minimal incision.

CASE REPORT

A 23-year-old Korean man presented with severe lower abdominal pain and voiding frequency that had appeared 20 days prior to presentation. The patient had been healthy and had no previous medical problems. He had no fever or loss of weight. A urologist performed a physical examination and identified diffuse hardness and tenderness without change of skin color in the lower abdominal midline area. However, the mass was not palpable. A complete blood count with a

differential count revealed only a mild elevation of the platelet count (534,000/ μ l). A urine test revealed hematuria (RBC 50-100/HPF; WBC > 100/HPF). Urine culture was negative for bacterial growth and urine cytology did not suggest malignancy. The results of an electrolyte battery and tests of liver function and renal function were all within normal limits.

Computed tomography with contrast enhancement of the abdomen and pelvis revealed a soft tissue mass lesion with an approximate diameter of 4.9 cm attached to the anterosuperior aspect of the bladder (Fig. 1). The location of the mass was considered to be of urachus origin, and urachal carcinoma or

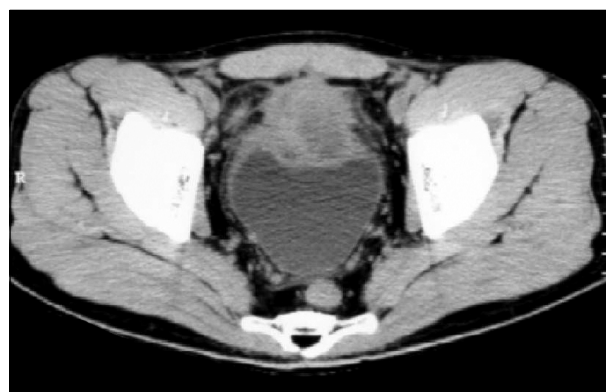


Fig. 1. Preoperative computed tomography revealed a urachal mass.

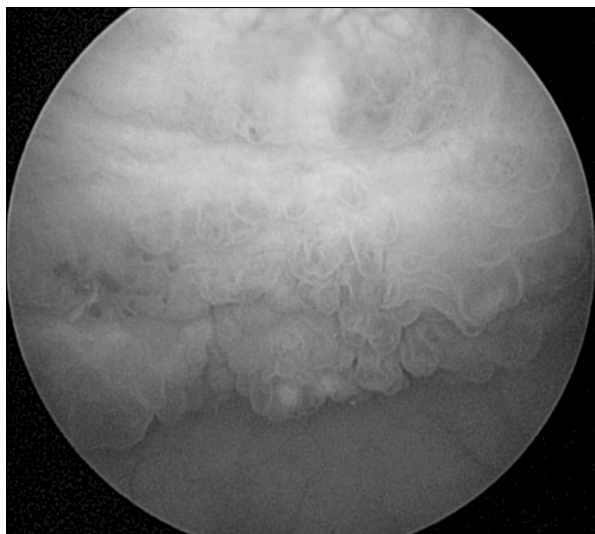


Fig. 2. Cystoscopic findings showed that the anterior bladder had inflammatory changes.

inflammations such as adenocarcinoma, actinomycosis, abscess, and so forth had to be excluded. There were no enlargements of lymph nodes or suspected metastatic lesions in the abdomen or the pelvis. Preoperative cystoscopy revealed diffuse mucosal changes just like a cystic inflammation pushing outside at the dome (Fig. 2).

Under general anesthesia, laparoscopic excision of the urachal remnant and partial cystectomy was performed. The patient was placed in the Trendelenburg position, with a 30° elevation of the left hip and flank. The first 10 mm port was placed by using the Hasson technique, on the right hemi-abdomen, at the umbilicus and the lateral border of the rectus muscle. A pneumoperitoneum was performed through this trocar (dissector, grasper). The next ports were placed under laparoscopic vision on the epigastrium (port 2, Optic) and the line joining the umbilical cicatrix with the right anterosuperior iliacus spina, always doing so along the lateral border of the rectus, avoiding the epigastric arteries (port 3, Metzenbaum scissors).⁶ The urachus was disconnected from the undersurface of the umbilical skin and, with the help of grasping forceps, was dissected away from the anterior abdominal wall to allow dissection of the entire urachus with the overlying peritoneum in a plane between the posterior rectus sheath and the under-surface of the muscle belly of the rectus. Using a “twist and roll” action as Wadhwa et al⁷ mentioned, the urachus was twirled around the grasping forceps, which provided strong traction and a clear view of the plane of dissection (Fig. 3).

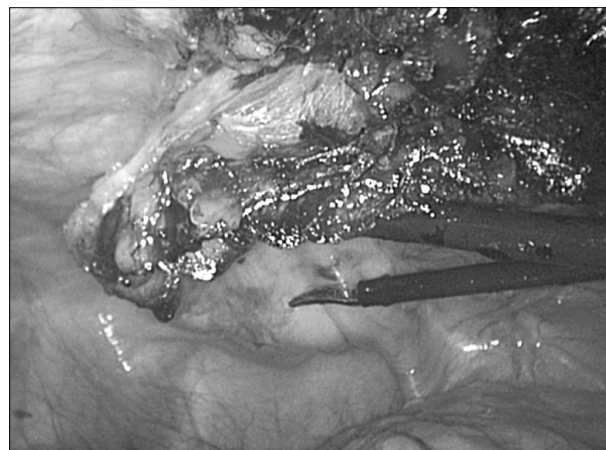


Fig. 3. Laparoscopic excision of the urachus. By use of a “twist and roll” action, the urachus was twirled around the grasping forceps.⁸

This dissection was followed caudally, in an antegrade manner, to subsequently enter the prevesical space of Retzius. There were severe infiltrations and hard adhesions around the pre-vesical mass. Laparoscopic excision could not be performed further. A minimal lower abdominal transverse incision (about 5 cm in size) was made, and the urachal remnant was excised and a partial cystectomy was performed through this window. A frozen biopsy of the main mass revealed inflammatory cells and no tumor cells. The resection margin showed no evidence of tumor cells. Therefore, we performed only pelvic lymph node sampling.

The final histologic examination revealed that the urachal mass was composed of a urachal cyst with xanthogranulomatous inflammation and chronic perivesical inflammation and fibrosis (Fig. 4A, B). Lesions showed typical lipid-laden foamy histiocytes favoring xanthogranulomatous changes (Fig. 4C, D). There was no evidence of neoplasm or carcinoma in situ. So far, 10 months after surgery, there have been no signs of recurrence or symptoms.

DISCUSSION

Xanthogranulomatous lesions are unusual forms of chronic inflammatory processes, pathologically characterized by the presence of large lipid-laden macrophages. Such lesions have been described in many urologic anatomic sites, such as kidney, bladder,^{8,9} testis, urachus, and retroperitoneum. The etiology of xanthogranulomatous lesions, however, is unclear. Xanthogra-

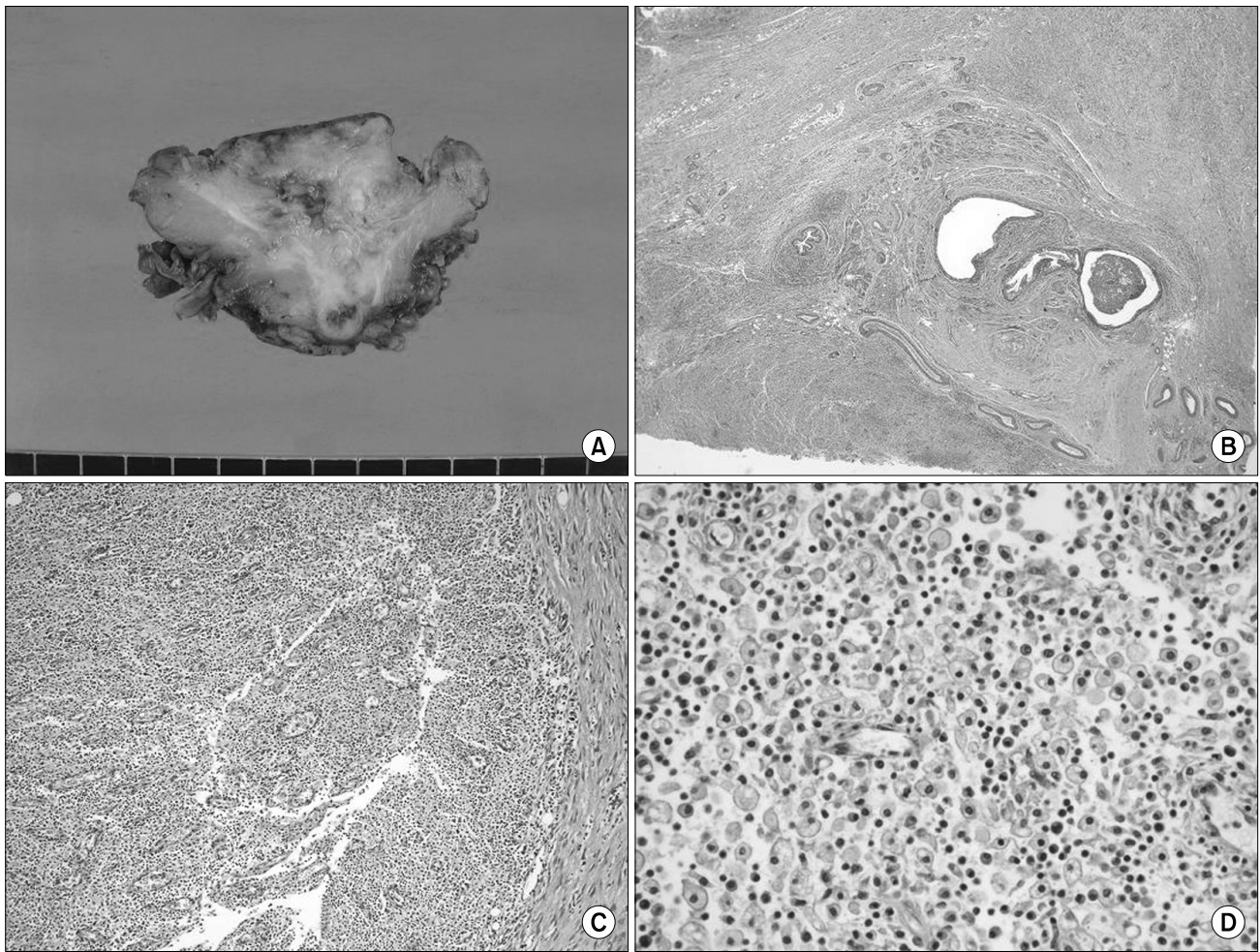


Fig. 4. (A) Gross Specimen. The mass is transected and shows a yellowish necrotic area between adipose tissues. (B) Microphotography showing urachal remnant (center) and inflammatory changes (H&E, x20). (C) Infiltration of foamy histiocytes favoring xanthogranulomatous changes (H&E, x200). The right lateral side is a smooth muscle of bladder (normal). (D) Lesion showing typical lipid-laden histiocytes with fine cytoplasmic vacuolization and scattered lymphocytes (H&E, x400).

nulomatous cystitis has been proposed to follow chronic infection of an urachal diverticulum or cyst, because 75% of all previously reported cases were associated with a remnant and 76% were located at the dome of the bladder. It is suggested that an immunologic defect is involved in the pathogenesis of xanthogranulomatous cystitis.¹⁰ Urachal xanthogranuloma is considered to have a similar etiology.

In all the Japanese studies regarding urachal xanthogranuloma, the patients presented with similar symptoms. All complained of sepsis and a lower abdominal mass.⁴ These are common presentations of urachal xanthogranuloma. However, our patient complained of symptoms of cystitis, including frequency, dysuria, and lower abdominal pain, which are typical symptoms of xanthogranulomatous cystitis.⁸⁻¹⁰ The symptoms

may have been caused by reactive cystitis adjacent to the urachal xanthogranuloma that was shown by cystoscopy.

The laparoscopic approach for benign urachal anomalies has been reported to be safe and efficacious. Laparoscopic partial cystectomy has been described for various benign diseases of the bladder, such as bladder leiomyoma, pheochromocytoma, and endometriosis. Recently, it was published that laparoscopic en bloc partial cystectomy with bilateral pelvic lymphadenectomy for urachal adenocarcinoma is a safe, feasible, minimally invasive alternative to open partial cystectomy for a urachus tumor.⁷ Therefore, we think that urachal tumors such as our case are a good indication for laparoscopic surgery.

Adhesion is an important problem for laparoscopic surgery. It is difficult preoperatively to know whether there is severe

infiltration and adhesion around the urachus and the bladder in a urachal tumor or xanthogranuloma. Laparoscopic dissection may be difficult around a xanthogranuloma; however, it is easy to dissect a urachus remnant behind the umbilicus and laparoscopic excision is useful, even if the extraperitoneal space around the lesion has severe adhesion, as in our case. Increased experience with pelvic laparoscopic surgery will help us to improve our ability to deal with severe adhesion around this area. However, adding a minimal lower abdominal transverse incision (about 5 cm sized) to laparoscopic surgery is another option for a beginner for pelvic laparoscopy when the whole laparoscopic surgery is not done successfully. Excision of a urachal remnant, partial cystectomy, bladder repair, and specimen retrieval were performed through this window in this case.

REFERENCES

1. Yamamoto T, Mori Y, Katoh Y, Iguchi M, Minamidari K, Sawai Y, et al. A case of urachal xanthogranuloma suspected to be a urachal tumor. *Hinyokika Kiyo* 2004;50:493-5
2. Carrere W, Gutiérrez R, Umbert B, Solé M, Menéndez V, Carretero P. Urachal xanthogranulomatous disease. *Br J Urol* 1996;77:612-3
3. Diaz Candamio MJ, Pombo F, Arnal F, Busto L. Xanthogranulomatous urachitis: CT findings. *J Comput Assist Tomogr* 1998;22:93-5
4. Kuo TL, Cheng C. Xanthogranulomatous Inflammation of urachus mimicking urachal carcinoma. *Urology* 2009;73:443
5. Tian J, Ma JH, Li CL, Xiao ZD. Urachal mass in adults: clinical analysis of 33 cases. *Zhonghua Yi Xue Za Zhi* 2008;88:820-2
6. Navarrete S, Sánchez Ismayel A, Sánchez Salas R, Sánchez R, Navarrete Llopis S. Treatment of urachal anomalies: a minimally invasive surgery technique. *JSLs* 2005;9:422-5
7. Wadhwa P, Kolla SB, Hemal AK. Laparoscopic en bloc partial cystectomy with bilateral pelvic lymphadenectomy for urachal adenocarcinoma. *Urology* 2006;67:837-43
8. Kim DY, Kim HS, Kim IK, Moon I, Kim TS, Choi S, et al. Xanthogranulomatous cystitis presenting as a urachal carcinoma. *Korean J Urol* 2004;45:1180-2
9. Han DH, Choi HJ, Kim JH, Shin JS, Chung KJ, Choi HY, et al. Xanthogranulomatous cystitis. *Korean J Urol* 2004;45: 958-61
10. Fornari A, Dambros M, Teloken C, Hartmann AA, Kolling J, Seben R. A case of xanthogranulomatous cystitis. *Int Urogynecol J Pelvic Floor Dysfunct* 2007;18:1233-5