

Giant Fibroepithelial Polyp of the Glans Penis

Yoon Dong Kim, Myung Ho Lee, Jun Mo Kim, Young Ho Kim, Eun Seok Koh¹

From the Departments of Urology and ¹Pathology, College of Medicine, Soonchunhyang University, Bucheon, Korea

Fibroepithelial polyps are a benign neoplasm of mesodermal origin that usually occur in the urinary tract. However, a giant fibroepithelial polyp of the glans penis is very rare and is strongly linked with long-term condom catheter use. In this article, we report a case of a 45-year-old man who presented with a giant fibroepithelial polyp originating from the glans penis. Physical examination showed a 6x3 cm sized mass lesion overlying the ventral surface of the glans near the urethral meatus without urethral communication. For the previous 10 years, the patient had been required to use a condom catheter secondary to paraplegia sustained during a T12-L1 spinal cord injury. He was successfully treated by wide local excision of the mass and suprapubic cystostomy placement. There was no evidence of recurrence after 12 months of follow-up. (**Korean J Urol 2009;50:619-621**)

Key Words: Fibroepithelial neoplasms, Condoms, Penis

Korean Journal of Urology
Vol. 50 No. 6: 619-621, June 2009

DOI: 10.4111/kju.2009.50.6.619

Received : February 25, 2009
Accepted : May 27, 2009

Correspondence to: Jun Mo Kim
Department of Urology, Bucheon
Soonchunhyang Hospital, College
of Medicine, Soonchunhyang
University, 1174, Jung-dong,
Wonmi-gu, Bucheon 420-767,
Korea
TEL: 032-621-5058
FAX: 032-621-5016
E-mail: urojun@schbc.ac.kr

© The Korean Urological Association, 2009

Fibroepithelial polyps are a benign mesodermal tumor that are histologically composed of a cone of fibrovascular stroma emerging from the submucosa. Because the epithelia of polyps differ according to the cells they originate from, polyps that develop from the urinary tract are covered by a layer of nonpapillary transitional cell epithelium, whereas those from the external genitalia or skin are covered by squamous epithelium.¹ Fibroepithelial polyps in the urological discipline primarily develop from the upper urinary tract and rarely from the bladder or posterior urethra.^{1,2} Lesions are usually observed as a smooth-surfaced pedunculated mass and typically are found in children or young patients. However, fibroepithelial polyps of the glans penis differ from those of the urinary tract with regard to their cause, shape, size, and histologic features. They are usually large-sized acquired lesions and are strongly linked to long-term condom catheter use. The pathogenesis of fibroepithelial polyps is unknown.^{2,3} We report a case involving a fibroepithelial polyp of the glans penis associated with long-term condom catheter use in a male patient.

CASE REPORT

A 45-year-old man was admitted to the plastic surgery department because of a skin and soft tissue defect involving the right scrotum. The patient was paraplegic due to a T12-L1 spinal cord injury sustained 10 years previously. His past medical history was also significant for a left simple nephrectomy for a staghorn stone 3 years previously and multiple reconstructive surgeries for skin necrosis in the coccygeal area. A condom catheter was used after his spinal cord injury because of a neurogenic bladder. Physical examination revealed a 7x8 cm skin and connective tissue defect on the right scrotum and a 10x15 cm sized pressure ulcer in the coccygeal area. A polypoid shaped mass was found on the glans penis, primarily involving the ventral surface of the penis near the urethral meatus, without any urethral involvement (Fig. 1). The patient's white blood cell count (13,000/ μ l) and C-reactive protein (23.32 mg/dl) concentration were elevated. Pyuria and hematuria were present on routine urine analysis, and *Enterobacter cloacae* was cultured from the urine. The urinary tract infection was subsequently treated with appropriate antibiotics.

After the patient completed the treatment for the coccygeal and right scrotal skin defects, a local excision of the polyp on the glans penis was performed. After insertion of a urethral catheter, the 6x3x3 cm sized penile mass was completely excised from the urethral meatus and the skin was simple sutured (Fig. 2). Histopathologic examination displayed an edematous fibrovascular core covered under squamous epithelium (Fig. 3A). Many mast cells were found in the loose connective tissue by Ziehl-Neelsen staining, but dysplasia was not seen (Fig. 3B). The urethral Foley catheter was changed to a suprapubic cystostomy to prevent relapse. No sign of recurrence was visualized during the 12-month period postoperatively.

DISCUSSION

Fibroepithelial polyps are a benign mesodermal neoplasms that include fibromas, leiomyomas, neurofibromas, and hemangiomas.⁴ They tend to occur mostly on the skin, but can be found in a wide variety of sites to include the anus, urinary tract, and male and female genitals. Most fibroepithelial polyps in the urinary tract occur in the ureter and renal pelvis and rarely occur in the posterior urethra or bladder.² However, fibroepithelial polyps of the glans penis differ from those involving the urinary tract with regard to their pathogenesis, shape, size, and histologic features. Since fibroepithelial polyps

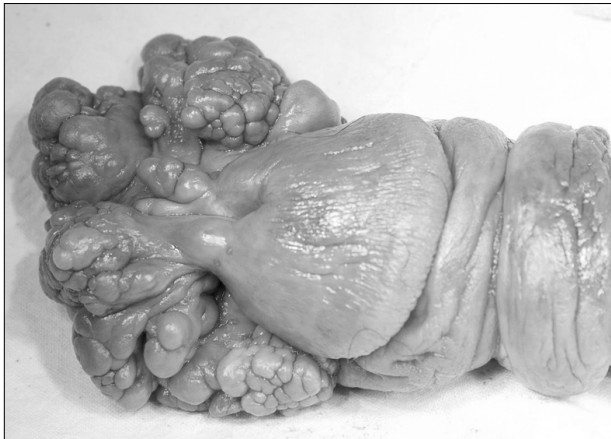

Fig. 1. Gross findings. A giant fibroepithelial polyp is observed at the ventral side of the glans penis.

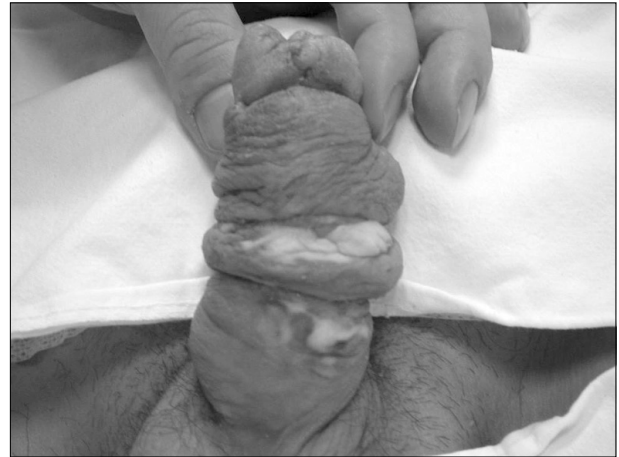

Fig. 2. Postoperative gross findings. The entire polyps are removed from the penis.

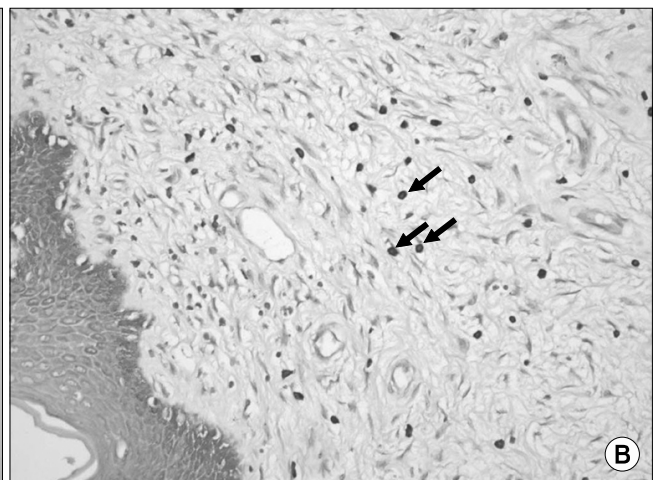
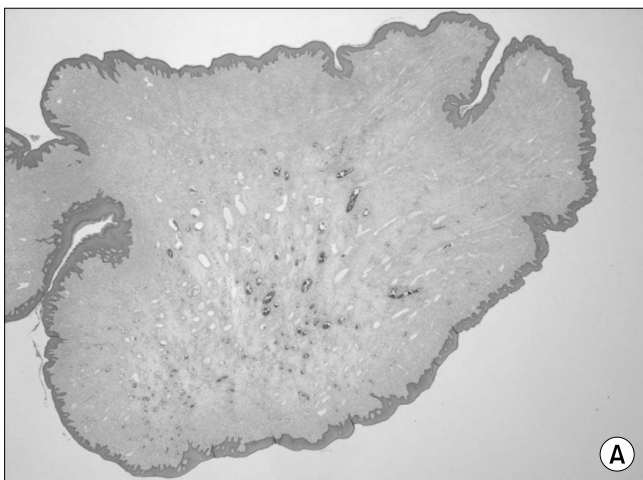


Fig. 3. Microscopic findings. (A) A polyp with normal-appearing squamous epithelium and subepithelial loose connective tissue (H&E, x10). (B) Ziehl-Neelsen staining reveals mast cells (arrows) in the loose connective tissue (x400).

of the glans penis were first reported by Fetsch et al³ in 2004, several reports have surfaced linking this lesion with long-term condom catheter use in quadriplegic or paraplegic patients. Condom catheters are generally considered superior to indwelling urethral catheters given the lower occurrence of urinary tract infections in patients with urinary incontinence unaccompanied by an obstructive uropathy.⁵ However, proper fitting and routine hygienic maintenance are required to avoid the multiple potential complications associated with their use; these include skin irritation, maceration, and ulceration; an allergic reaction to the latex condom or adhesives; recurrent urinary tract infections; a urethral diverticula or fistula; penile edema; and localized ischemia or gangrene.^{5,6} Although the pathogenesis associated with condom catheters remains unclear, it is assumed that the use of a condom catheter decreases vascular and lymphatic drainage and causes secondary stromal hyperplasia. However, another factor to consider when investigating pathogenesis is the tendency of fibroepithelial polyps to develop on the ventral surface of the glans penis near the urethral meatus. In addition, fibroepithelial polyps of the glans penis are not always associated with condom catheter use. Peña and colleagues reported a case not associated with condom catheter use but due to peripheral vascular failure.⁷ Other unusual cases associated with congenital anomaly and paraphimosis have also been reported.^{3,4} Although fibroepithelial polyps from the glans penis are covered with squamous epithelium, these lesions are quite different from skin tags (i.e., fibroepithelial polyp of the anus) with respect to their size and histological features.³ The lesion most similar to a penile fibroepithelial polyp is a vaginal polyp. Vaginal and penile polyps have similar features such as increased stromal cellularity, characteristic multinucleated stromal cells, and proliferation of medium-sized vessels.^{3,8} In addition, mast cells are also found in fibroepithelial polyps of the vagina and anus similar to penile polyps, as seen in our patient. Mast cells play a vital role in inflammatory reactions, fibrosis, and vascular formation through their interaction with mononuclear or polynuclear stromal cells, but their role in fibroepithelial polyp development remains unclear.^{9,10} However, there are clinical and histologic differences between vaginal and penile polyps. The former is more likely to have a myxoid matrix and the stromal cells react positively to immunohistochemical stains with desmin and vimentin, contrary to the latter. Another difference is that the vaginal polyp is assumed to be related to hormones, occurring

mostly in young and middle-aged women. Approximately 40-70% of stroma cells show positive reactions to estrogen and progesterone receptors, whereas stains for hormone receptors in penile polyps remain negative.^{3,8}

Long-term condom catheter use appears to play a role not only in glans penis fibroepithelial polyp occurrence, but also in its recurrence. Considering that 2 out of 7 cases of continuous condom catheter use relapse after primary excision, it is recommended that condom catheters be replaced by either a suprapubic cystostomy, urethral Foley catheter, or by clean intermittent catheterizations to prevent relapse.³ In our patient, the condom catheter was switched to a suprapubic cystostomy with no signs of recurrence in the 12 months following his operation.

REFERENCES

1. Ahn JW, Rho JH, Kim YS, Hong SJ, Lee MS. A case of giant ureteral polyp. *Korean J Urol* 1994;35:906-8
2. Williams TR, Wagner BJ, Corse WR, Vestevich JC. Fibroepithelial polyps of the urinary tract. *Abdom Imaging* 2002;27:217-21
3. Fetsch JF, Davis CJ Jr, Hallman JR, Chung LS, Lupton GP, Sesterhenn IA. Lymphedematous fibroepithelial polyps of the glans penis and prepuce: a clinicopathologic study of 7 cases demonstrating a strong association with chronic condom catheter use. *Hum Pathol* 2004;35:190-5
4. Yildirim I, Irkilata C, Sumer F, Aydur E, Ozcan A, Dayanc M. Fibroepithelial polyp originating from the glans penis in a child. *Int J Urol* 2004;11:187-8
5. Golji H. Complication of external condom drainage. *Paraplegia* 1981;19:189-97
6. Jayachandran S, Mooppan UM, Kim H. Complications from external (condom) urinary drainage devices. *Urology* 1985;25:31-4
7. Peña KB, Parada DD. Lymphedematous fibroepithelial polyp of the glans penis non-associated with condom catheter use. *APMIS* 2008;116:215-8
8. Orosz Z, Lehoczy O, Szoke J, Pulay T. Recurrent giant fibroepithelial stromal polyp of the vulva associated with congenital lymphedema. *Gynecol Oncol* 2005;98:168-71
9. Groisman GM, Polak-Charcon S. Fibroepithelial polyps of the anus: a histologic, immunohistochemical, and ultrastructural study, including comparison with the normal anal subepithelial layer. *Am J Surg Pathol* 1998;22:70-6
10. al-Nafussi AI, Rebello G, Hughes D, Blessing K. Benign vaginal polyp: a histological, histochemical and immunohistochemical study of 20 polyps with comparison to normal vaginal subepithelial layer. *Histopathology* 1992;20:145-50