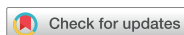

Images in Cardiovascular Medicine



Adrenal Insufficiency in a Patient with Acute Myocardial Infarction Plus Shock

Tae Soo Kang , MD, PhD^{1,*}, Ha-Young Choi, MD^{2,*}, and Sang-Ho Park , MD, PhD²

¹Division of Cardiology, Department of Internal Medicine, Dankook University Hospital, Cheonan, Korea

²Division of Cardiology, Department of Internal Medicine, Soonchunhyang University Cheonan Hospital, Cheonan, Korea

OPEN ACCESS

Received: Apr 25, 2018

Revised: Jul 29, 2018

Accepted: Aug 14, 2018

Correspondence to

Sang-Ho Park, MD, PhD

Division of Cardiology, Department of
Internal Medicine, Soonchunhyang University
Cheonan Hospital, 31, Suncheonhyang 6-gil,
Dongnam-gu, Cheonan 31151, Korea.
E-mail: matsalong@schmc.ac.kr

*Tae Soo Kang and Ha-Young Choi equally
contributed to this work.

A 48-year-old male patient was presented with atypical chest pain and dyspnea. Coronary CT angiography showed a diffuse chronic total occlusion of the left anterior descending coronary artery, a severe stenosis (80–90%) of proximal to mid-left circumflex arteries, and near-total occlusion of the mid-right coronary artery (**Figure 1A–C**). Echocardiography showed severe left ventricular dysfunction with an ejection fraction of approximately 20%. Emergent percutaneous coronary intervention (PCI) after application of extracorporeal membrane oxygenation (ECMO) was successfully performed (**Figure 1D–G**). ECMO was weaned after the 3rd day from the index procedure. However, although follow-up echocardiography after PCI showed much improvement in ejection fraction from 20% to 45%, his blood pressure could not be maintained for 6 days without the use of inotropes. His blood pressure dropped severely whenever the dosage of inotropes was reduced and it was impossible to reduce the dosage of inotropes. The

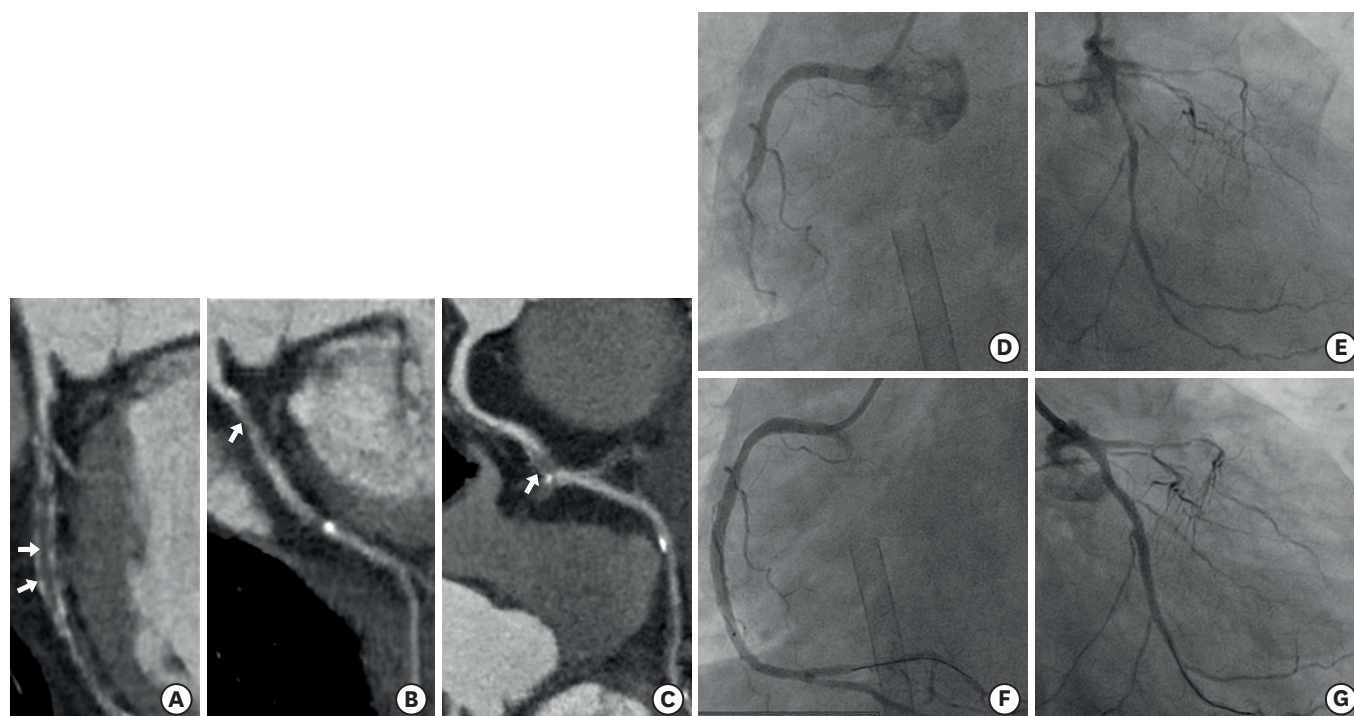


Figure 1. Coronary CT angiography and PCI for LCX coronary artery and RCA. (A) Total occlusion of the LAD coronary artery; (B) 80–90% severe stenosis of proximal to mid-LCX; (C) near-total occlusion of the mid-RCA; (D, E) PCI for LCX lesion; (F, G) PCI for RCA lesion.
 CT = computed tomography; LAD = left anterior descending; LCX = left circumflex; PCI = percutaneous coronary intervention; RCA = right coronary artery.

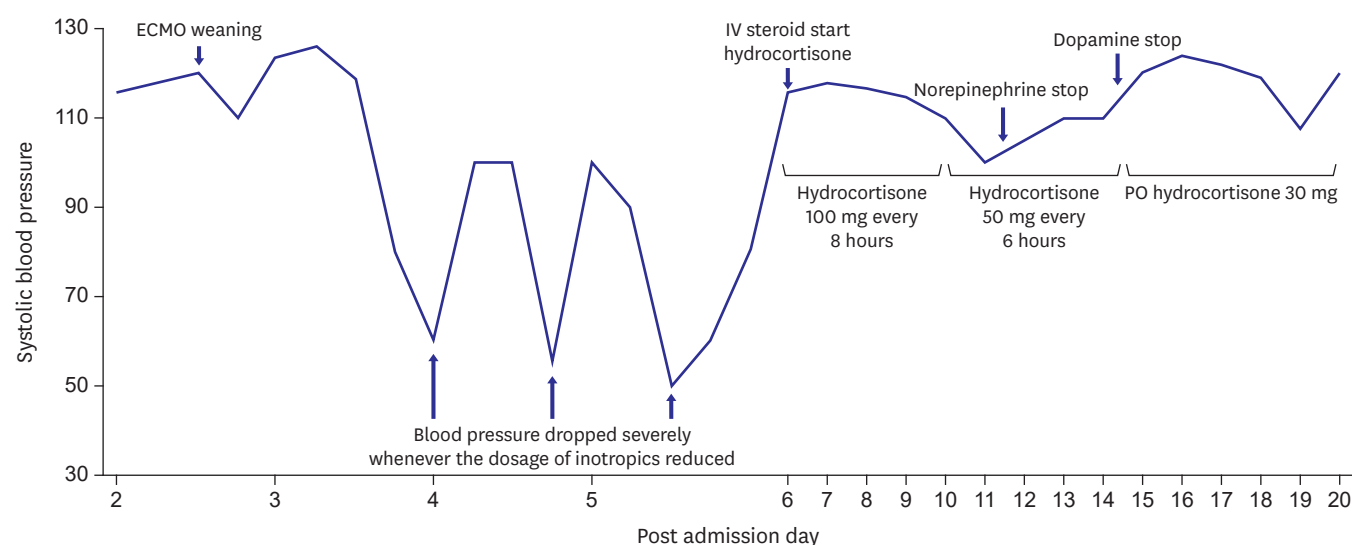



Figure 2. Timeline for blood pressure according to management. The blood pressure of the patient dropped severely whenever the dosage of inotropes was reduced. Vasopressors could be reduced after steroid administration. ECMO = extracorporeal membrane oxygenation; IV = intravenous; PO = oral.

Copyright © 2018. The Korean Society of Cardiology
This is an Open Access article distributed under the terms of the Creative Commons Attribution Non-Commercial License (<https://creativecommons.org/licenses/by-nc/4.0>) which permits unrestricted noncommercial use, distribution, and reproduction in any medium, provided the original work is properly cited.

ORCID iDs

Tae Soo Kang 
<https://orcid.org/0000-0002-4298-6272>
Sang-Ho Park 
<https://orcid.org/0000-0001-7912-0336>

Funding

This study was supported by Soonchunhyang research fund.

Conflict of Interest

The authors have no financial conflicts of interest.

Author Contributions

Conceptualization: Park SH, Kang TS, Choi HY; Data curation: Park SH, Kang TS, Choi HY; Methodology: Park SH; Writing - original draft: Park SH, Choi HY; Writing - review & editing: Park SH, Kang TS.

level of his serum free cortisol in the morning was 10.18 $\mu\text{g/dL}$. The interpretation of this test result was that a state of adrenal insufficiency could have occurred considering the critical illness. After administration of steroid, inotropes could be discontinued (**Figure 2**).

Myocardial stunning at acute myocardial infarction (AMI) is the main underlying mechanism of acute pump failure;¹⁾²⁾ this means that the myocardium can be recovered if the management for AMI are appropriately performed at the beginning. However, despite proper management, some patients who do not recover from shock state are occasionally encountered. Adrenal insufficiency should be considered as a differential diagnosis, particularly when shock persists after improvement of ejection fraction after PCI in AMI.

REFERENCES

1. Vincent JL, De Backer D. Circulatory shock. *N Engl J Med* 2013;369:1726-34.
[PUBMED](#) | [CROSSREF](#)
2. Reynolds HR, Hochman JS. Cardiogenic shock: current concepts and improving outcomes. *Circulation* 2008;117:686-97.
[PUBMED](#) | [CROSSREF](#)