

Editorial



Distal Radial Approach through the Anatomical Snuff Box for Coronary Angiography and Percutaneous Coronary Intervention

Jae-Hyung Roh, MD, PhD, and Jae-Hwan Lee , MD, PhD

Division of Cardiology, Department of Internal Medicine, Chungnam National University Hospital, Chungnam National University School of Medicine, Daejeon, Korea

OPEN ACCESS

Received: Aug 27, 2018

Accepted: Sep 17, 2018

Correspondence to

Jae-Hwan Lee, MD, PhD

Division of Cardiology, Department of Internal Medicine, Chungnam National University Hospital, Chungnam National University School of Medicine, 282, Munhwa-ro, Jung-gu, Daejeon 35015, Korea.

E-mail: myheart@cnu.ac.kr

Copyright © 2018. The Korean Society of Cardiology

This is an Open Access article distributed under the terms of the Creative Commons Attribution Non-Commercial License (<https://creativecommons.org/licenses/by-nc/4.0>) which permits unrestricted noncommercial use, distribution, and reproduction in any medium, provided the original work is properly cited.

ORCID iDs

Jae-Hwan Lee

<https://orcid.org/0000-0002-6561-7760>

Conflict of Interest

The authors have no financial conflicts of interest.

Author Contributions

Conceptualization: Roh JH, Lee JH; Data curation: Roh JH, Lee JH; Resources: Roh JH; Supervision: Lee JH; Validation: Roh JH, Lee JH; Visualization: Lee JH; Writing - original draft: Roh JH, Lee JH; Writing - review & editing: Roh JH, Lee JH.

► See the article “Feasibility of Coronary Angiography and Percutaneous Coronary Intervention via Left Snuffbox Approach” in volume 48 on page 1120.

The anatomical snuffbox, also known as the radial fossa, is a triangular-shaped depression on the radial, dorsal aspect of the hand at the level of the carpal bones. It is clearly observed when the thumb is extended (**Figure 1**).^{1,2)} The bottom of the snuffbox is supported by carpal bones composed of the scaphoid and trapezium. The medial and lateral borders are bounded by tendons of the extensor pollicis longus and the extensor pollicis brevis, respectively. The proximal border is formed by the styloid process of the radius. Within this narrow triangular space, various structures are located, including the distal radial artery (RA), a branch of the radial nerve, and the cephalic vein.

The anatomy of the hand arteries is illustrated in **Figure 2**. The RA gives off the superficial palmar branch before curving around the wrist. The superficial palmar branch passes through, occasionally over, thenar muscles and usually anastomoses with the end of ulnar artery (UA) to complete a superficial palmar arch (SPA). Thereafter, the RA passes across the floor of the anatomical snuff box and through the first interosseous space, crosses the palm, and ends up completing the deep palmar arch (DPA) at the fifth metacarpal base with deep palmar

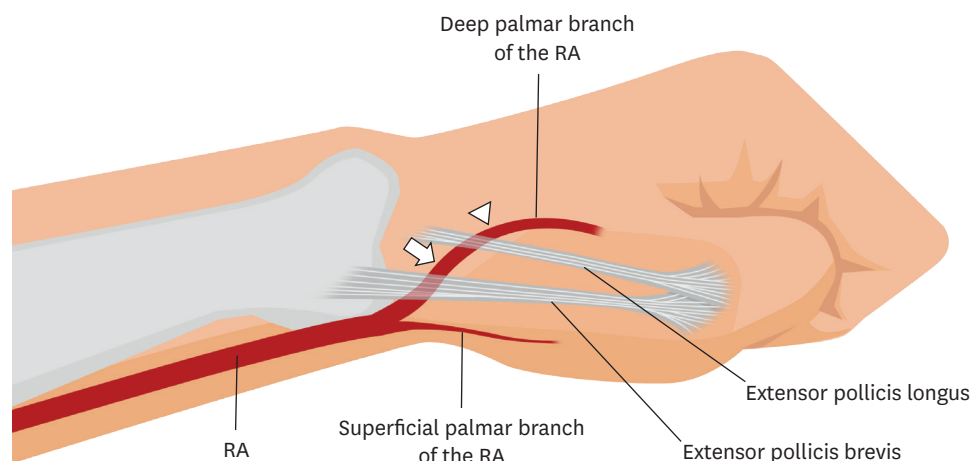


Figure 1. The pathway of RA via anatomical snuffbox and left hand posture of patient for puncture. The common puncture site (arrow) and the subsidiary puncture site (arrowhead). RA = radial artery.

The contents of the report are the author's own views and do not necessarily reflect the views of the *Korean Circulation Journal*.

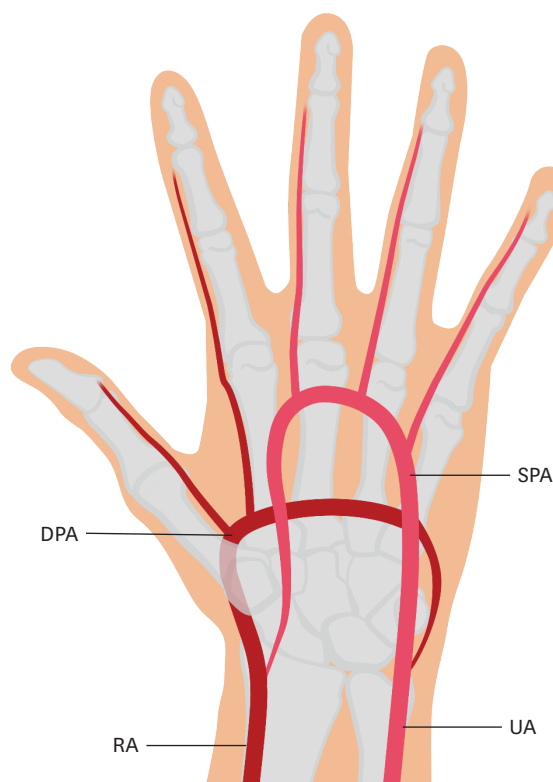


Figure 2. Anatomical structure of left hand arteries.
DPA = deep palmar arch; RA = radial artery; SPA = superficial palmar arch; UA = ulnar artery.

branch of the UA. The UA gives off the deep palmar branch before it runs across the palm and anastomoses with the superficial palmar branch of the RA to complete the SPA. Unlike the DPA fed mainly by the RA, the SPA is mainly supplied by the UA. There are 2 points distal to the wrist crease where arterial pulsation is so palpable that a vascular access could be tried: the RA on the anatomical snuff box, and the UA under the hypothenar muscles. Because the UA is located relatively deeper under the hypothenar muscles while vascular access though them usually is accompanied by more pain with lower success rate, the distal RA in the anatomical snuff box is occasionally used as an alternative to conventional radial access.

The distal radial access through the snuff box has recently been performed despite short available length, shallow depth, and small diameter of the RA in the snuff box with complex surrounding structures.^{3,4)} Kim et al.⁵⁾ have performed coronary angiography with the snuffbox approach for 132 of 150 enrolled patients. Quantitative analyses of angiographies revealed that diameters of radial arteries were smaller in the snuff box than those in conventional radial access sites.⁵⁾ For all patients, 6 Fr sheath was uneventfully introduced. They reported that 42 patients who needed coronary intervention for significant stenosis, 41 patients successfully underwent the procedure except 1 patient whose coronary lesion was so complex that intervention via the snuff box approach could not be conducted. Furthermore, it has been reported that the snuffbox approach can be applied without difficulty even for left main coronary intervention.⁶⁾

The snuff box approach has numerous advantages over conventional radial access. First, even if the vascular access has blocked the artery, blood supply to the hand would maintain

via the SPA. Second, hard structures (e.g., carpal bones) just underneath the access site and the small diameter of the distal RA in the snuff box make hemostasis easy compared to conventional radial approach. Third, subcutaneous hematoma rarely spreads to the upper part of the forearm. Fourth, no need for compression around the wrist for hemostasis makes the wrist free to move, which limits venous congestion of the hand. Fifth, in case of vasospasm and hematoma from unsuccessful needling which make further trials harder, an operator could easily move to the conventional radial approach. Occasionally, needling beyond the extensor pollicis longus, the medial border of the snuff box, can be tried in such a situation (**Figure 1**, arrowhead). Sixth, for patients with chronic kidney disease, vascular injury caused by the conventional radial approach occasionally preclude arterio-venous fistula formation for hemodialysis. On the other hand, the snuff box approach spares the site for future arterio-venous fistula. Seventh, the snuff box approach saves more undamaged length of the RA for potential coronary artery bypass surgery candidates.

Although both left and right snuffbox approaches are feasible for most patients, the left snuffbox approach is more attractive to many interventional cardiologists because many disadvantages of conventional left radial approach can be overcome by it. Interventionists who prefer the left radial approach argue that the right subclavian artery is more likely to be tortuous and that via the left radial approach, the catheter is easily manipulated in the same way as it is via the femoral approach while giving more back-up support than that via the right radial approach. Despite these advantages of the left radial approach, many interventionists stick to the right radial approach for several reasons. First, operators often need to move to the left side of patients for needling. Second, leaning across the table to the left wrist of patients increases the chance of operators' radiation exposure, especially when operators are short in height and/or patients are obese. However, the left snuff box approach ameliorates disadvantages caused by the conventional left radial approach by pulling patients' left hand over to the right inguinal area. In this position, operators can perform needling and procedures in the same way as they do via the right radial approach. Furthermore, the left snuff box approach is especially helpful for right-handed patients. It lets patients freely use their dominant hand immediately after the procedure, which facilitates their returning to work.

Nevertheless, there are several disadvantages of the snuff box approach. First, because the RA is smaller in caliber, more tortuous, and more vulnerable to spasm in the anatomical snuffbox, needling is more difficult than that via the conventional radial approach. This explains why Kim et al.⁵⁾ have reported success rate of about 90%. Second, because of the proximity of the radial nerve and carpal bones, needling can easily cause pain by irritating nerve and periosteum. Nerve injuries caused by the conventional radial approach have been reported.⁷⁾ However, there is no report on such injuries from the snuff box approach yet. This might be because of their recent introduction. Third, the scant soft tissue around the snuff box cannot secure the sheath properly. Fourth, since the RA is small in caliber in the snuff box, sheaths larger than 7 Fr are difficult to be introduced. Kim et al.⁵⁾ have reported that they are able to introduce 6 Fr sheaths for all 132 patients whose arteries are successfully punctured in the snuff box. Fifth, because of tortuosity of the RA in the snuff box, a floppy 0.018- or 0.014-inch guidewire may be required. Sixth, about 3–5 cm distal to the conventional radial access, the snuff box approach can reduce the effective length of the guiding catheter. Therefore, catheters may not reach the coronary ostium, especially in situations such as tall patients and tortuous arteries. For such situations, the catheter needs to be shortened, like distally located coronary lesions and the retrograde approach for chronic total occlusion lesion. Seventh, because there are many anatomic variations

below the wrist across patients, the snuff box approach is not always feasible. However, the availability of simple conversion to conventional radial approach makes it an easy target for a first shot.

In conclusion, distal radial approach through the anatomical snuff box is emerging as a feasible and safe alternative to conventional one with several advantages. It is very attractive in maximizing strengths of the conventional left radial approach. Therefore, Kim et al.'s data⁵⁾ warrant further studies on the snuff box approach in terms of various short- and long-term clinical outcomes under various clinical situations.

REFERENCES

1. Pyles ST, Scher KS. Cannulation of the radial artery in the anatomic snuffbox. *Surg Gynecol Obstet* 1983;156:227-8.
[PUBMED](#)
2. Deepika K, Palaniappan D, Fuhrman T, Saltzman B. Anatomic snuffbox radial artery cannulation. *Anesth Analg* 2010;111:1078-9.
[PUBMED](#) | [CROSSREF](#)
3. Kiemeneij F. Left distal transradial access in the anatomical snuffbox for coronary angiography (IdTRA) and interventions (IdTRI). *EuroIntervention* 2017;13:851-7.
[PUBMED](#) | [CROSSREF](#)
4. Pua U, Quek LHH. "Snuffbox" distal radial access. *J Vasc Interv Radiol* 2018;29:44.
[PUBMED](#) | [CROSSREF](#)
5. Kim Y, Ahn Y, Kim I, et al. Feasibility of coronary angiography and percutaneous coronary intervention via left snuffbox approach. *Korean Circ J* 2018;48:1120-30.
[PUBMED](#) | [CROSSREF](#)
6. Kim Y, Jeong MH, Kim I, et al. Intravascular ultrasound-guided percutaneous coronary intervention with drug-eluting stent for unprotected left main disease via left snuffbox approach. *Korean Circ J* 2018;48:532-3.
[PUBMED](#) | [CROSSREF](#)
7. Jang HJ, Kim JY, Han JD, et al. Numbness after transradial cardiac catheterization: the results from a nerve conduction study of the superficial radial nerve. *Korean Circ J* 2016;46:161-8.
[PUBMED](#) | [CROSSREF](#)