

심근교와 연관된 급성 심근경색의 치료로 시행한 일차적 관동맥 스텐트 삽입술 1예

김기석 · 김형삼 · 오석진 · 배상석 · 배장환 · 연태진 · 김동운 · 조명찬

A Case of Acute Myocardial Infarction Associated with Myocardial Bridge Treated by Primary Coronary Stenting

Ki Seok Kim, MD, Hyoung Sam Kim, MD, Seok Jin Oh, MD, Sang Seok Bae, MD,
Jang Whan Bae, MD, Tae Jin Youn, MD, Dong Woon Kim, MD and Myeong Chan Cho, MD

Department of Internal Medicine, College of Medicine, Chungbuk National University, Cheongju, Korea

ABSTRACT

The clinical significance of myocardial bridges (MBs) is variable, and most patients are asymptomatic. However, angina, myocardial infarction and sudden death, associated with MBs, have been reported. Intracoronary stents offer a novel, and potentially definitive, treatment for myocardial ischemia associated with clinically significant MBs. We describe the use of intracoronary stenting for primary angioplasty in a patient with an anterior myocardial infarction associated with MBs. (**Korean Circulation J 2002;32(6):517-520**)

KEY WORDS : Myocardial bridge ; Stents ; Myocardial infarction ; Therapeutics.

서론

가, ,

3-5)

15~85%

0.5~2.5%

3)6-9)

2)

0.95%

, 80%가

, 11.1%

: 2002 3 12

: 2002 4 25

: , 361 - 711

62

증례

: (043) 269 - 6013 · : (043) 273 - 3252

59

가

E - mail : ytjmd@med.chungbuk.ac.kr

(30~190 IU/L), CK-MB : 15 IU/L(1~16 IU/L),
 LDH : 332 IU/L(220~470 IU/L), Tn-T : negative
 (0.011, <0.1 µg/mL), myoglobin : 42.84 ng/mL(28~
 72 ng/mL) . 238 mg/
 dL, LDL 175 mg/dL .
 (Fig. 1). CK : 49 IU/L

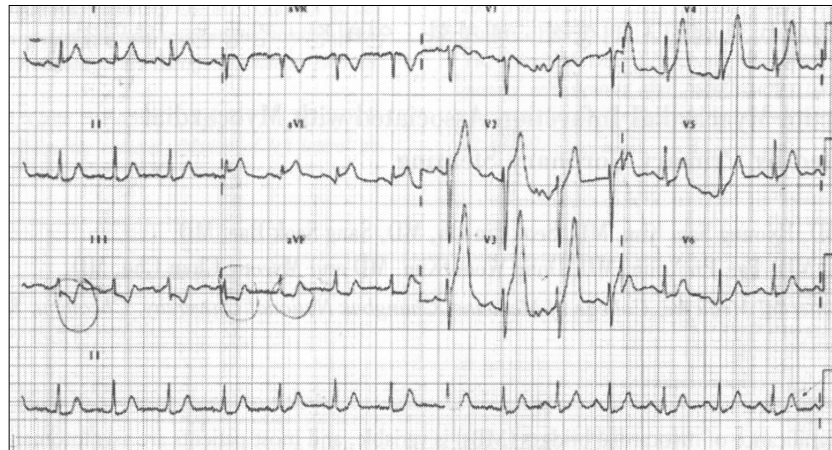


Fig. 1. Electrocardiogram showed tall T in leads V1 to V4 and ST segment depression in inferior leads.

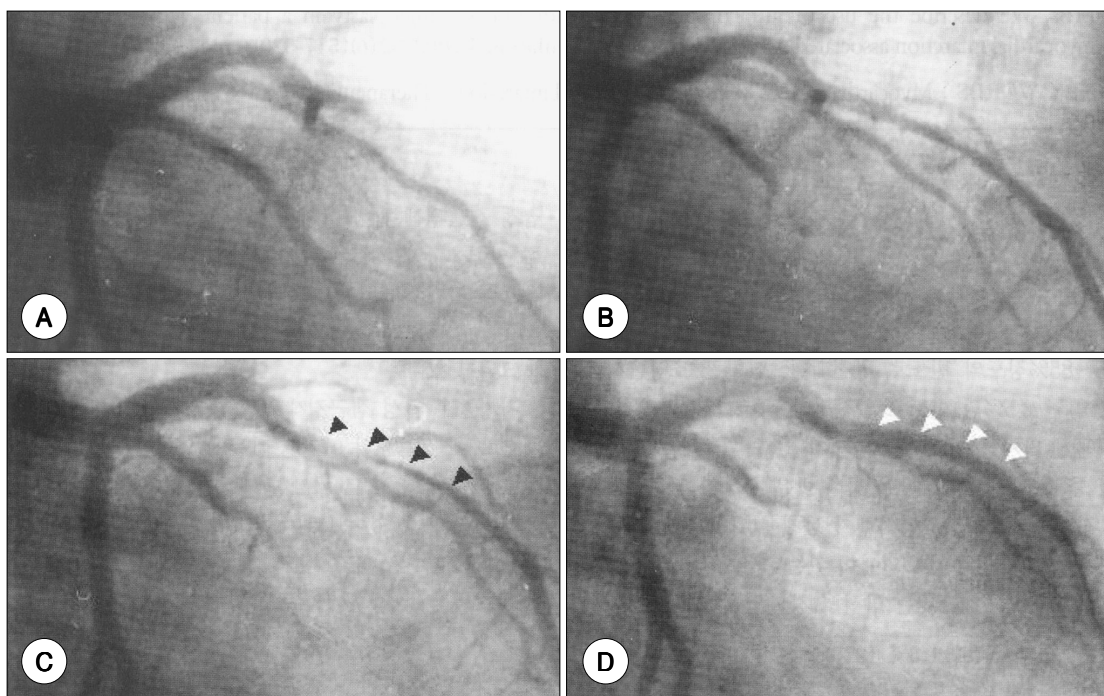


Fig. 2. Left coronary angiogram showed total occlusion of mid left anterior descending artery (RAO caudal view) (A). Left coronary angiogram in diastole after balloon dilation (B). Left coronary angiogram in systole after balloon dilation (C). Significant luminal narrowing was observed with myocardial bridge (). Left coronary angiogram in systole after stent insertion (D). Significant luminal narrowing was disappeared ().

, de Winter ⁷⁾
 (Fig. 2A). Trooper 0.014 IVUS , 가
 , 2.0 × 20 mm Adante balloon(Boston Scientific Simed. Ltd, Maple, USA) pre - dilation , 2.5 × 24 mm Adante balloon
 6 60 ,
 TIMI 가 , ,
 35% (Fig. ⁴⁾ , ¹²⁾
 2B). , 20 mm
 가 , (mural
 90% (Fig. 2C). aneurysm)
 2.5 × 25 mm Nir W/SOX(Boston Scientific Ireland Ltd, Galway, Ireland) , 가 ⁴⁾¹¹⁾
 10 60
 (Fig. 2D). ,

고 찰

primitive coronary intratrabeular arterial network ,
 , 가 가
 , , , 가 ,
 , ³⁻⁵⁾ , de Winter ⁷⁾
 , (spasm) , 3
 (kinking), ,
 가 , 가 CA-
 , BG 가
 , 가가 ,
 90% , 가 20 mm
³⁾¹⁰⁾ , Ge ¹⁾ ,
 IVUS(IVUS : intravascular
 ultrasound) , 가

요 약

59

가

중심 단어 : ; ; ; .

REFERENCES

- 1) Ge J, Erbel R, Rupprecht HJ, Koch L, Kearney P, Gorge G, Haude M, Meyer J. *Comparison of intravascular ultrasound and angiography in the assessment of myocardial bridging.* *Circulation* 1994;89:1725-32.
- 2) Kim W, Jeong MH, Kim KH, Park JC, Kim KH, Lee SW, Kim NH, Ahn YK, Cho JG, Park JC, Kang JC. *Clinical and angiographic characteristics, and long-term clinical follow up of myocardial bridge.* *Korean Circ J* 2000;30:819-26.
- 3) Smith SC, Taber MT, Robiolio PA, Lasala JM. *Acute myocardial infarction caused by a myocardial bridge treated with intracoronary stenting.* *Cathet Cardiovasc Diagn* 1997;42:209-12.
- 4) Roul G, Sens P, Germain P, Bareiss P. *Myocardial bridging as a cause of acute transient left heart dysfunction.* *Chest* 1999;116:574-80.
- 5) Bashour TT, Espinosa E, Blumenthal J, Wong T, Mason DT. *Myocardial infarction caused by coronary artery myocardial bridge.* *Am Heart J* 1997;133:473-7.
- 6) Stables RH, Knight CJ, McNeill JG, Sigwart U. *Coronary stenting in the management of myocardial ischemia caused by muscle bridging.* *Br Heart J* 1995;74:90-2.
- 7) de Winter RJ, Kok WEM, Piek JJ. *Coronary arteriosclerosis within a myocardial bridge, not a benign condition.* *Heart* 1998;80:91-3.
- 8) Bayes A, Marti V, Auge JM. *Coronary stenting for symptomatic myocardial bridging.* *Heart* 1998;80:102-3.
- 9) Choi SH, Shim SJ, Byun KH, Choi DH, Shim WH. *A case of coronary stenting in the management of myocardial ischemia caused by myocardial bridging.* *Korean Circ J* 2001;31:940-4.
- 10) Collieran JA, Tierney JP, Prokopchak R, Diver DJ, Breall JA. *Angiographic presence of myocardial bridge after successful percutaneous transluminal coronary angioplasty.* *Am Heart J* 1996;131:196-8.
- 11) Prendergast BD, Kerr F, Starkey IR. *Normalisation of abnormal coronary fractional flow reserve associated with myocardial bridging using an intracoronary stent.* *Heart* 2000;83:705-7.
- 12) Kwak SY, Park SC, Kim YM, Kim SK, Lee KH, Hyon MS, Kwon YJ, Youm W. *A case of Q wave acute myocardial infarction in patients with myocardial bridging caused by fibrous band.* *Korean Circ J* 1998;28:2061-5.
- 13) Agirbasli M, Hillegass WB Jr, Chapman GD, Brott BC. *Stent procedure complicated by thrombus formation distal to the lesion within a muscle bridge.* *Cathet Cardiovasc Diagn* 1998;43:73-6.