

급사의 원인으로서의 부정맥·야기성 우심실심근증

박태인¹ · 김동자¹ · 손윤경¹ · 채종민² ·곽정식²
 박헌식³ · 조용근³ · 채성철³ · 전재은³ · 박의현³

Arrhythmogenic Right Ventricular Cardiomyopathy as a Cause of Sudden Unexplained Death

Tae In Park, MD, PhD¹, Dong Ja Kim, MD¹, Yoon Kyung Sohn, MD, PhD¹, Jong Min Chae, MD, PhD²,
 Jung Sik Kwak, MD, PhD², Hun Sik Park, MD³, Yongkeun Cho, MD, PhD³,
 Shung Chull Chae, MD, PhD³, Jae Eun Chun, MD³, PhD and Eu Hyun Park, MD, PhD³

¹Department of Pathology, ²Forensic Medicine, ³Internal Medicine, College of Medicine, Kyungpook National University, Taegu, Korea

ABSTRACT

Objective : Arrhythmogenic right ventricular cardiomyopathy (ARVC) is a progressive cardiac muscle disease characterized as a progressive fibrofatty replacement of the right ventricle, severe ventricular arrhythmia, and sudden death. However, there has been no report of ARVC as a cause of sudden death in Korea. **Methods and Results :** Postmortem studies were done on 115 cases of sudden unexplained death at the department of legal medicine, school of medicine, Kyungpook National University in year 1999. We identified 7 cases (6%) of typical ARVC with no other identifiable cause of sudden death. The subjects included 5 males and 2 females, ranging in age from 19 to 41 years (mean 29.7 years). All were found dead at in bed (5 cases) or in the workshop (2 cases). Five cases were fibrofatty types and two cases were fatty types. Right ventricular aneurysm, inflammatory infiltrates and left ventricular involvement were found in 4, 2 and 1 cases, respectively. Two cases had a family history of sudden death before age 40. No one was suspected of having cardiovascular disease or ARVC before death. **Conclusion :** These findings indicate that ARVC in the Taegu-Kyungpook area may be more frequent than previously thought. ARVC may be a major cause of sudden unexplained death. (**Korean Circulation J 2001;31(3):335-340**)

KEY WORDS : Arrhythmogenic right ventricular cardiomyopathy · Sudden death.

서론

(arrhythmogenic

: 2000 10 30
 : 2001 3 15
 : , 700 - 721 27가 50
 : (053) 420 - 5528 · : (053) 426 - 2046
 E - mail : hspark@knu.ac.kr.

right ventricular cardiomyopathy (ARVC)¹⁻³⁾ 가 1

ARVC 1 가 7

가 가 가 가 , 가 2

가 가 가 가 .

incomplete penetrance¹⁾⁴⁻⁹⁾ , , , ,

ARVC 10% 5 μm hematoxylineosin Masson's trichrome . Masson's trichrome 가 5%

ARVC¹⁰⁾¹¹⁾ ARVC fibrofatty fibrolipomatorus type fatty lipomatous type

1999 1 12

ARVC

재료 및 방법

결 과

1999 1 12 7 가 5 , 가 2 , 19

115 41 29.7 . 5

ARVC 2

9 7

1 . 가 2

가 2 1 15

6 . ARVC 가, 1 39 가 (Table 1).

free wall 75%

Table 1. Clinical characteristics of subjects

| Case No. | Age/Sex | Previous symptoms | Family history of sudden death* | Circumstances of death |
|----------|---------|-------------------|---------------------------------|------------------------|
| 1 | 19/F | - | + | Found dead in bed |
| 2 | 26/M | - | + | Found dead in bed |
| 3 | 29/M | ND | ND | Found dead in bed |
| 4 | 33/M | ND | ND | Found dead in workshop |
| 5 | 27/F | ND | ND | Found dead in bed |
| 6 | 33/M | ND | ND | Found dead in workshop |
| 7 | 41/M | ND | ND | Found dead in bed |

* : before age 40, ND : no data, M : male, F : female

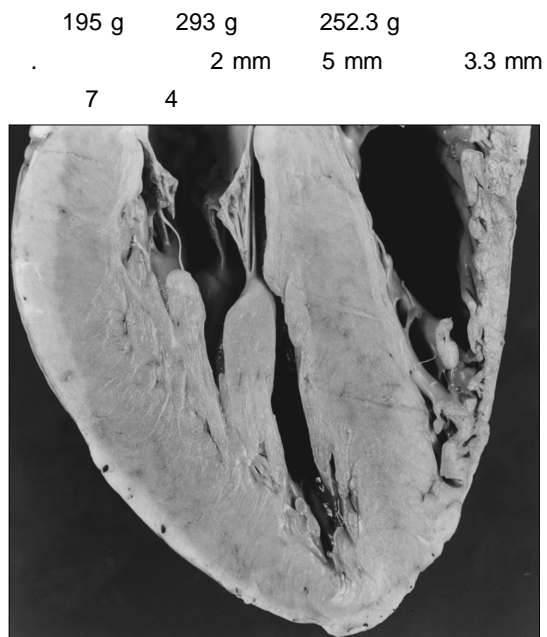


Fig. 1. Gross photograph of the case 1 shows apical myocardial thinning and gross fat infiltrates.

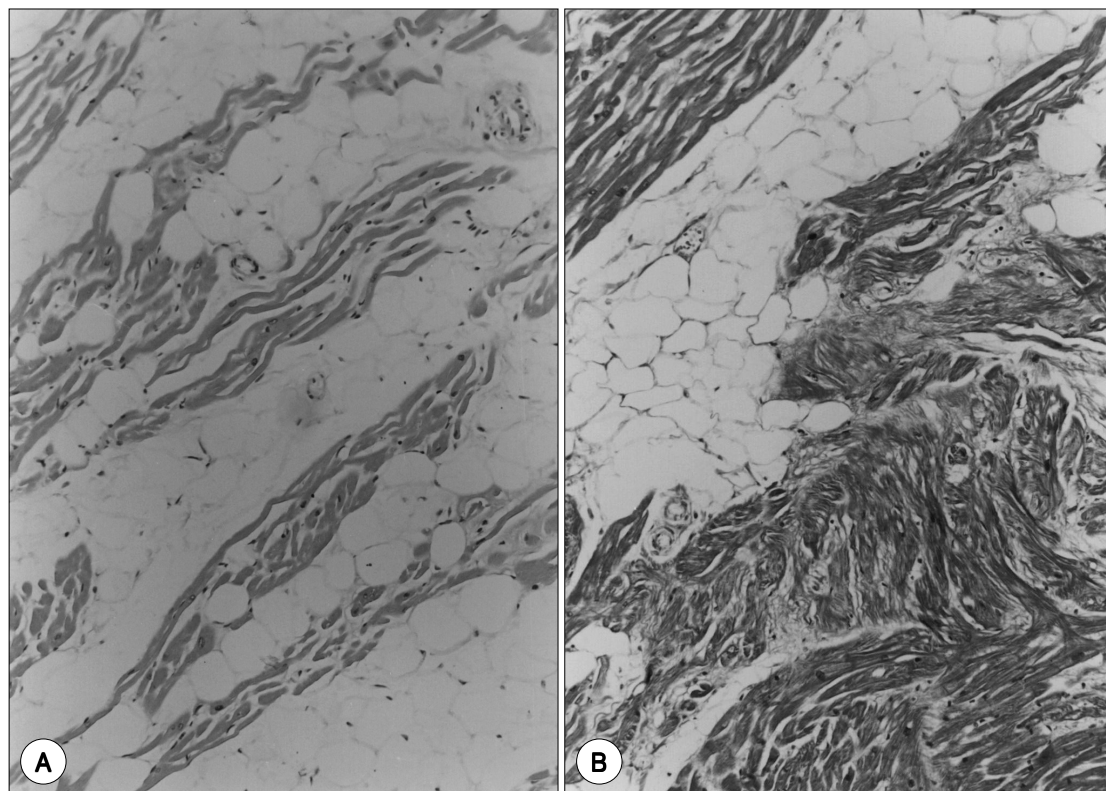


Fig. 2. Arrhythmogenic right ventricular cardiomyopathy. A : Histologically, RV free wall shows marked infiltration of fat within cardiac muscle fibers. B : Masson's trichrome stain demonstrates some amounts of fibrous tissue (blue areas) in addition to fat.

(Fig. 1).

가 . 5
fibrofatty type, 2
fatty type (Fig. 2). 6
fibro-
fatty type 1
, fibrofatty type 2
(Table 2).
고 찰

Marcus Thiene 1980
ARVC,
가
1)4)12)

| Case No. | Heart weight (g) | Thickness of RV wall (mm) | Histologic pattern | LV involvement | RV anuerysm | Inflammatory infiltrates |
|----------|------------------|---------------------------|--------------------|----------------|-------------|--------------------------|
| 1 | 195 | 2 | Fibrofatty | - | + | + |
| 2 | 227 | 2 | Fibrofatty | + | + | + |
| 3 | 260 | 4 | Fibrofatty | - | - | - |
| 4 | 268 | 4 | Fibrofatty | - | - | - |
| 5 | 243 | 3 | Fatty | - | + | - |
| 6 | 280 | 3 | Fatty | - | + | - |
| 7 | 293 | 5 | Fibrofatty | - | - | - |

[illegible]

가⁶⁾⁷⁾ 가 가 ARVC

Mallat²⁶⁾ ARVC apoptosis ARVC

apoptosis가

재료 및 방법 : 1999 1 12

Valente²⁷⁾ 115

apoptosis가 가 ARVC

7

가

Bangugut

Bangugut 가 hema -

toxylin - eosin Masson's trichrome

ARVC free wall

75%

Masson's trichrome

가 5% fibrofatty fibrolipo - fatty

matorus type lipomatous type

결 과 :

195 g 293 g 252.3 g

7

5

가 fibrofatty type, 2

ARVC

2)4)6)9)

ARVC

가

2 mm 5 mm 3.3 mm

7 4

fibrofatty type fatty type 2

6

fibrofatty type 1

fibrofatty type 2

요 약

연구배경 : ARVC

결 론 :

중심 단어 :

REFERENCES

- 1) Thiene G, Nava A, Corrado D, Rossi L, Pennelli N. Right ventricular cardiomyopathy and sudden death in young people. *N Eng J Med* 1988;318:129-33.
- 2) Topaz O, Edwards JE. Pathologic features of sudden death in children, adolescents, and young adults. *Chest* 1985;87:476-82.
- 3) Shen WK, Edwards WD, Hammill SC, Bailey KR, Ballard DJ, Gersh BJ. Sudden unexpected nontraumatic death in 54 young adults: A 30-year population-based study. *Am J Cardiol* 1995;76:148-52.
- 4) Marcus FI, Fontaine GH, Guiraudon G, Frank R, Laurenceau JL, Malergue C, et al. Right ventricular dysplasia: A report of 24 adult cases. *Circulation* 1982;65:384-98.
- 5) Pinamonti B, Sinagra G, Salvi A, Lenarda A, Morgera T, Silvestri F, et al. Left ventricular involvement in right ventricular dysplasia. *Am Heart J* 1992;123:711-24.
- 6) Basso C, Thiene G, Corrado D, Angelini A, Nava A, Valente M. Arrhythmogenic right ventricular cardiomyopathy. Dysplasia, dystrophy, or myocarditis? *Circulation* 1996;94:983-91.
- 7) Burke AP, Farb A, Tashko G, Virmani R. Arrhythmogenic right ventricular cardiomyopathy and fatty replacement of the right ventricular myocardium. Are they different disease? *Circulation* 1998;97:1571-80.
- 8) Corrado D, Basso C, Thiene G, McKenna WJ, Davies MJ, Fontaliran F, et al. Spectrum of clinicopathologic manifestations of arrhythmogenic right ventricular cardiomyopathy/dysplasia: A multicenter study. *J Am Coll Cardiol* 1997;30:1512-20.
- 9) Kullo IJ, Edwards WD, Seward JB. Right ventricular dysplasia: the Mayo experience. *Mayo Clin Proc* 1995;70:541-8.
- 10) 최기준 · 권현철 · 남기병 · 김용진 · 김효수 · 손대원, et al. 부정맥 유발성 우심실이형성증 1예. *순환기* 1995;25:1057-63.
- 11) 김영권 · 한동선 · 권숙희 · 이명인 · 이학중. Arrhythmogenic right ventricular dysplasia 1예. *순환기* 1996;26:1204-9.
- 12) Osler W. *The principles and practice of medicine*. 6th ed. New York and London: D Appleton and company;1906. p.826.
- 13) Richardson P, McKenna W, Bristow M, Maisch B, Mautner B, O'Connell J, et al. Report of the 1995 World Health Organization/International society and federation of cardiology task force on the definition and classification of cardiomyopathies. *Circulation* 1996;93:841-2.
- 14) Corrado D, Thiene G, Nava A, Rossi L, Pennelli N. Sudden death in young competitive athletes: clinicopathologic correlations in 22 cases. *Am J Med* 1990;89:588-96.
- 15) Maron BJ, Shirani J, Poliac LC, Mathebege R, Roberts WC, Mueller FO. Sudden death in young competitive athletes. Clinical, demographic, and pathological profiles. *JAMA* 1996;276:199-204.
- 16) Matsumori A, Kawai C. Coxsackie virus B3 perimyocarditis in BALB/c mice: experimental model of chronic perimyocarditis in the right ventricle. *J Pathol* 1980;131:97-106.
- 17) Grumbach IM, Heim A, Vohhof S, Stille-Siegener M, Mall G, Gonska BD, et al. Coxsackievirus genome in myocardium of patients with arrhythmogenic right ventricular dysplasia/cardiomyopathy. *Cardiology* 1998;89:241-5.
- 18) Rampazzo A, Nava A, Danielli GA, Buja G, Daliento L, Fasoli G, et al. The gene for arrhythmogenic right ventricular cardiomyopathy maps to chromosome 14q23-q24. *Hum Mol Genet* 1994;3:959-62.
- 19) Rampazzo A, Nava A, Erne P, Eberhard M, Vian E, Slomp P, et al. A new locus for arrhythmogenic right ventricular cardiomyopathy (ARVD2) maps to chromosome 1q42-q43. *Hum Mol Genet* 1995;4:2151-4.
- 20) Severini GM, Krajcinovic M, Pinamonti B, Sinagra G, Fioretti P, Brunazzi MC, et al. A new locus for arrhythmogenic right ventricular dysplasia on the long arm of chromosome 14. *Genomics* 1996;31:193-200.
- 21) Rampazzo A, Nava A, Miorin M, Fonderico P, Pope B, Tiso N, et al. ARVD4, a new locus for arrhythmogenic right ventricular cardiomyopathy, maps to chromosome 2 long arm. *Genomics* 1997;45:259-63.
- 22) Coonar AS, Protonotarios N, Tsatsopoulou A, Needham EW, Houlston RS, Cliff S, et al. Gene for arrhythmogenic right ventricular cardiomyopathy with diffuse nonepidermolytic palmoplantar keratoderma and woolly hair (Naxos disease) maps to 17q21. *Circulation* 1998;97:2049-58.
- 23) Ahmad F, Li D, Karibe A, Gonzalez O, Tapscott T, Hill R, et al. Localization of a gene responsible for arrhythmogenic right ventricular dysplasia to chromosome 3p23. *Circulation* 1998;98:2791-5.
- 24) Li D, Ahmad F, Gardner MJ, Weilbaecher D, Hill R, Karibe A, et al. The locus of a novel gene responsible for arrhythmogenic right ventricular dysplasia characterized by early onset and high penetrance maps to chromosome 10p12-p14. *Am J Hum Genet* 2000;66:148-56.
- 25) Daliento L, Turrini P, Nava A, Rizzoli G, Angelini A, Buja G, et al. Arrhythmogenic right ventricular cardiomyopathy in young versus adult patients: similarities and differences. *J Am Coll Cardiol* 1995;25:655-64.
- 26) Mallat Z, Tedgui A, Fontaliran F, Frank R, Durigon M, Fontaine G. Evidence of apoptosis in arrhythmogenic right ventricular dysplasia. *N Engl J Med* 1996;335:1190-6.
- 27) Valente M, Calabrese F, Thiene G, Angelini A, Basso C, Nava A, et al. In vivo evidence of apoptosis in arrhythmogenic right ventricular cardiomyopathy. *Am J Pathol* 1998;152:479-84.
- 28) Baron RC, Thacker SB, Gorelkin L, Vernon AA, Taylor WR, Choi K. Sudden death among Southeast Asian refugees. An unexplained nocturnal phenomenon. *JAMA* 1983;250:2947-51.