

우관동맥의 말단부에서 연장된 형태의 좌회선 관동맥 1예

가

백종태 · 진승원 · 장이선 · 김명숙 · 김용주 · 김희열
김종진 · 박준철 · 채장성 · 김재형 · 홍순조 · 최규보

A Case of Left Circumflex Coronary Artery Arising as a Terminal Extension of Right Coronary Artery

Jong-Tae Baek, MD, Seung-Won Jin, MD, Yi-Sun Jang, MD, Myung-Sook Kim, MD,
Yong-Joo Kim, MD, Hee-Yeul Kim, MD, Chong-Jin Kim, MD, Jun-Chul Park, MD,
Jang-Sung Chae, MD, Jae-Hyung Kim, MD, Soon-Jo Hong, MD and Kyu-Bo Choi, MD

Department of Internal Medicine, College of Medicine, The Catholic University of Korea, Seoul, Korea

ABSTRACT

Many types of coronary artery anomalies have been detected, and most of them occur in the left circumflex artery. Left circumflex coronary arteries arising from the right sinus of Valsalva or from the right coronary artery have been a commonly described anomaly in the pediatric as well as in the adult population. These anomalies may make an angiographic visualization of coronary circulation and may increase the risk of coronary artery trauma during the intervention or a cardiac surgery. So, the adequate visualization of these anomalies is essential for the proper management of patients. We report a 67-year-old female patient with angina and absent left circumflex coronary artery, in which the artery arose as a terminal extension of the right coronary artery. Angiographically nonvisualization of the left circumflex coronary artery from the left coronary artery is presented. (**Korean Circulation J 2001;31(1):125-128**)

KEY WORDS : Left circumflex coronary artery · Coronary artery anomaly.

서 론

가 가 .

,

.

Valsalva

가 가

,¹⁻⁴⁾

: 2000 7 10

: 2001 1 31

: , 301 - 723

520 - 2

가

: (042) 220 - 9504, 9517 ·

: (042) 255 - 8663

E - mail : 4831317@hananet.net

가

.

증례

67, 5, 15, 10, 9, 9, 65%, Dobutamine, 가 (10 µg/kg/min), 140/90 mm Hg, 92 / , 20 / , 가가 (30 µg/kg/min)

9,600/mm³, 12.7 g/dl, 38.4%, 251,000/mm³, 84 mg/dl, blood urea nitrogen 9.5 mg/dl, creatinine 0.81 mg/dl, AST/ALT 18/11 IU/L, cholesterol 165 mg/dl, triglyceride 52 mg/dl, high density lipoprotein - cholesterol 45.2 mg/dl, low density lipoprotein - cholesterol 110 mg/dl, prothrombin time(INR) 1.1, Troponin T 0.011 ng/ml, Creatinine phosphokinase - MB 0.716 ng/ml, Creatinine phosphokinase 56 IU/L Lactate dehydrogenase 350 IU/L

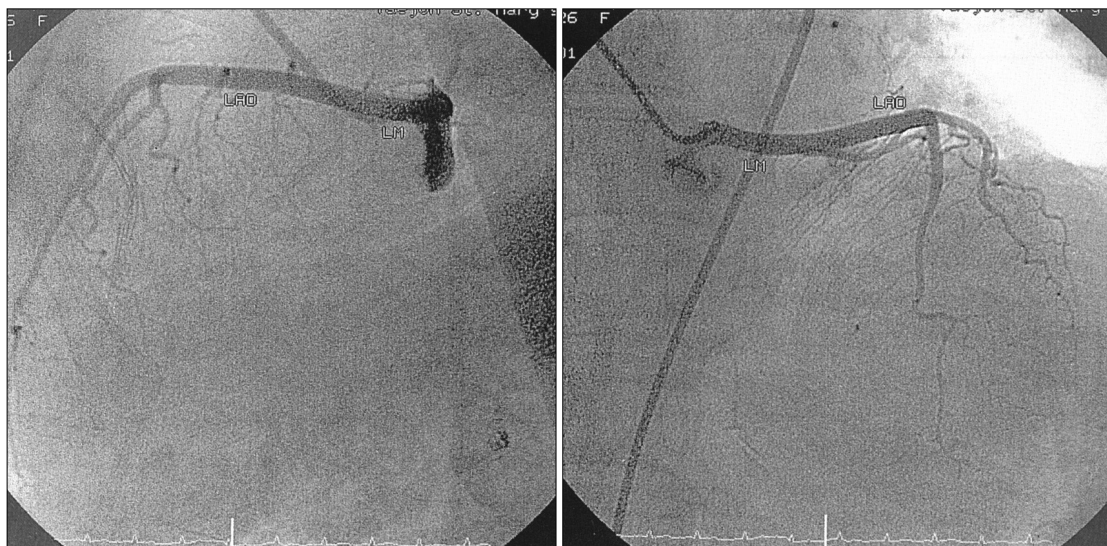


Fig. 1. Selective left coronary angiogram showed left anterior descending artery only, and no left circumflex artery originated from the left main trunk in the lateral view (left) and anteroposterior view (right).

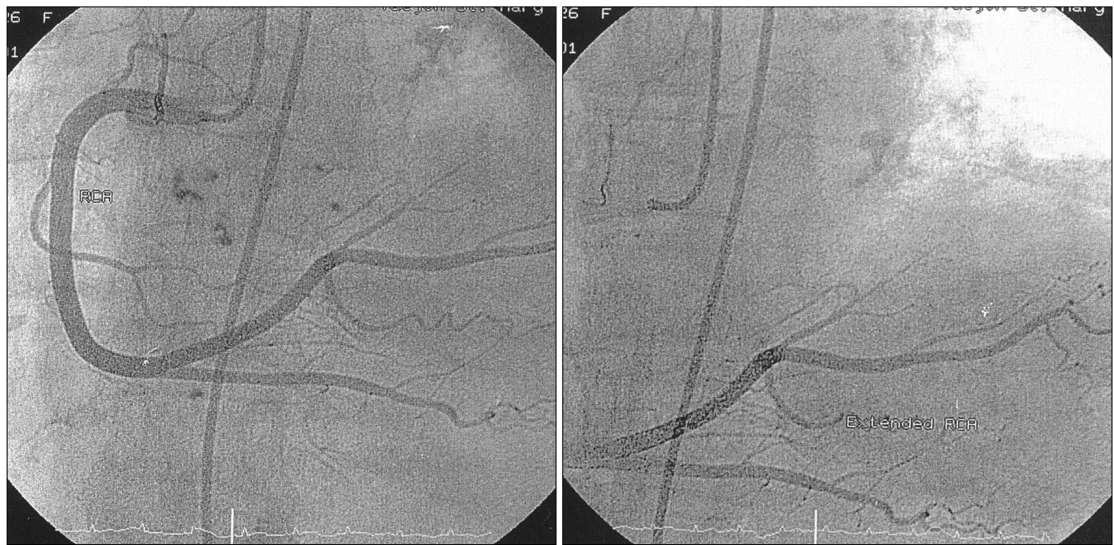

Fig. 2. Selective right coronary angiogram showed left circumflex artery arising as a terminal extension of right coronary artery in the anteroposterior view.

가 ,
0.2 2%
1-4) , Gentzler
300 1 가
6)
(Fig. 1). 가
drome) 19 (systolic click syn -
가 89%
가
(Fig. 2). ,
가
7)
76%
고 안
1933 Antopol 5)
가
1-4) 60%¹⁻²⁾
Vasalva 가 가

2)8)9) . 가 nitrate ergonovine

10) .

(stump)

11) Page 4) 가 (aortic root sign)

Valsalva

(sign of nonperfused myocardium) opacification Valsalva

가 12) 가

가

가

가

Dobutamine

중심 단어 :

REFERENCES

- 1) Click RL, Holmes DR, Vlietstra RE. *Anomalous coronary arteries: Location, degree of atherosclerosis and effect and on survival: A report from the coronary artery surgery study. J Am Coll Cardiol* 1989;13:531-7.
- 2) Sagkan O, Ornek E, Yesidag O. *Left circumflex coronary artery arising as a terminal extension of right coronary artery: A case report. Angiology* 1995;45:405-8.
- 3) Page HL Jr, Engel HJ, Campbell WB. *Anomalous origin of the left coronary artery: recognition, angiographic demonstration and clinical significance. Circulation* 1974; 50:768-73.
- 4) Ogden JA. *Congenital anomalies of the coronary arteries. Am J Cardiol* 1970;25:474-9.
- 5) Antopol W, Kugel MA. *Anomalous origin of the left circum-flex coronary artery. Am Heart J* 1933;8:802.
- 6) Gentzler RD, Gault JT, Liedtke AJ, McCann WD. *Congenital absence of the left circumflex artery in the systolic click syndrome. Circulation* 1975;52:490-6.
- 7) Donaldson RM, Raphael MJ. *Missing coronary artery: Review of the technical problems in coronary angiography resulting from anatomical variants. Br Heart J* 1982;47: 62-70.
- 8) Park JW, Cha KS, Park SW, Lee SH, Seo IA, Lee CJ, et al. *Congenital absence of left circumflex coronary artery: Circum-flex artery extended from right coronary artery. Korean Circulation J* 1999;29:67-72.
- 9) Honey M, Lincoln JC, Osborne MP. *Coarctation of the aorta with right aortic arch. Report of surgical correction in 2 cases: one with associated anomalous origin of circumflex coronary artery from right pulmonary artery. Br Heart J* 1974;37:937-45.
- 10) Roy PR, Saunders A, Sowton GE. *Review of the variations in origin of left coronary artery. Br Heart J* 1975; 372:87-92.
- 11) Leroy F, Germain S, Bauters C. *Abnormal origin of the left circumflex coronary artery: clinical, angiographic and prognostic aspect: apropos of 30 cases. Arch Mal Coeur Vaiss* 1992;85:993-9.
- 12) Carcia CM, Chandler J, Richard R. *Anomalous left circumflex artery from the right coronary artery: first adult case report. Am Heart J* 1992;123:526-8.