

장기 심방 정위에서 우측 상대정맥 결손과 심방중격 결손이 동반된 지속성 좌측 상대정맥 1례

민의정¹ · 박순성¹ · 강이석² · 이흥재²

Persistent Left Superior Vena Cava with Absent Right Superior Vena Cava and Large Atrial Septal Defect in Visceroatrial Situs Solitus

Eui Jeong Min, MD¹, Soon Seong Park, MD¹, I-Seok Kang, MD² and Heung Jae Lee, MD²

¹Department of Pediatrics, Inha General Hospital, College of Medicine, Inha University, Sungnam, Kyonggi,

²Pediatrics, Samsung Medical Center, Seoul, Korea

ABSTRACT

Absence of right superior vena cava (SVC) in visceratrial situs solitus is a rare (0.07% to 0.13%) congenital cardiovascular malformation, and little is known about the type and frequency of additional heart defects and arrhythmias. We reviewed previous publications and report the case of 8 month old male infant with absent right superior vena cava and persistent left superior vena cava and large secundum atrial septal defect, mild pulmonary valvular stenosis. (**Korean Circulation J 2000;30(8):1035-1039**)

KEY WORDS : Absent right superior vena cava · Persistent left superior vena cava · Secundum atrial septal defect.

서 론

(persistent left superior vena cava)
(left anterior cardinal vein)
가

0.07% 0.13%

(positional anomaly)
age anomaly)

(drain -

(coronary sinus)
가

: 2000 1 10

: 2000 7 15

: , 461 - 190

: (031) 720 - 5862 · : (031) 720 - 5869

E - mail : Parksoon@inha.ac.kr

1

중 레

: , , 8 .

: .

: 3

:

가 :

: 128 / , 44

/ , 36.7 . 10.16 g(50 75

), 98 cm(75 90) .

:

3/6

2

:

12,400/mm³, 11.6 gm/dl, 286,000

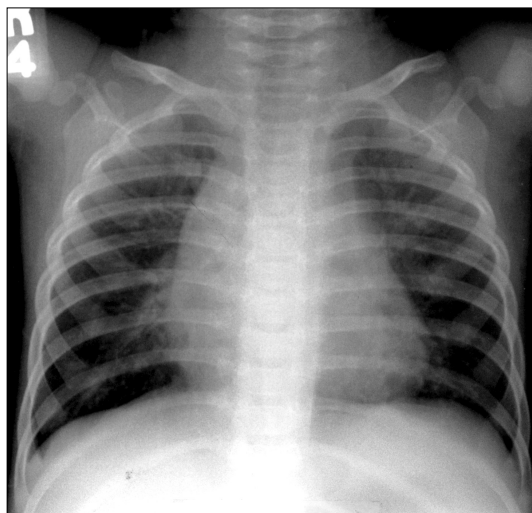


Fig. 1. Both lungs show diffuse bronchial wall thickening with peribronchial infiltration. The cardiac size appears to be within normal limit and pulmonary vascularity is increased.

/mm³

, X -

가 ,

가 (Fig. 1).

(sinus rhythm),

(Fig. 2).

(13.3 mm)

(=4.2 m/sec),

:

Qp/Qs 2.2 : 1

72 mmHg, 3 mmHg

32 mmHg, 18 mmHg .

:

(infundibular pul -

monary stenosis),

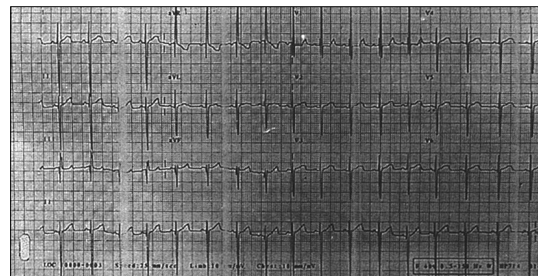


Fig. 2. ECG shows normal sinus rhythm, severe right axis deviation and right ventricular hypertrophy.

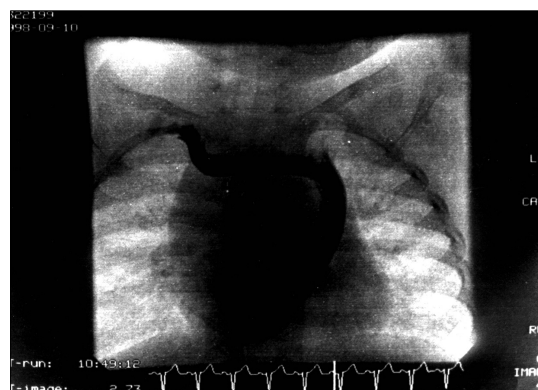


Fig. 3. Persistent left superior vena cava (LSVC), draining into coronary sinus (CS). The venous catheter was introduced through the femoral vein approach. Frontal angiogram with injection into the right innominate vein showing absent right superior vena cava.

(Fig. 3).

zygos vein) 가 ,

가

. Nash ²⁾

Cochrane ⁸⁾

고 찰

4

. Ba-

rtram ⁴⁾

0.3%¹⁾, 가 3 34%²⁾

Bartram ⁴⁾

1862 Halbertsma

1964 Karnegis ³⁾ 가

, 1997 Boston Bartram ⁴⁾

121 가 (36

case : 30%) ,

(29 case : 24%) ,

(56

case : 46%)

121 49 가

Lenox ⁵⁾ 0.13%, Bartram ⁴⁾ 0.09%

Nash ²⁾

1% 가

(superior vena cava)

(heart block)

8 (anterior cardinal vein)

(sinoatrial nodal dysfunction) 34.5% 가

(left innominate vein)

(complete) 8 , (va-

riable) 1 , 2 (second degree) 1 17%

(left common cardinal vein)

7%

(sinus venosus)

(coronary sinus)

3.5%

oblique vein of Marshall

(right common cardinal vein)

(65.5%)가

(34.5%) 가

(left superior vena cava) ⁶⁾

James

. Fraser ⁷⁾ left duct ⁹⁾

of Cuvier caudal junction Lenox ¹⁰⁾

3

(azygos vein) (hemia -

5 가 가 1 sive procedure)
 (AV node and bundle)
 Anderson ¹¹⁾
 가,
 Spiral CT,
 MRI
 56 (46%)
 (secundum ASD) 16%,
 11%, 9%, unroofed
 7%, 7%, 5%,
 5%,
 scimitar syndrome,
 2%
 16) 7)
 trisomy 21, trisomy 가
 18 7%
 가 ¹²⁾ (systemic venous drai -
 nage) 7)
 8
 가
 가 P 1
 P
 가 ⁵⁾ X - 요 약
 6)
¹³⁾ Oguni ¹⁴⁾ 1
 (cross - sectional index = parasternal long
 axis view × /)가 300
 mm²/m³ 가
 contrast
 15)
 (inva -

REFERENCES

- 1) Sanders JM. *Bilateral superior vena cava. Anat Rec* 1946; 94:657-9.

- 2) Nash EN, Moore GW, Hutchins GM. *Pathogenesis of persistent left superior vena cava with a coronary sinus connection. Pediatr Pathol* 1991;11:261-9.
- 3) Karnegis JN, Wang Y, Winchell P, Edwards JE. *Persistent left superior vena cava, fibrous remnant of the right superior vena cava and ventricular septal defect. Am J Cardiol* 1964;14:573-7.
- 4) Bartram U, Van Praagh S, Levine JC, Hines M. *Absent right superior vena cava in viscerotransposition. Am J Cardiol* 1997;80:175-83.
- 5) Lenox CC, Zuberbuhler JR, Park SC, Neches WH, Matthews RA, Fricker FJ, et al. *Absent right superior vena cava with persistent left superior vena cava: Implications and management. Am J Cardiol* 1980;45:117-22.
- 6) Taybi H, Kurlander GJ, Lurie PR, Campbell JA. *Anomalous systemic venous connection to the left atrium or to a pulmonary vein. Am J Roentgenol* 1965;94:62-77.
- 7) Fraser RS, Dvorkin J, Rossall RE, Eidem R. *Left superior vena cava: A review of associated congenital heart lesions, catheterization data and roentgenologic findings. Am J Med* 1961;31:711-6.
- 8) Cochrane AD, Marath A, Mee RB. *Can a dilated coronary sinus produce left ventricular inflow obstruction? An unrecognized entity. Ann Thorac Surg* 1994;58:1114-6.
- 9) James TN, Marshall TK, Edwards JE. *De subitaneis mortibus XX. Cardiac electrical instability in the presence of a left superior vena cava. Circulation* 1976;54:689-97.
- 10) Lenox CC, Hashida Y, Anderson RH, Hubbard JD. *Conduction tissue anomalies in absence of the right superior caval vein. Int J Cardiol* 1985;8:251-60.
- 11) Anderson RH, Latham RA. *The cellular architecture of the human atrioventricular node, with a note on its morphology in the presence of a left superior vena cava. J Anat* 1971;109:443-55.
- 12) Captain GM, Inmon TW, Pollock BE. *Persistent LSVC. Am Heart J* 1965;49:267.
- 13) Foale R, Bourdillon PD, Sommerville J, Rickards A. *Anomalous venous return: Recognition by 2-dimensional echocardiography. Eur Heart J* 1983;4:186.
- 14) Oguni H, Hatano T, Yamada T, Satomi G, Nakamura K, Imamura E, et al. *A case of absent right superior vena cava with persistent left superior vena cava: Cross-sectional echocardiographic diagnosis. Heart and vessels* 1985;1:239-43.
- 15) Gensini G, Caldini P, Blount SG. *Persistent left superior vena cava. Am J Cardiol* 1965;4:677.
- 16) Heager K, Juhlin I, Krook H. *Eisenmenger's complex accompanied by double superior vena cava, the left draining into the left atrium. Report of a case with fetal outcome due to vagus irritation during heart catheterization. Am Heart J* 1955;50:471.