

Non-Ischemic Cardiomyopathy Attributed to Adult Myotonic Dystrophy

Hyun Kyung Park, MD, Won Hyeong Park, MD, Dae-Geun Song, MD, Tae Gyoan Kim, MD, Bo Young Min, MD, Keun Lee, MD and Joong-Il Park, MD

Division of Cardiology, Department of Internal Medicine, Seoul Veterans Hospital, Seoul, Korea

ABSTRACT

In patients with myotonic dystrophy (MD), impairment of the conduction system is a common and progressive finding. However, only a few cases of MD with cardiomyopathy have been reported. Herein we report a case of MD with progressive non-ischemic cardiomyopathy and severe electrocardiographic abnormalities. (*Korean Circ J* 2009;39:340-342)

KEY WORDS: Myotonic dystrophy; Cardiomyopathy.

Introduction

Myotonic dystrophy (MD) is an inherited disorder transmitted in an autosomal dominant fashion.¹⁾ In MD, cardiac complications are the second most common cause of death in up to 30% of patients.²⁾ The cardiac involvement in patients with MD is usually characterized by arrhythmias, mainly due to conduction system abnormalities and an increased risk of sudden death. However, the occurrence of clinical myocardial disease appears to be rare, with only occasional reports of cardiomyopathy, and little is known about the clinical course as it relates to involvement of the myocardium.³⁾

Case

A 48-year-old male patient with a 10-year history of MD was referred for evaluation of an abnormal electrocardiogram (EKG). He had no subjective symptoms. MD was confirmed by rectus femoralis muscle biopsy that showed atrophy and degenerated fibers with internal nuclei, consistent with a myotonic myopathy (Fig. 1A). Electromyography showed myotonic discharges in several muscles. The patient had four uncles who all died because of myopathic disease before 50 years of age. The

patient had a 5-year-old niece with MD and cardiac involvement. The patient's daughter had a sudden death at 18 years of age.

The clinical examination revealed signs of classic MD. He had premature balding and had a characteristically thin face, hand myotonia, and bilateral weakness of the lower extremities. His blood pressure and heart rate were 110/80 mmHg and 57/min, respectively. An initial 12-lead EKG showed first-degree atrioventricular block (PR interval, 220 msec) and intraventricular conduction delay (QRS duration, 142 msec) (Fig. 1B). The serum creatine kinase was mildly elevated, but the creatine kinase-MB isoenzyme and troponin T levels were normal. No significant arrhythmias were observed on the initial 24-hour Holter monitoring. However, an inappropriate heart rate (83/min) response with suspicious atrioventricular block at stage 4 was observed on the exercise treadmill test. Initial transthoracic echocardiography (TTE) demonstrated hypokinesia of the inferior wall with mild left ventricular systolic dysfunction (ejection fraction, 45%). There were no signs of ischemic disease by coronary angiography; there was no fat infiltration or fibrosis demonstrated on cardiac MRI (Fig. 1C).

On the 1-year follow-up evaluation, intermittent left bundle branch block was observed on 24-hour Holter monitoring (Fig. 1D), and more aggravated regional wall motion abnormalities (hypokinesia of the anterolateral and inferior walls) were shown on TTE (ejection fraction, 40%) with dyspnea on exertion New York Heart Association. A permanent pacemaker insertion was considered to prevent sudden death based on American College of Cardiology/American Heart Association guidelines.

Received: April 11, 2009

Revision Received: June 15, 2009

Accepted: June 16, 2009

Correspondence: Joong-Il Park, MD, Division of Cardiology, Department of Internal Medicine, Seoul Veterans Hospital, 6-2 Dunchon-dong, Gangdong-gu, Seoul 134-791, Korea

Tel: 82-2-2225-1310, Fax: 82-2-484-8709

E-mail: drjipark@naver.com

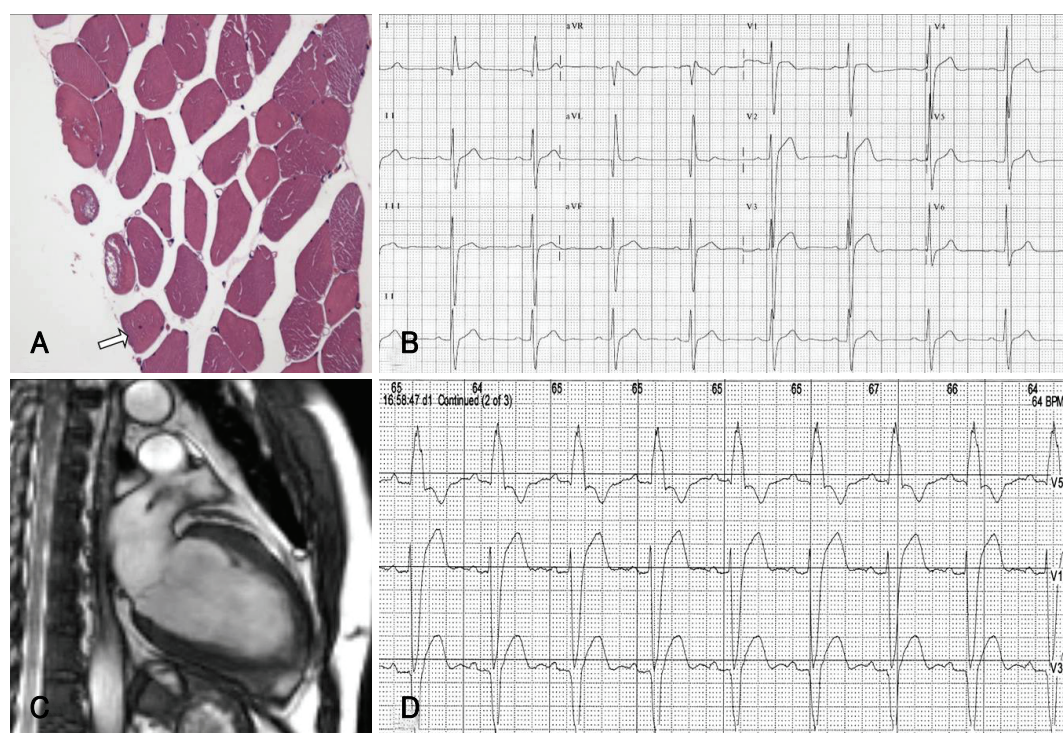


Fig. 1. A: Rectus femoralis muscle biopsy shows atrophy and degenerated fibers with internal nuclei (arrow). B: 12-lead EKG shows first-degree AV block (PR interval, 220 msec) and intraventricular conduction delay (QRS duration, 142 msec). C: cardiac MRI did not show an abnormal signal intensity of the myocardium suggestive of fat infiltration or fibrosis. D: intermittent left bundle branch block was observed on 24-hour Holter monitoring. EKG: electrocardiogram, AV: atrioventricular.

Discussion

While cardiac involvement (CI) in MD is usually characterized by arrhythmias (conduction abnormalities and tachyarrhythmias), myocardial damage with symptoms of heart failure is rare because CI is mainly due to selective degeneration of the infra-nodal conduction system.³⁻⁵⁾ On histologic evaluation, CI in MD involves interstitial myocardial fibrosis and fatty infiltration.⁶⁾ Interestingly, in the case described herein, there were no significant arrhythmias on EKG, no fibro-lipomatous changes, and no evidence of myocardial ischemia on cardiac MRI. However, the initial and follow-up EKGs showed decreased left ventricular systolic function and extended regional wall motion abnormalities. Therefore, serial EKGs may be a more useful imaging tool than CT or MRI for earlier detection of myocardial involvement in asymptomatic patients with MD.

In primary MD patients, cardiac involvement is the second most common cause of death.²⁾ Atrioventricular block and ventricular tachyarrhythmia are considered to be the main cause of sudden death in patients with MD.⁷⁾ Several studies have recommended that Holter monitoring should be performed on a regular basis.^{8,9)} Recent pacing guidelines have recognized that asymptomatic conduction abnormalities in MD may warrant special consideration for pacing.¹⁰⁾ In the present case, the patient showed non-specific findings on initial Holter

monitoring, but treadmill testing showed a significant arrhythmia and an inappropriate heart rate. Progressive conduction abnormalities with aggravated cardiomyopathy were observed on subsequent follow-up examinations.

We therefore suggest that comprehensive evaluation with treadmill testing and an EKG may be beneficial for patients with primary MD, even when asymptomatic, to identify non-ischemic cardiomyopathy in an effort to determine the appropriate time for pacemaker insertion and prevention of life-threatening complications.

REFERENCES

- 1) Ashizawa T, Epstein HF. Ethnic distribution of myotonic dystrophy gene. *Lancet* 1991;338:642-3.
- 2) Mathieu J, Allard P, Potvin L, Prevost C, Begin P. A 10 year study of mortality in a cohort of patients with myotonic dystrophy. *Neurology* 1999;52:1658-62.
- 3) Finsterer J, Stollberger C, Blazek G, Kunafer M, Prager E. Cardiac involvement over 10 years in myotonic and Becker muscular dystrophy and mitochondrial disorder. *Int J Cardiol* 2007;119:176-84.
- 4) Kang WK, Ku DH, Shin SH, Jeong YC, Jeon ES, Park JH. A case of myotonic dystrophy with prolonged atrial flutter. *Korean Circ J* 1989;19:770-5.
- 5) Bhakta D, Lowe MR, Groh WJ. Prevalence of structural cardiac abnormalities in patients with myotonic dystrophy type I. *Am Heart J* 2004;147:224-7.
- 6) Nguyen HH, Wolfe JT 3rd, Holmes DR Jr, Edwards WD. Pathology of the cardiac conduction system in myotonic dystrophy:

- a study of 12 cases. J Am Coll Cardiol* 1988;11:662-71.
- 7) Groh WJ, Groh MR, Saha C, et al. *Electrocardiographic abnormalities and sudden death in myotonic dystrophy type 1. N Engl J Med* 2008;358:2688-97.
- 8) Phillips MF, Harper PS. *Cardiac disease in myotonic dystrophy. Cardiovasc Res* 1997;33:13-22.
- 9) Sa MI, Cabral S, Costa PD, Coelho T, Freitas M, Gomes JL. *Ambulatory electrocardiographic monitoring in type 1 myotonic dystrophy. Rev Port Cardiol* 2007;26:745-53.
- 10) Gregoratos G, Abrams J, Epstein AE, et al. *ACC/AHA/NASPE 2002 guideline update for implantation of cardiac pacemakers and antiarrhythmia devices: summary article: a report of the American College of Cardiology/American Heart Association Task Force on Practice Guidelines (ACC/AHA/NASPE Committee to Update the 1998 Pacemaker Guidelines). Circulation* 2002;106:2145-61.