

# Anomalous Origin of the Left Circumflex Coronary Artery from the Right Sinus of Valsalva Identified by Imaging with Multidetector Computed Tomography

Young-Soo Lee, MD, Jin-Bae Lee, MD and Kee-Sik Kim, MD

Division of Cardiology, College of Medicine, Catholic University of Daegu, Daegu, Korea

## ABSTRACT

An anomalous origin for the coronary artery is a rare congenital condition with an incidence of about 0.17% based on autopsy cases. A 53-year-old man suffering from exertional angina for one month underwent coronary angiography. The left circumflex coronary artery (LCX) was found to originate from the right sinus of Valsalva. Multidetector computed tomography revealed that the LCX coursed posterior to the aorta and followed a normal course after it entered the left anterior atrioventricular groove. (*Korean Circulation J* 2006;36:823-825)

**KEY WORDS :** Coronary vessel anomalies ; Tomography, X-ray computed.

## Introduction

Coronary artery anomalies are found incidentally in 0.6% to 1.55% of patients who undergo coronary angiography;<sup>1,2)</sup> increasing use of diagnostic coronary angiography is uncovering even more such abnormalities. They may present with no symptoms, but occasionally cause: loss of consciousness, tachycardia, chest pain and sudden death. A coronary vessel anomaly of the right coronary artery (RCA) is the most common coronary artery anomaly, with an incidence for the left circumflex coronary artery (LCX) anomaly reported to be 0.3%.<sup>3)</sup>

We present a case of a 53-year-old male who had an anomalous origin of the LCX detected at coronary angiography; the course of the LCX was determined by multidetector computed tomography (MDCT).

## Case

A 53-year-old male presented with a one month history of chest pain with activity. The patient had no cardiovascular risk factors. On admission, the blood pressure, pulse rate, respiratory rate and body temperature were 100/60 mmHg, 54 beats per minute, 20 per minute

and 37.0°C, respectively. There were no abnormal heart or respiratory sounds. The cardiac enzymes, such as CK-MB and cardiac specific troponin I, were within normal limits. An electrocardiogram showed no ischemic changes. Chest radiography was also normal. A transthoracic echocardiography revealed normal left ventricular systolic function and no regional wall motion abnormality.

Diagnostic coronary angiography revealed minimal stenosis in the left anterior descending artery. However, the LCX could not be visualized during injection of the left coronary artery. There were significant lesions noted at the proximal and distal portion of the RCA. The ostium of the LCX was located at below the ostium of the RCA in the right sinus of Valsalva (Fig. 1A). There was no significant luminal narrowing in the LCX, and its peripheral distribution was normal (Fig. 1B). However, we could not precisely assess the course of the proximal portion of the LCX. At first, we successfully performed percutaneous coronary intervention at the proximal and distal portions of the RCA, which were considered the most significant lesions. Two days later, ECG-gated MDCT angiography was performed using a Sensation 16 scanner (Siemens, Forchheim, Germany). A bolus of contrast material (100 mL, Ultravist 370<sup>®</sup>, Schering, Berlin, Germany) was injected intravenously at a rate of 3.5 mL/sec, followed by 50 mL of saline at the same rate. Data were retrospectively reconstructed at the mid-diastolic phase. All images were transferred to a workstation (Syngo, Wizard; Siemens Medical solutions) for thin maximum intensity projection and volume rendering of the image. The MDCT revealed that the LCX

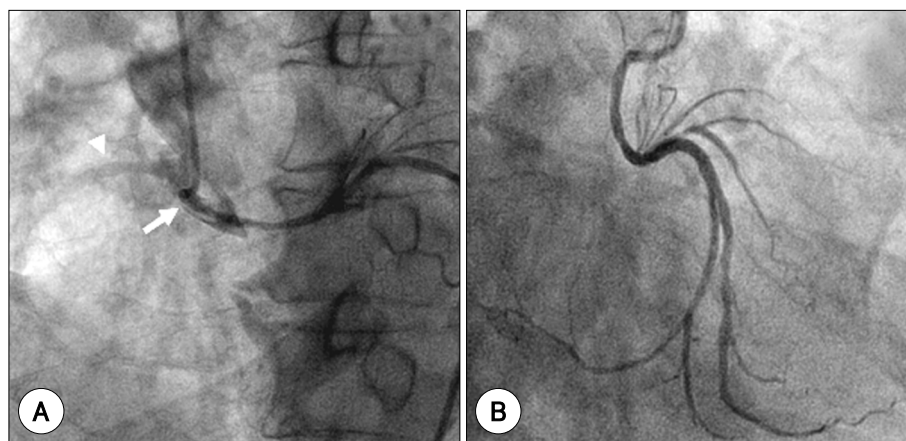
Received : October 17, 2006

Accepted : November 16, 2006

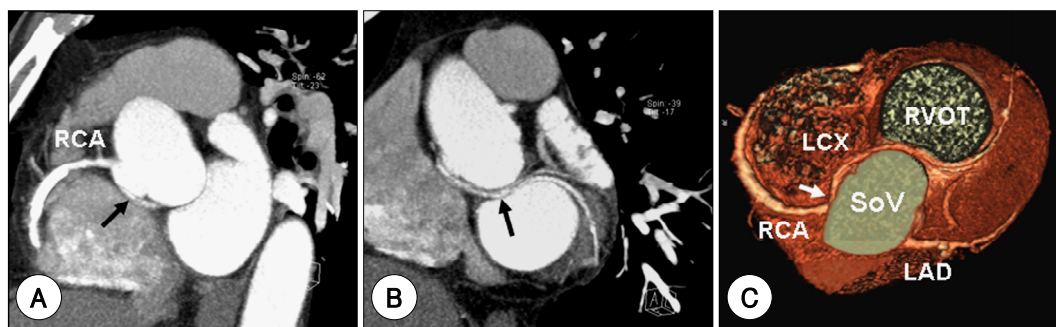
Correspondence : Jin-Bae Lee, MD, Division of Cardiology, College of Medicine, Catholic University of Daegu, 3056-6 Daemyung-4-dong, Nam-gu, Daegu 705-718, Korea

Tel: 82-53-650-4389, Fax: 82-53-621-3266

E-mail: jblee@cu.ac.kr



**Fig. 1.** A: coronary angiogram in the left anterior oblique projection shows the circumflex coronary artery (white arrow) originating in the right sinus of Valsalva and slight enhancement of the right coronary artery (arrow head). B: coronary angiogram in the right anterior oblique-caudal projection shows the circumflex coronary artery from originating from right sinus of Valsalva, which passes a retroaortic course to its normal distribution.



**Fig. 2.** Anomalous origin and course of the left circumflex coronary artery (LCX). A: short axis thin maximum intensity projection (MIP) of the right coronary artery (RCA) reveals that LCX (arrow) arises from the right sinus of Valsalva (SoV). B: sagittal oblique MIP of ascending aorta and C: volume-rendered image with view from cranial reveal that LCX (arrow) courses posterior to aorta and follows the normal course after it enters the left anterior atrioventricular groove. RVOT: right ventricular outflow tract, LAD: left anterior descending coronary artery.

arose from the right sinus of Valsalva separately from the RCA (Fig. 2A, C) and coursed posterior to the aorta and followed a normal course after it entered the left anterior atrioventricular groove (Fig. 2B, C). We provided the patient with anti-thrombotic medications and vasodilators, and he has been free of chest pain.

## Discussion

A coronary vessel anomaly of the RCA is the most commonly detected with an incidence for the LCX anomaly of 0.3%.<sup>3,4)</sup> The coronary vessel anomalies of the LCX originate from the left sinus of Valsalva (55.5%), the RCA (36.9%) and right sinus of Valsalva (25.9%).<sup>5)</sup> Although the LCX anomaly is classified as benign and asymptomatic, it can cause myocardial ischemia, and in a few cases sudden death, myocardial infarction, and angina pectoris in the absence of atherosclerotic lesions have been reported. These manifestations might be due to repeated compression of the anomalous artery by a dilated aortic root or to unusual angling as a result of the retroaortic course of the LCX, which can compress the coronary ostium and restrict blood flow.<sup>6)</sup> In our

case, there was a significant lesion identified at the proximal and distal portion of the RCA, but not at the LCX. Therefore, the patient underwent a percutaneous coronary intervention at the RCA, without the spasm test.

Identification of anomalous coronary arteries is frequently difficult with conventional coronary angiography because of the absence of three-dimensional information on the course of the coronary arteries in relationship to the great vessels. MDCT can detect the anomalous origin and course of a coronary artery in relation to the great vessels.<sup>7)</sup> In our case, we could identify the different ostia of the LCX and RCA, the retroaortic course of the anomalous LCX and its relationship to the great vessels by MDCT. MDCT, which allows for three dimensional visualization of the coronary arteries and high spatial resolution, may be an even more useful diagnostic modality for the detection of anomalies, particularly in patients where the coronary artery anatomy appears uncertain on conventional coronary angiography.

## REFERENCES

- 1) Yamanaka O, Hobbs RE. Coronary artery anomalies in 126,595 patients undergoing coronary arteriography. *Cathet Cardiovasc*

*Diagn* 1990;21:28-40.

- 2) Kimbiris D, Iskandrian AS, Segal BL, Bemis CE. *Anomalous aortic origin of coronary arteries. Circulation* 1978;58:606-15.
- 3) Sharbaugh AH, White RS. *Single coronary artery: analysis of the anatomic variation, clinical importance and report of five cases. JAMA* 1974;230:243-6.
- 4) Kim JS, Lee JM, Yoon HJ, et al. *A case of coronary vessel anomaly of the left circumflex artery originating from the right coronary artery with variant angina. Korean Circ J* 2004;34:711-4.
- 5) Mavi A, Sercelik A, Ayalp R, Pestemalci T, Batyraliev T, Gumusburun E. *Variants origin of left circumflex coronary artery with angiograph. Saudi Med J* 2002;23:1390-3.
- 6) Roberts WC. *Major anomalies of coronary arterial origin seen in adulthood. Am Heart J* 1986;111:941-63.
- 7) Saito Y, Inoue F, Matsumoto N, et al. *Detection of anomalous origins of the coronary artery by means of multislice computed tomography. Circ J* 2005;69:320-4.