

## Successful Treatment of Prosthetic Tricuspid Valve Thrombosis with Repeated Urokinase Therapy

Jeong Hoon Yang, MD<sup>1</sup>, Sung Hea Kim, MD<sup>1</sup>, Soo Jin Cho, MD<sup>1</sup>, Jong Kyu Kim, MD<sup>1</sup>, Sang-Chol Lee, MD<sup>1</sup>, Kay-Hyun Park, MD<sup>2</sup> and Seung Woo Park, MD<sup>1</sup>

<sup>1</sup>Departments of Medicine, <sup>2</sup>Thoracic and Cardiovascular Surgery, Samsung Medical Center, Sungkyunkwan University School of Medicine, Seoul, Korea

### ABSTRACT

Prosthetic valve thrombosis (PVT) can be a life-threatening complication that requires immediate treatment. This is a case report on repeated thrombolytic therapy for thrombosis of a prosthetic tricuspid valve. After repeated urokinase therapy, mechanical clicks were audible and the hemodynamics of the patient rapidly improved. Echocardiography showed the disappearance of thrombi and a normalized pressure gradient. Cine-fluoroscopy showed a well-functioning prosthetic valve. (Korean Circulation J 2006;36:400-403)

**KEY WORDS :** Thrombosis ; Thrombolytic therapy.

### Introduction

Prosthetic valve thrombosis (PVT) is a rare, but serious complication resulting from the use of mechanical valves.<sup>1-4)</sup> Thrombotic malfunction of a mechanical heart valve in the tricuspid position is a well-known and relatively benign clinical entity, and this can occur despite adequate anticoagulation.<sup>5)</sup> Thrombolytic therapy to relieve thrombotic prosthetic valve obstruction has been accepted for treating the right-sided valves, although its role for treating the left-sided valves and hemodynamically unstable patients needs to be clarified.<sup>1-7)</sup> We report here on a case of subacute thrombosis of a St. Jude mechanical tricuspid valve prosthesis in which the two-dimensional echocardiography and cine-fluoroscopy demonstrated severe tricuspid inflow obstruction. This malady was completely resolved after repeated thrombolytic therapy without any complication.

### Case

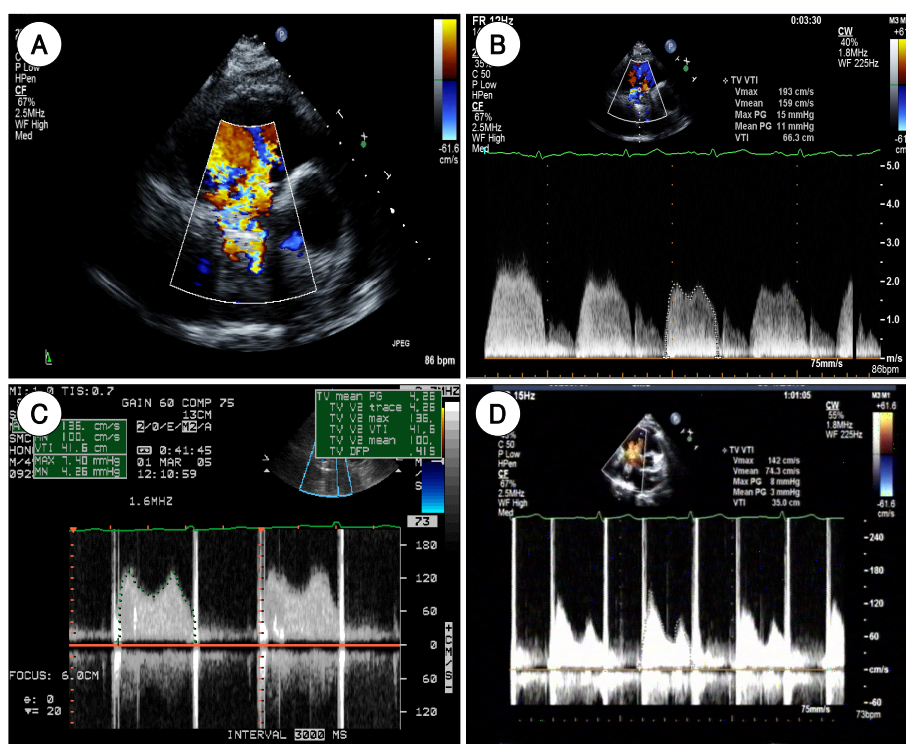
A 49-year-old man was admitted to the hospital with facial and lower extremity edema that began 6 days before his hospital admission. He had received a mechanical

tricuspid valve replacement (St. Jude, 33 mm) for Ebstein's anomaly and he had undergone coronary artery bypass graft surgery for his three-vessel coronary artery disease 80 days prior to this admission. Anticoagulation with warfarin was started after the surgery, and this was continued after discharge from the hospital. On the day of admission, the INR was 2.16. On physical examination, the blood pressure was 130/70 mmHg and the heart rate was 90/min. The lungs were clear and cardiac examination revealed no metallic click sound, which was usually audible in a patient with prosthetic valves. The liver edge was palpable 2 cm below the right costal margin and there was grade 1+ pitting edema of the lower extremities. Echocardiographic examination revealed restricted motion of the tricuspid prosthetic valve leaflets with an increased transvalvular mean pressure gradient of 11 mmHg (Fig. 1). Cine-fluoroscopic examination showed fixation of both leaflets of the prosthetic valve (Fig. 2). A bolus injection of 500,000 IU of urokinase was given; this was followed by continuous dripping of 2,500,000 IU for 12 hours. The patient was then treated with intravenous heparin that was adjusted to a partial thromboplastin time of 1.5 to 2 times of the control value. An echocardiographic and cine-fluoroscopic follow-up examination was performed after completion of the infusion. The mean pressure gradient between the right ventricle and atrium was decreased to 4.3 mmHg, but only one of the leaflets showed normal movement on the cine-fluoroscopic and echocardiographic examination. Because of this, the thrombolytic agent was given again 24 hours after the first treatment with the same

Received : September 26, 2005

Accepted : October 26, 2005

Correspondence : Seung Woo Park, MD, Department of Medicine, Samsung Medical Center, Sungkyunkwan University School of Medicine, 50 Ilwon-dong, Gangnam-gu, Seoul 135-710, Korea  
Tel: 82-2-3410-3419, Fax: 82-2-3410-3849  
E-mail: swpark@smc.samsung.co.kr



**Fig. 1.** The transthoracic echocardiographic feature of prosthetic tricuspid valve thrombosis: the initial Doppler echocardiographic examination shows a mosaic pattern of the color Doppler signal at the tricuspid inflow (A), and continuous Doppler examination shows the increased tricuspid inflow velocity and the elevated mean pressure gradient of the prosthetic tricuspid valve (B). This suggests tricuspid stenosis. C: the image shows the decreased mean pressure gradient of the prosthetic tricuspid valve after the first course of thrombolysis, but it is still higher than normal. D: there is a normalized pressure gradient of prosthetic tricuspid valve after repeated thrombolysis.

protocol as the initial therapy. Follow-up echocardiographic examination showed a normal Doppler pattern of the tricuspid inflow, and the mean pressure gradient of the tricuspid inflow was 3 mmHg (Fig. 1). Cine-fluoroscopic examination showed that both valve leaflets were moving freely after the repeated thrombolysis (Fig. 2). The patient was given anticoagulation therapy with warfarin with a target INR of 3.0 to 4.0, and the patient was discharged from the hospital.

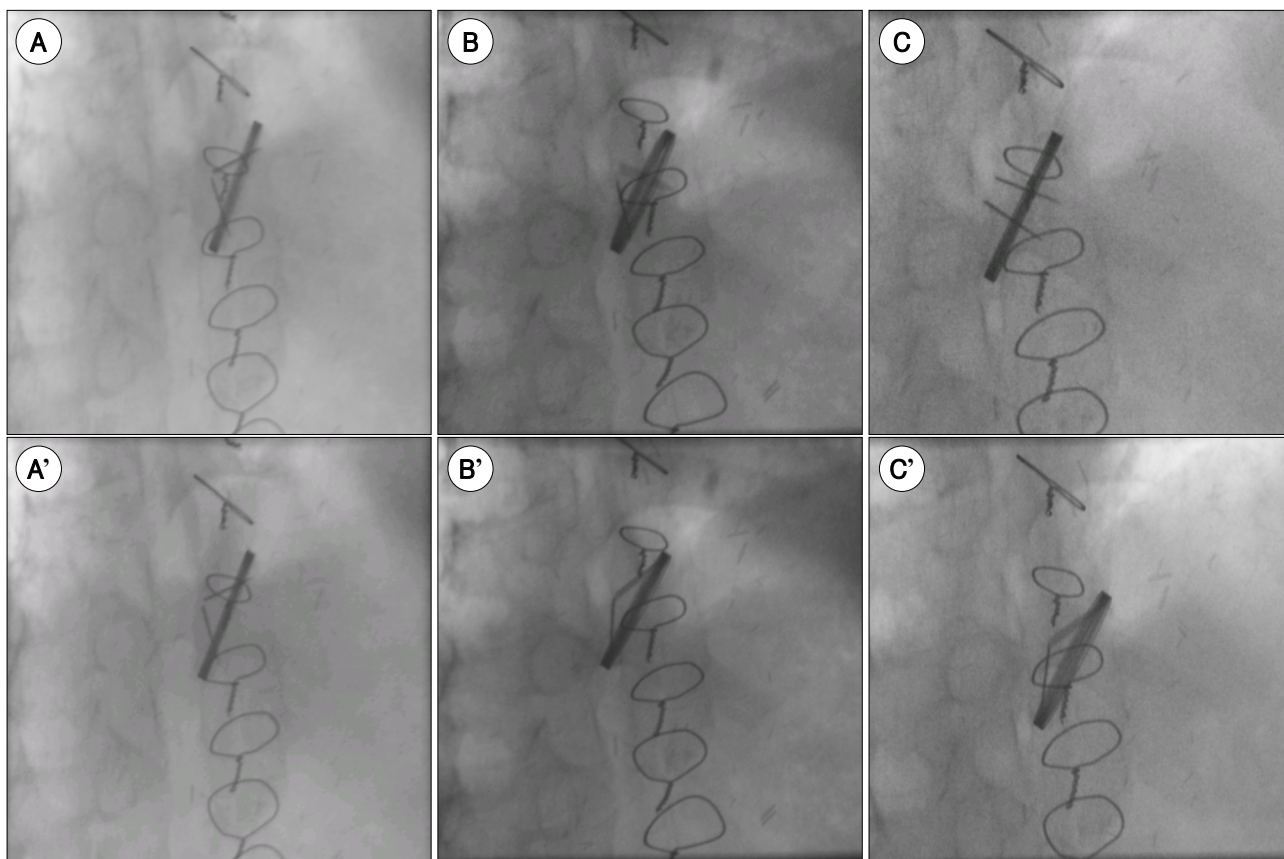
## Discussion

Since the first prosthetic valve replacement in humans was done in 1960,<sup>3)</sup> prosthetic valve thrombosis remains an important cause of morbidity and mortality.<sup>2)</sup> Unfortunately, despite the advances in valve design and the performance of optimal anticoagulation, the reported incidence of thrombotic obstruction ranges from 4% to 8.6% within 5 years of implantation and this can be as high as 13% within 1 year for the tricuspid prostheses.<sup>3,4)</sup> The higher incidence of thrombosis in the tricuspid position compared to the other valves may be because of the relatively low-pressure environment.<sup>2,7,8)</sup>

Typically, PVT results in acute hemodynamic deterioration that requires immediate medical attention, but occasionally it may have a more insidious onset and a longer duration of symptoms.<sup>3,8)</sup> The physical exami-

nation may reveal a decreased intensity of one or both metallic clicks or the presence of a new murmur, edema, ascites and hepatomegaly.<sup>1,3,7,8)</sup> The diagnosis of valve thrombosis is usually confirmed by performing cine-fluoroscopy and echocardiography with a Doppler examination.<sup>1-3,9)</sup> A thrombus is best visualized by transesophageal echocardiography, but transthoracic echocardiography and cine-fluoroscopy, which are less sensitive for detecting thrombi but they are more widely accessible and more easily applicable, can demonstrate a restriction or the absence of movement of a leaflet of the prosthetic valve; these tools can be very useful for the assessment of the efficacy of the treatment during the treatment period and at follow-up.<sup>10,15)</sup>

Surgery was the traditional treatment for obstructive PVT. However, there is high operative mortality that is largely related to the clinical functional class.<sup>2-4,11)</sup> The surgical mortality ranges from 0 to 60% depending on the functional class at the time of presentation and the urgency of the operation.<sup>3)</sup> In recent years, with the advent of thrombolytic therapy, an alternative nonsurgical treatment for PVT has emerged.<sup>4)</sup> In general, thrombolytic therapy cannot be generally recommended for thrombosis of the left-sided heart valves unless the patient is not a surgical candidate because of the risk of critical embolic complications and major bleeding.<sup>2,5)</sup> However, the right-sided valves seem to be safer to treat



**Fig. 2.** Cine-fluoroscopic features of the prosthetic tricuspid valve thrombosis. A: the image shows the fixed motion of the prosthetic tricuspid valve leaflets before thrombolysis. B: the image shows that only one valve leaflet moves after the first thrombolysis. C: the image shows that both valve leaflets move freely after the repeated thrombolysis. Cine-fluoroscopic sequences in diastole (A, B, C) and systole (A', B', C') are shown, respectively.

with thrombolytic therapy because the major complications are merely fever or minor pulmonary embolism.<sup>1)3)5)12)</sup> Streptokinase, rt-PA and urokinase have been the most commonly used thrombolytic agents. There was no statistically significant difference between the agents for their success rates, although there are some differences in the dosage and the duration of the infusion for each of the thrombolytic agents.<sup>1-3)11)13)14)</sup>

The recurrent thrombosis rate after initial thrombolysis is approximately 11%. Because the success rate of repeated thrombolysis is equal to that of the initial treatment, another attempt at thrombolysis is worthwhile in those patients suffering with rethrombosis.<sup>3)</sup> Therefore, repeated thrombolytic therapy can be considered for the case of a partial PVT after the initial thrombolytic therapy, as was done in the current case, and especially for right sided PVT.

## REFERENCES

- 1) Han KR, Song JM, Choi SJ, et al. Clinical characteristics and treatment of bileaflet prosthetic valve thrombosis and stenosis in the tricuspid position. *Korean J Med* 1994;46:505-13.
- 2) Tischler MD, Lee RT, Kirshenbaum JM. Successful treatment of prosthetic tricuspid valve thrombosis with short-course recombinant tissue-type plasminogen activator. *Am Heart J* 1990;120:975-7.
- 3) Tsiouris N, Ahmad M. Prosthetic valve thrombosis and thrombolysis: a case report and review of the literature. *Am J Med Sci* 2001;322:229-32.
- 4) Dwivedi N, Aroney CN, Slaughter R. Thrombosis of a mechanical tricuspid valve prosthesis and of the left subclavian vein: successful therapy with thrombolysis. *Cathet Cardiovasc Diagn* 1998;43:84-6.
- 5) Cambier P, Mombaerts P, de Geest H, Collen D, van de Werf F. Treatment of prosthetic tricuspid valve thrombosis with recombinant tissue-type plasminogen activator. *Eur Heart J* 1987;8:906-9.
- 6) Kim YM, Park YW, Han JY, et al. Thrombolytic treatment of prosthetic valve thrombosis. *J Korean Soc Echocardiogr* 2001;9:38-44.
- 7) Joyce LD, Boucek M, McGough EC. Urokinase therapy for thrombosis of tricuspid prosthetic valve. *J Thorac Cardiovasc Surg* 1983;85:935-7.
- 8) Thorburn CW, Morgan JJ, Shanahan MX, Chang VP. Long-term results of tricuspid valve replacement and the problem of prosthetic valve thrombosis. *Am J Cardiol* 1983;51:1128-32.
- 9) Chung N, Yoon JH, Jang YS, et al. Prosthetic mitral valve thrombosis: diagnosis and thrombolytic therapy with urokinase. *Korean Circ J* 1991;21:1159-64.
- 10) Roth A, Diamant S, Sherez J. Thrombolytic treatment for thrombosis of a prosthetic valve at the tricuspid position in a young patient with a congenital heart disease. *Clin Cardiol* 1999;22:747-8.

- 11) Fyfe DA, Taylor AB, Kline Ch, Sade RM, Gillette PC. *Doppler echocardiographic evaluation of streptokinase lysis of thrombosed right-sided St. Jude Medical valves in patients with congenital heart defects. Am Heart J* 1991;121:1156-60.
- 12) Kurzrok S, Singh AK, Most AS, Williams DO. *Thrombolytic therapy for prosthetic cardiac valve thrombosis. J Am Coll Cardiol* 1987;9:592-8.
- 13) Kang SK, Kim SW, Won TH, et al. *Thrombolytic therapy for thrombosis of prosthetic mitral valve: a case report. Korean J Thorac Cardiovasc Surg* 2002;35:826-30.
- 14) Lengyel M, Fluster V, Keltai M, et al. *Guidelines for management of left-sided prosthetic valve thrombosis: a role for thrombolytic therapy. J Am Coll Cardiol* 1997;30:1521-6.
- 15) Kim JK, Hwang HK. *Results of eight-year follow-up of omni-science cardiac prosthetic valve. Korean Circ J* 2002;32:588-95.