

A Case of Pacemaker Implantation after Balloon Venoplasty on Innominate Vein Stenosis

Jin Seok Kim, M.D., Hui-Nam Pak, M.D., Hong Euy Lim, M.D. and Young-Hoon Kim, M.D.

Korea University Cardiovascular Center, Seoul, Korea

ABSTRACT

A pacemaker-induced venous obstruction is relatively common, but is rare in cases where chronic venous occlusion has developed and progressed after the removal of permanent pacemaker leads. We report a case of permanent pacemaker implantation following percutaneous balloon venoplasty in a patient with innominate vein stenosis. The patient had a history of permanent pacemaker implantation, using a right subclavian approach, with lead extraction due to infective endocarditis 6 years earlier. Although the epicardial leads were re-implanted, once more the ventricular lead broke. When we tried to implant a new pacemaker, using a left subclavian endovascular approach, extensive venous stenoses of the innominate, right internal jugular and subclavian veins were found. As it was impossible to advance the standard pacemaker lead; therefore, percutaneous balloon venoplasty of the innominate vein was performed, and a DDD-R pacemaker successfully implanted. (*Korean Circulation J* 2005;35:558-561)

KEY WORDS : Pacemaker, artificial ; Venous thrombosis ; Balloon angioplasty.

Introduction

After the implantation of a permanent pacemaker, sometimes there is a need to change or remove a pacemaker lead due to physical damage, malfunction or infection. In such cases, difficulty may be encountered when changing or extracting the pacing lead if pacemaker-induced venous stenosis or obstruction exists. This usually occurs several years after implantation,¹⁾ but there have also been reports of delayed presentation, even after extraction of the leads.²⁾ There have been several reports about balloon venoplasty or stent deployment during the course of a lead replacement procedure when a venous stricture has been discovered.^{3,4)} However, it is rare for venoplasty to be performed during the placement of a pacing lead in patients where the leads have been extracted a long time ago and the venous stenosis or obstruction has chronically progressed. We report a patient with fracture of an epicardial pacing lead, with a central vein occlusion, caused by a previous permanent pacemaker that had been removed 6 years earlier due to lead infection. During the insertion of a pacing lead through the left subclavian vein, an innominate vein stenosis was encountered; there-

fore, balloon venoplasty was performed on the innominate vein and a permanent pacemaker successfully implanted.

Case

A 45-year-old man was admitted to our institution with general weakness and dizziness that developed immediately after playing golf. Ten years earlier, he had had a previous dual chamber DDD pacemaker via the right subclavian vein due to complete atrioventricular nodal block. Initially, the implantation of a permanent pacemaker was performed through a right subclavian approach as he was a left-handed. Four years later, he was admitted due to fever and dyspnea, and diagnosed with infective endocarditis. However, the infection was not controlled and the mitral insufficiency became worse, despite appropriate antimicrobial treatment. Therefore, the existing pacemaker leads had been removed through the right subclavian vein and mitral valve replacement performed, followed by implantation of a new epicardial dual chamber pacemaker, where the leads had been placed at the right atrium and antero-lateral wall of the right ventricle, respectively. The generator was implanted in the right upper abdominal wall above the muscular fascia. On admission, an electrocardiogram showed ventricular sensing and pacing failure (Fig. 1A), and an abdomen radiograph revealed a fracture of the ventricular lead of the epicardial pacemaker (Fig. 1B). We

Received : February 24, 2005

Accepted : April 20, 2005

Correspondence : Hui-Nam Pak, M.D., Korea University Medical Center, 126-1 Anam-5-ga, Seungbuk-gu, Seoul 136-702, Korea

Tel: 82-2-920-5445, Fax: 82-2-927-1478

E-mail: hnpak@korea.ac.kr

planned to implant a permanent pacemaker using an endovascular approach through the left subclavian vein, where no pacing leads had previously been placed. After puncturing the left subclavian vein, we tried to advance a 0.035" guidewire via 9 Fr sheath. However, we could

not advance the guidewire at the level of the innominate vein. A venogram of the innominate vein revealed a severe stenosis at the junction of the innominate vein and superior vena cava (Fig. 2A). A subsequent venogram of the right subclavian vein showed total occlusion

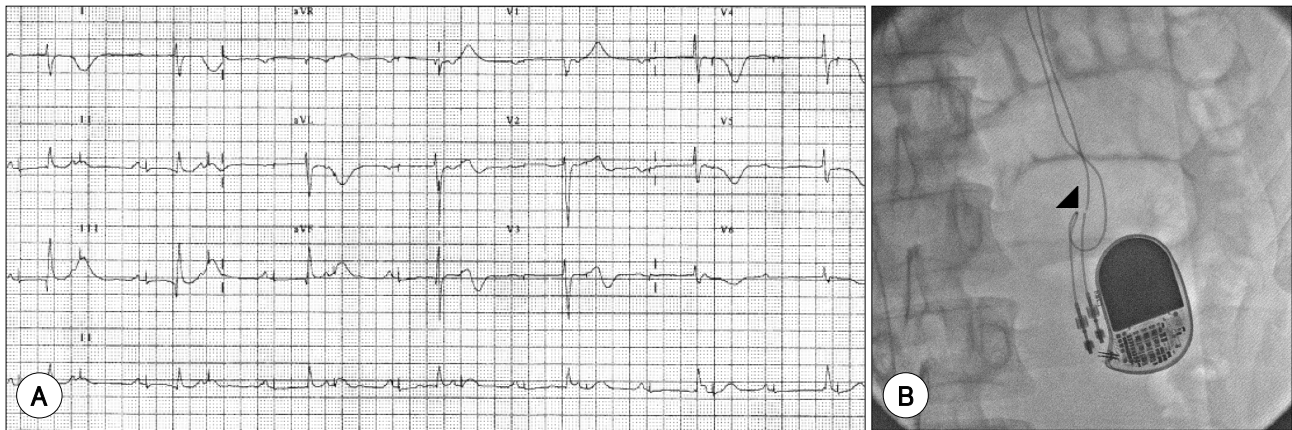


Fig. 1. ECG and abdomen radiography on admission. A: ECG shows sensing and pacing failure of the ventricular lead, accompanied by severe bradycardia. B: Ventricular lead fracture (black arrow head) of an epicardially implanted pacemaker is seen. ECG: electrocardiogram.

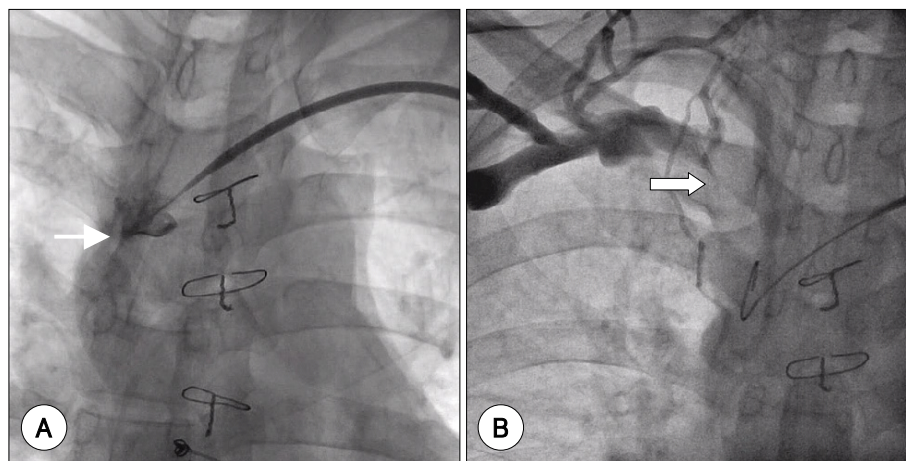


Fig. 2. Venograms of innominate and right subclavian vein. Significant focal stenoses (thin arrow) are seen at the junction of the SVC and innominate vein (A), with the total obstruction (thick arrow) of the proximal right subclavian vein at the junction with the right internal jugular vein (B). SVC: superior vena cava.

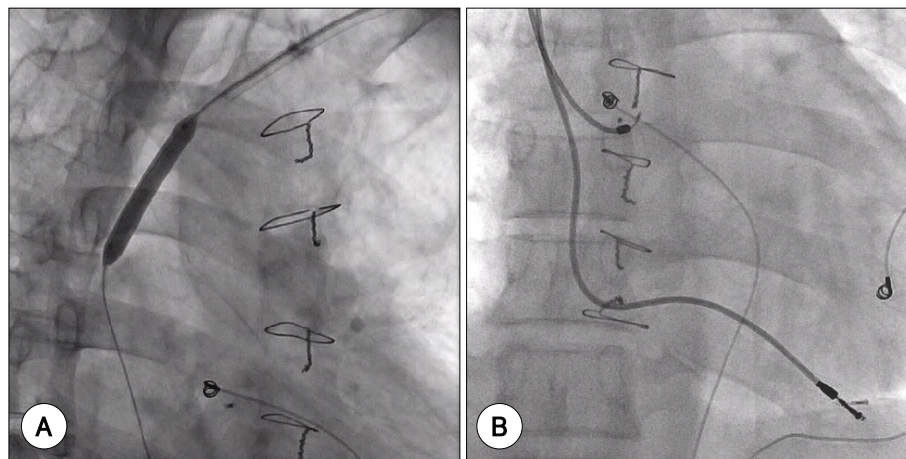


Fig. 3. Implantation of a dual chamber permanent pacemaker (B) after percutaneous transluminal balloon venoplasty of an innominate vein (A).

of the right subclavian vein at the junction of the superior vena cava and well developed collateral vessels (Fig. 2B). However, the patient never showed any evidence of superior vena cava syndrome. Therefore, we decided to perform percutaneous transluminal balloon venoplasty on the innominate vein via a left subclavian approach. A 0.014" guidewire (Floppy, ACS Inc) was advanced through a 9 Fr sheath across the stenotic site, followed by balloon venoplasty on the innominate vein (Fig. 3A) using a 4 × 20 mm balloon (6 atm, 30 seconds, Boston Scientific Inc). Without complication, this facilitated the safe passage of the new pacing leads. Finally, we implanted a dual chamber pacemaker (DDDR, Biotronics Inc), with the leads fixed to the apex of the right ventricle and the right atrial appendage, respectively (Fig. 3B). The measured sensitivities, thresholds and impedances of the A and V leads were within normal limits. The patient showed no symptoms, with a normal functioning pacemaker, during seven months of follow-up without any evidence of superior vena cava syndrome.

Discussion

A central venous occlusion may develop at any time after the implantation of transvenous permanent pacemaker, but usually occurs after several years.¹⁾ A pacemaker-induced venous obstruction is mainly caused by the pacemaker leads, which can result in thrombosis and stenosis. Most often a thrombosis occurs in the axillary, subclavian and innominate veins, or in the superior vena cava (SVC), and has been reported to be relatively common.^{5,6)} Significant venous thrombosis of the innominate or subclavian vein was been documented in up to 30-40% of patients, and with complete occlusion in up to 20% at 2 years after implantation. However, symptomatic venous thrombosis occurs in less than 5% of patients after pacemaker implantation.⁷⁾ Most patients with pacemaker related chronic obstruction of the central veins remain asymptomatic, and might be found during pacemaker lead revision.³⁾ In our case, we observed chronically well developed collateral vessels, which concealed the symptomatic central vein obstruction, after pacing lead extraction. An early obstruction after pacemaker implantation mainly usually results from thrombosis, in the absence of stenosis, but a delayed obstruction may be the result of fibrotic stenosis.⁸⁾ The most common area of lead related fibrotic stenosis is the junction between the superior vena cava and innominate vein. The pacemaker lead tension can irritate the endothelial side of venous wall, especially at the site of multiple leads intersection.⁹⁾ Local endothelial trauma and irritation due to the endothelial lead can lead to fibrosis and thrombosis, which may occur by puncturing the vein or merely by manipulating the guidewire.¹⁰⁾ Other supposed causes include severed leads left behind within the cir-

culatation, for whatever reason, and a history of recent or remote infection.⁹⁾

Balloon venoplasty^{4,9-11)} of the superior vena cava and endovascular stenting^{4,7)} have been reported for patients with SVC stenosis following permanent pacemaker implantation. Pace et al.¹⁰⁾ described the use of percutaneous transluminal balloon venoplasty to facilitate the extraction of permanent pacemaker leads, and their replacement with new leads through occluded vessels, which may be considered an adjunctive method. Tan et al.⁹⁾ reported that a patient with a SVC occlusion associated with a pacemaker lead can be effectively treated with balloon venoplasty with a good long-term clinical and angiographic outcome. In this case, an interesting finding was that the central venous occlusion had developed chronically, even though the permanent pacemaker leads had been removed six years earlier. The past infective endocarditis might contribute to the slow progression of venous stenosis or an occlusion.

In summary, we report a case of pacemaker lead placement after percutaneous transluminal balloon venoplasty in a critically stenotic innominate vein in a patient with past history of lead extraction and infective endocarditis. When pacemaker leads are extracted or replaced, the operator has to pay attention to the possibility of venous stenosis and the risk of venous complications. An interventional method, including balloon venoplasty or stenting, might be helpful in overcoming a central venous obstruction or stenosis with a complicated pacemaker implantation.

REFERENCES

- 1) Francis CM, Starkey IR, Errington ML, Gillespie IN. *Venous stenting as treatment for pacemaker-induced superior vena cava syndrome.* Am Heart J 1995;129:836-7.
- 2) Chia HM, Anderson D, Jackson G. *Pacemaker-induced superior vena cava obstruction: bypass using the intact azygous vein.* Pacing Clin Electrophysiol 1999;22:536-7.
- 3) Spittell PC, Vliestra RE, Hayes DL, Higano ST. *Venous obstruction due to permanent transvenous pacemaker electrodes: treatment with percutaneous transluminal balloon venoplasty.* Pacing Clin Electrophysiol 1990;13:271-4.
- 4) Teo N, Sabharwal T, Rowland E, Curry P, Adam A. *Treatment of superior vena cava obstruction secondary to pacemaker wires with balloon venoplasty and insertion of metallic stents.* Eur Heart J 2002;23:1465-70.
- 5) Spittell PC, Hayes DL. *Venous complication after insertion of transvenous pacemaker.* Mayo Clin Proc 1992;67:258-65.
- 6) Cho EJ, Youn HJ, Rho TH, et al. *Clinical characteristics of patient with permanent pacemaker associated with lead thrombi.* Korean Circ J 2003;33:294-301.
- 7) Lanciego C, Rodriguez M, Rodriguez A, Carbonell MA, Garcia LG. *Permanent pacemaker-induced superior vena cava syndrome: successful treatment by endovascular stent.* Cardiovasc Intervent Radiol 2003;26:576-9.
- 8) Lindsay HS, Chennells PM, Perrins EJ. *Successful treatment by balloon venoplasty and stent insertion of obstruction of the superior vena cava by an endocardial pacemaker lead.* Br Heart

J 1994;71:363-5.

- 9) Tan CW, Vijitbenjaronk P, Khuri B. *Superior vena cava syndrome due to permanent transvenous pacemaker electrodes: successful treatment with combined thrombolysis and angioplasty: a case report. Angiology* 2000;51:963-9.
- 10) Pace JN, Maquilan M, Hessen SE, khoury PA, Wilson A, Kutalek SP. *Extraction and replacement of permanent pacemaker leads through occluded vessels: use of extraction sheaths as conduits-balloon venoplasty as an adjunct. J Interv Card Electrophysiol* 1997;1:271-9.
- 11) Kastner RJ, Fisher WG, Blacky AR, Bacon ME. *Pacemaker-induced superior vena cava syndrome with successful treatment by balloon venoplasty. Am J Cardiol* 1996;77:789-90.