

Demonstration of Pathologic Coronary Flow Dynamics using Transthoracic Doppler Echocardiography: Its Potential Role in Clinical Decision-Making

Ho-Joong Youn, M.D.

Division of Cardiology, Department of Internal Medicine, College of Medicine, The Catholic University of Korea, Seoul, Korea

ABSTRACT

With advancements in high frequency transducers, transesophageal (TEE) and transthoracic Doppler echocardiography (TTE) are emerging as promising methods for the evaluation of coronary arteries. In addition to visualizing images for the detection of stenosis of the proximal and distal coronary arteries, as well as various kinds of coronary artery anomalies, the functional assessment through measurement of the coronary flow reserve using TEE and TTE have become valuable and additive tools for coronary angiography that define only the epicardial coronary arteries. Further efforts to develop new techniques, including real time 3D echocardiography, in the anatomic and functional assessments of coronary artery disease should be undertaken. (*Korean Circulation J* 2005;35:269-281)

KEY WORDS : Echocardiography, transthoracic ; Coronary circulation.

Introduction

Coronary angiography is currently the standard method for assessing coronary artery disease. However, the visual estimation of the anatomic severity of coronary artery stenosis limits the information available on coronary flow dynamics, and fails to adequately predict its physiologic importance. Therefore, the significance of the estimations of the coronary artery flow and coronary flow reserve (CFR) have been emphasized.¹⁻⁴⁾

Direct invasive measurements using Doppler flow wires and catheters have provided a wealth of literature on the pathophysiology of coronary flow dynamics. In clinical practice, these techniques are rarely applied due to the time and expense required; therefore treatment is based on anatomic measures. Non-invasive tools, such as those described below, could change the standard on which the treatment of coronary disease is based.

With the development of digital imaging capabilities, the emergence of multiplane transducer, the cine loop review and left sided contrast agents, transesophageal Doppler echocardiography (TEE) has improved the

visualization of the proximal coronary artery and enhanced the detection of its abnormalities, including stenosis and anomalies.⁵⁾ In addition to visualizing the proximal coronary artery, functional assessment through the measurement of CFR using TEE has become a valuable and additive tool for coronary angiography that defines only the epicardial coronary arteries.⁶⁾

Recently, one emerging technique is now contributing to the evaluation of the pathophysiologic significance of coronary artery disease in humans. Direct echocardiographic assessment of coronary artery disease using transthoracic Doppler echocardiography (TTE) was first described 17 years ago by Fusegima,⁷⁾ but rapid progress in the field has only occurred over the past few years. TTE is now emerging as a promising method for evaluating coronary artery disease. After a period of training, the detection and measurement of the distal left anterior descending coronary artery (LAD) flow with TTE is feasible in more than 90 % of patients, and continuous efforts are being made to noninvasively measure the epicardial coronary artery flow⁸⁻³⁹⁾ and CFR.⁴⁰⁻⁶⁶⁾

Identification of penetrating intramyocardial coronary arteries (PICA),⁶⁷⁻⁷²⁾ tumor feeding vessels in metastatic intracardiac mass⁷³⁾ and the internal mammary artery (IMA) flow⁷⁴⁻⁸¹⁾ have been reported using TTE. Although a recent study has reported the visualization of the distal right coronary artery (RCA),⁸²⁾⁸³⁾ most lite-

Correspondence : Ho-Joong Youn, M.D., Division of Cardiology, Department of Internal Medicine, College of Medicine, The Catholic University of Korea, 62 Yeouido-dong, Yeongdeungpo-gu, Seoul 150-713, Korea
Tel: 82-2-3779-1325, Fax: 82-2-3779-1374
E-mail: younhj@catholic.ac.kr

ature to date has examined the flow in the mid and distal left LAD.

The aims of this review were to discuss the coronary flow physiology and pathophysiology, to outline the technical aspects of the coronary artery visualization and flow measurement and to critique the current literature in this field.

Flow Physiology in Normal and Stenotic Coronary Arteries

The autoregulation of the coronary flow maintains

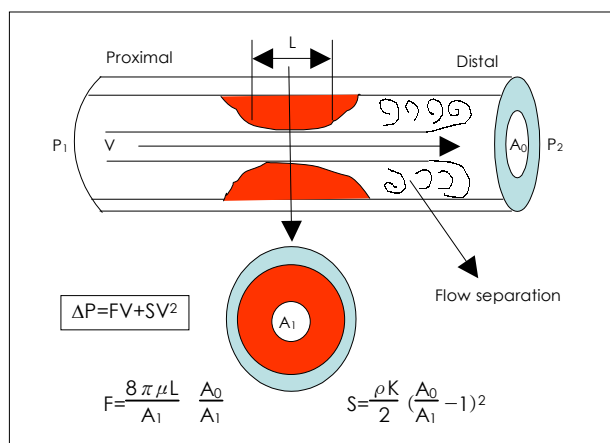


Fig. 1. Flow dynamics in coronary stenosis. F: coefficient of viscous friction loss, S: coefficient of separation loss, V: instantaneous velocity in the tube, L: length.

a constant level of myocardial perfusion in the face of changes in the driving pressure. When the mean aortic pressure drops below 60 to 70 mmHg, the coronary artery dilates to its full capacity, where auto regulatory mechanisms cease to be effective. At this point, myocardial perfusion becomes pressure dependent. Under normal physiological conditions, 95% of the total coronary resistance is determined by the small penetrating arteries (so called "resistance vessels" [50-500 m]) and only 5% by the epicardial coronary arteries.¹⁻⁴⁾

With normal coronary circulation, the basal coronary flow increases four- to five-fold with stimuli, such as intense exercise. The difference between the basal coronary flow and peak flow under maximal vasodilation represents CFR. CFR is usually expressed as the ratio of the coronary flow under maximal vasodilation to that under resting conditions. The basal coronary flow pattern is influenced by the presence of cardiac disease. For example, patients with long-standing hypertension, with or without left ventricular hypertrophy, have higher baseline coronary flow velocities. Baseline coronary flow velocity is an important determinant of CFR. Patients with a higher basal coronary flow velocity may have a diminished CFR.

Conversely, detailed assessment of the flow dynamics in coronary artery stenosis is essential in the understanding the pathophysiology of obstructive coronary disease. In the presence of moderate to severe coronary stenosis, a significant pressure-loss develops

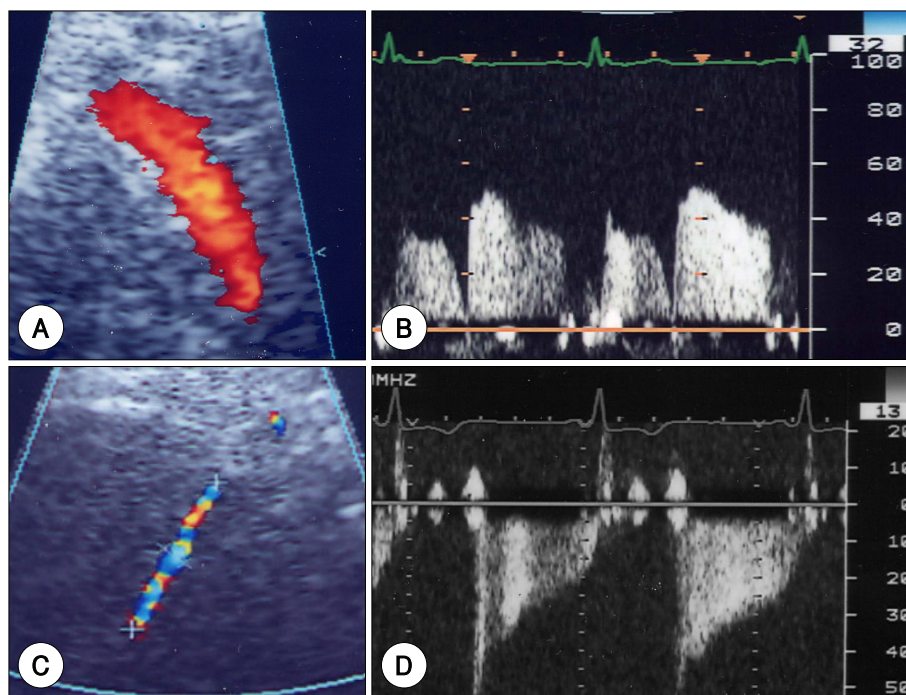


Fig. 2. Demonstration of color and pulsed doppler signals of the coronary artery flow using TTE. A: distal LAD flow showing the tubular and forward flow with homogenous red color. B: typical biphasic pattern showing dominant diastolic flow and smaller systolic components. C: color flow signal of PICA. D: pulsed doppler signal of PICA. LAD: left anterior descending coronary artery, PICA: penetrating intramyocardial coronary arteries.

across the stenosis, which causes reductions in the coronary flow reserve and effective coronary flow to the myocardium. The relationship between the flow velocity in the artery and the pressure loss due to arterial stenosis has been well documented.⁸⁴⁻⁸⁶⁾ In addition to the relative percentage stenosis, geometric features, such as the lesion length and shape, influence the pressure loss across a lesion (Fig. 1).⁸⁴⁾⁸⁵⁾

The CFR is influenced not only by the extent of stenosis, but also by physiological variables, such as myocardial hypertrophy, heart rate and preloading state, etc.⁸⁷⁾ Blood pressure does not appear to affect the magnitude of CFR as long as the pressures stay within the autoregulatory range. Even in coronary arteries with intermediate stenosis of 40 to 60%, the increases in myocardial hypertrophy, heart rate or preload decrease the CFR and produce myocardial ischemia.⁸⁸⁾ In addition to stenosis of the epicardial coronary artery, patients with left ventricular hypertrophy, secondary to long-standing hypertension,⁸⁹⁻⁹²⁾ microvascular disease,⁹³⁾⁹⁴⁾ aortic stenosis⁹⁵⁾ or hypertrophic subaortic stenosis,⁹⁶⁾ suffer from angina pectoris, even though they have normal coronary arteries. The mechanism responsible for the development of angina pectoris in patients with normal coronary arteries remains to be identified.

Measurements of the absolute coronary flow and CFR are very important for clinical decision making in coronary arteries with diffusely decreased coronary flow compared to the measurement of the relative CFR using T1-201 SPECT.⁹⁷⁾ In other words, measuring the absolute CFR can better assess the functional impairment of a coronary vessel. Measurements of the CFR have gained wide acceptance as an additional diagnostic approach to the decision making process for diagnostic cardiac catheterization and coronary intervention.

Technical Aspects of Image Acquisition

Left anterior descending artery(LAD)

The distal LAD is visualized primarily in the long-axis cross section, and the ultrasound beam is then inclined laterally (Fig. 2A). The proximal LAD is visualized in the modified parasternal short-axis-view, with the cross-sectional image of the aortic valve and septal branch of LAD also visualized in the parasternal short axis view at the mid-papillary muscle level. In color Doppler flow mapping of the distal LAD, the velocity range is set at 10-20 cm/sec. The color gain is adjusted to provide the optimal range. The acoustic window is around the midclavicular line of the fourth and fifth intercostal space in the left lateral decubitus position. The coronary blood flow is explored under the guidance of color Doppler flow mapping, but does not lie in the same position throughout the entire

cardiac cycle due to the translational motion. The position of the coronary blood flow is more stable in diastole. The probe angle and sample volumes are adjusted in order to orient the Doppler signal parallel to the coronary flow. In normal coronary arteries, the color Doppler signals of the distal LAD show diastolic dominant flow, with a smaller systolic component. Such flow patterns are very similar to that of the proximal LAD flow using transesophageal Doppler echocardiography⁵⁾ and the flow pattern using Doppler guide wire or Doppler catheter (Fig. 2B).⁹⁸⁾ Extravascular compression during systole is likely to be responsible for the smaller systolic component.⁹⁹⁾

According to our study,³⁷⁾³⁸⁾⁶²⁾ the average peak diastolic velocity of the distal LAD was 21.2 ± 7.9 cm/sec, and the average percentage of diastolic duration of coronary artery flow was $58.5 \pm 6.4\%$ per RR interval at resting within the physiological heart rate in healthy subjects with normal coronary angiogram and normal left ventricular function.

Right coronary artery(RCA)

For imaging the peripheral RCA flow, a lower frequency transducer is required due to the distance between the transducer and basal inferior cardiac wall. The posterior descending branch of the distal RCA may be visualized in the 2-chamber view adjacent to the ostium of the coronary sinus. The patient should be positioned in the left lateral decubitus position. The ultrasound beam is then inclined laterally, or rotated, to visualize the coronary blood flow close to the epicardial layer of the proximal portion or midportion of the posterior interventricular sulcus under color flow mapping guidance. In a recent paper, the coronary flow velocities were measured with a pulsed wave Doppler using minimum angle correction (from 0 to 15 degrees).⁸²⁾⁸³⁾

Penetrating intramyocardial coronary arteries(PICA)

In the supine or left lateral decubitus position, with a broad-band (2.5 to 5.0 MHz) transducer placed at the apical impulse, a standard apical 2- or 4-chamber 2-dimensional image is obtained. The imaging depth is decreased to between 3 and 5 cm. For color flow examination, a preset coronary program, with a very low Nyquist limit (12 to 20 cm), and either a single (red) or a two color map, is used. The probe should be positioned and the color gain optimized to maximize the flow. Linear intramyocardial color Doppler signals may be visualized perpendicular to the epicardial surface in the myocardium just beneath the apical impulse (Fig. 2C).⁶⁹⁾ Once the color flow signal had been optimized, the transducer position was adjusted to minimize the angle between the Doppler beam and the long axis of the flow signal and to ensure that the pulsed Doppler

sample volume (1.5 mm wide) was located within the linear color Doppler signal for as much of the cardiac cycle as possible. The pulsed Doppler signal of the intra-myocardial coronary artery flow was identified as a characteristic diastolic predominant flow pattern (Fig. 2D).

Demonstration of Pathologic Flow Dynamics

Localized aliasing

In recent studies,²⁴⁾²⁹⁾³³⁻³⁵⁾ the detection of localized aliasing using color flow mapping was helpful in searching for the stenotic site. The increase in the coronary blood flow velocity at the site of coronary stenosis correlated closely with the degree of stenosis, as measured by quantitative coronary angiography. In previous studies, the LAD flow was measured from the distal or middle part of the LAD using modified long-axis apical projection. The capability of TTE allows for flow measurement in the proximal LAD.³³⁾³⁴⁾ Detection of localized color aliasing and measurement of the prestenotic to stenotic mean diastolic velocity ratio in the LAD using TTE are both useful in the noninvasive diagnosis of restenosis after PTCA or stent implantation for LAD lesions (Fig. 3A, B).³³⁾

Rapid diastolic deceleration slope with systolic flow reversal

Blood flow to previously ischemic myocardium is sometimes profoundly reduced, which is known as the 'no reflow' or 'low reflow' phenomenon. Kawamoto et al.¹⁰⁰⁾ measured the diastolic deceleration time with

a Doppler guide wire shortly after coronary intervention in patients with acute myocardial infarction, and found a short diastolic deceleration time was associated with a worse wall motion recovery in the infarct zone. Shintani et al.³⁰⁾ reported that the diastolic deceleration slope of diastolic coronary flow velocity using TTE was steeper in patients with substantial no reflow phenomenon than in those without, and patients with a shorter deceleration half time (DHT) of the diastolic coronary flow velocity had a poorer functional outcome when associated with anterior myocardial infarction. A shorter DHT implies a steeper first deceleration slope of the diastolic flow velocity wave form (Fig. 3C). A reduced myocardial blood pool may account for this observation. During diastole in normal subjects, the coronary blood flow predominantly fulfills the intra-myocardial blood pool without an increase in intra-myocardial pressure, which is why the slope of the diastolic deceleration flow velocity is gradual in both normal subjects and in patients with good reflow. In the case of the no reflow phenomenon, the intra-myocardial blood pool is reduced; and thus, the coronary blood flow rapidly fills the reduced blood pool so that the distal coronary pressure rapidly increases. The increased distal pressure competes with the coronary inflow, resulting in a rapid deceleration of the diastolic flow velocity. A shorter DHT might be associated with more extensive microvascular damage; and therefore, the DHT measured with TTE could be a useful predictor of myocardial viability after an acute anterior myocardial infarction.³⁰⁾

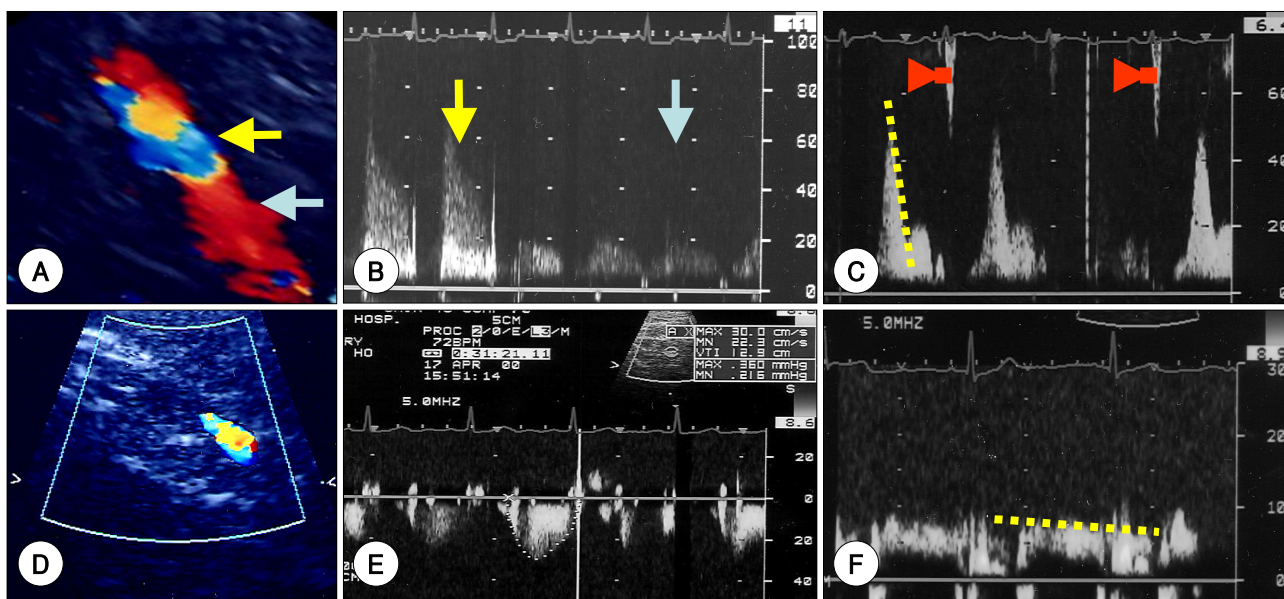


Fig. 3. Demonstration of pathologic coronary artery flows using TTE. A: localized aliasing from orange to blue at the stenotic site, with a curved front of the flow convergence proximal to the lesion. B: peak blood flow velocity in the normal segment (blue arrow) is <20 cm/s, increasing to >70 cm/s within the stenotic lumen (yellow arrow). The increase in velocity suggested by the aliasing could be confirmed by pulsed Doppler sampling. C: rapid deceleration slope of the diastolic velocity, with systolic reversal flow (arrow). D: flow with blue color, suggesting retrograde flow at the anterior apex. E: pulse Doppler signals of retrograde flow. F: profoundly reduced diastolic peak velocity, with a prolonged deceleration slope.

Retrograde flow

The noninvasive diagnosis of total coronary occlusion before coronary angiogram has been difficult, especially in patients without anginal symptoms, ventricular dysfunction or ECG changes. TTE permits non-invasive and quantitative measurements of the coronary blood flow velocity beyond the totally occluded arterial segments. The presence of collateral flow can be inferred when retrograde blood flow is detected distal to the site of a total occlusion (Fig. 3D, E).

Retrograde flow in the LAD using TTE was a highly sensitive and specific finding in the noninvasive diagnosis of total LAD occlusion has been observed.³²⁾ After the occlusion of a major epicardial coronary artery, blood flow to the previously supplied myocardium must arrive through the coronary collateral vessels. The retrograde blood flow velocity distal to the totally occluded coronary vessel represents a collateral flow to the occluded region. TTE allows for noninvasive and quantitative measurements of the coronary blood flow velocity beyond the totally occluded arterial segments. However, caution is required since the occluded LAD, which is filled through the uncommon collateral channels, such as high-lateral branch or conus branch, may have normal antegrade flow in the midportion of the LAD.

Flow damping-slow flow

Crowley et al.²²⁾ reported that patients with severe stenosis demonstrated profound reduction in the diastolic component of the blood flow velocity in the distal LAD compared to those with less severe stenosis. With stenosis, the phasic pattern of coronary flow was partly damped out (Fig. 3F). The reduction observed in the diastolic flow velocity distal to the stenoses may be due to the greater effect of the stenosis severity on the blood flow during a period of low distal (intramyocardial) vascular resistance than when the distal vascular resistance is high.¹⁰¹⁾ Logan¹⁰²⁾ reported that the flow decreased with increasing degree of stenosis only when the distal resistance was low, which was almost independent of the degree of stenosis (except in regions of very severe stenosis) when distal resistance was relatively high. In clinical situations, the percentage of luminal narrowing read from the coronary angiogram is often used as the gold standard for describing stenosis severity. However, the coronary angiogram images only internally outlines the vessels, thus the diffuse coronary narrowing cannot be expressed by the percentage of narrowing. Also, several problems have arisen with this conventional evaluation method because of the various factors that may contribute to generating the pressure-loss across the coronary stenosis.

With regard to the above, the flow damping measured with TTE distal to the stenotic segment reflects

not only the percentage of the stenosis diameter, but also other geometrical factors, such as the length and complexity of stenotic lesions.

Defining the normal range of diastolic coronary flow velocity in the distal LAD for clinical decision making is very important in differentiating normal from pathologic flow. Even though the definition of the normal value for the distal LAD flow remains to be settled, due to various factors affecting the baseline coronary flow velocity, an extremely slow diastolic velocity of less than 13 cm/sec may suggest the pathologic flow dynamics are impairing the myocardial perfusion.³⁸⁾ Recently, the authors³⁷⁾³⁸⁾ confirmed these findings using non-invasive techniques in patients with significant stenosis of the LAD of more than 70%. The peak diastolic velocities were 13.4 ± 5.5 , 15.1 ± 6.8 and 22.1 ± 11.8 cm/s in 5 patients with TIMI 1 flow, 18 with TIMI 2 flow and in those with TIMI 3 flow, respectively ($p < 0.01$ versus TIMI grade 1 and grade 2 flow, respectively).³⁷⁾ A peak diastolic velocity less than 13 cm/s had a sensitivity and specificity of 58 and 91%, respectively, for identifying lesion types B2 and C using the ACC/AHA guideline.³⁸⁾

Furthermore, the measurement of the distal flow velocity after reperfusion in patients with acute myocardial infarction is useful in characterizing reflow. The thrombolysis in Myocardial Infarction (TIMI) trial flow grading system is the gold standard for assessing coronary patency.¹⁰³⁾ Recent investigations demonstrated that mortality and left ventricular function were no better among patients with TIMI grade 2 flow than in those with TIMI 0 and 1 flows.¹⁰⁴⁾¹⁰⁵⁾ This finding indicates that the angiographic assessment of coronary patency does not necessarily reflect the optimal myocardial reperfusion in characterizing reflow. Nakamura et al.¹⁰⁶⁾ reported less diastolic dominant phasic flow, using Doppler guide wire, even after the establishment of widely patent arteries, which may be involved in extensive microcirculation damage, and a low diastolic systolic velocity ratio was significantly related to angiographic slow flow. Therefore, the assessment of the coronary flow velocity using TTE after reperfusion is a promising new approach for determining the adequacy of reperfusion and therapeutic strategies for the treatment of patients with acute anterior myocardial infarction.

Until now, the clinical significance of the baseline coronary flow velocity has been underestimated. Coronary angiography demonstrates the phenomenon of "slow dye progression" in patients with angina-like chest pain and nonstenotic coronary arteries. Although this phenomenon has been observed by every experienced angiographer, only a few reports¹⁰⁷⁻¹¹⁵⁾ have been published, and the underlying mechanisms as well as its clinical significance are still unclear. Tambe et al.¹⁰⁷⁾

suggested an abnormally high small-vessel resistance as the cause of slow flow, but their conclusions were based only on indirect evidence, namely the absence of significant epicardial coronary artery disease in patients with angina pectoris. Goel et al.¹¹³⁾ reported that patients with slow flow constitute a definite subset within the wide spectrum of syndrome X, and that this phenomenon could be used as a marker for myocardial ischemia. Therefore, further study of coronary hemodynamics using TTE in patients with the slow dye progression phenomenon and nonstenotic coronary arteries seems justified.

Predominant systolic flow at anastomosis site of graft vessel

With the patient in the left lateral position, using a low left parasternal window, long-axis images of the left ventricle can be obtained. The imaging depth should be reduced to visualize the interventricular sulcus anterior to the right ventricular outflow tract. Using combined 2-dimensional imaging and color flow mapping, a left IMA graft can be identified as a tubular structure, with color flow directed from base to apex. Once the position of the left IMA has been identified, intraluminal flow signals are obtained using pulsed Doppler. The rate of direct visualization of native IMA was can be as high as 100%.⁷⁷⁾ Transthoracic echocardiographic visualization of a left IMA graft in published studies has varied from 70 to 95%.⁷⁸⁾⁷⁹⁾

In the native internal mammary artery, the flow is dominant during systole, and only low-velocity profiles are recorded during diastole. Patent IMA grafts show a gradual transition in the flow pattern from predominant systolic velocity proximally (at the origin from the subclavian artery) to predominant diastolic velocity distally (immediately proximal to the anastomosis with the native coronary artery).⁷⁸⁾⁷⁹⁾ At the distal anastomotic site of an IMA graft without significant stenosis, the typical pulsed Doppler flow pattern is similar to that of the coronary artery with a predominant diastolic component (Fig. 4A). When an IMA graft develops stenosis, low velocity profiles are recorded during diastole, with an increase in the systolic component (Fig. 4B).

Estimation of Coronary Flow Reserve(CFR) Using TTE

Technical aspect

The change in the coronary flow velocity in the epicardial coronary artery, not the coronary flow volume, is measured, although assessment of CFR is ideal for the estimation of coronary microcirculation. However, changes in the coronary flow velocity during drug-induced hyperemia have been alternatively used for assessment of CFR because the coronary flow velocity correlates well with the coronary flow.

In the measurement of the CFR using TTE, dipyridamole and adenosine have been used as vasodilating agents. After obtaining the baseline coronary flow velocity, dipyridamole is infused at a rate of 0.56 mg/kg/min for 4 minutes. Peak vasodilating activity is obtained 2 to 4 minutes after the cessation of dipyridamole infusion. Alternatively, adenosine can be infused intravenously, inducing rapid onset of vasodilation, resulting in briefer examination periods comparable with those of dipyridamole. The coronary flow velocities are measured before and immediately after the cessation of the adenosine infusion. The CFR is expressed as the ratio of the peak diastolic flow velocity during maximal vasodilation to that of the basal diastolic flow velocity (Fig. 5).

Clinical application

The measurement of the CFR using TTE was applied primarily in patients with normal coronary angiogram and chest pain, such as hypertrophic cardiomyopathy and aortic stenosis.³³⁾³⁶⁾⁴³⁾⁴⁹⁾⁶¹⁾⁶²⁾ Having proven the close relationship between the noninvasive and invasive methods,⁴²⁾⁵⁰⁾⁵⁶⁾ it has been applied to evaluate the severity of stenosis,⁴¹⁾⁵¹⁾⁵³⁾⁵⁴⁾ evaluate the improvement in the coronary flow after interventional treatment, such as balloon angioplasty and stent insertion, and for the early detection⁵⁹⁾ of restenosis. Intracoronary Doppler has been introduced to optimize the results of percutaneous coronary intervention,¹¹⁶⁾¹¹⁷⁾ but it has shown surprisingly high rates of impaired CFR after balloon angioplasty or stenting (50 and 30% respec-

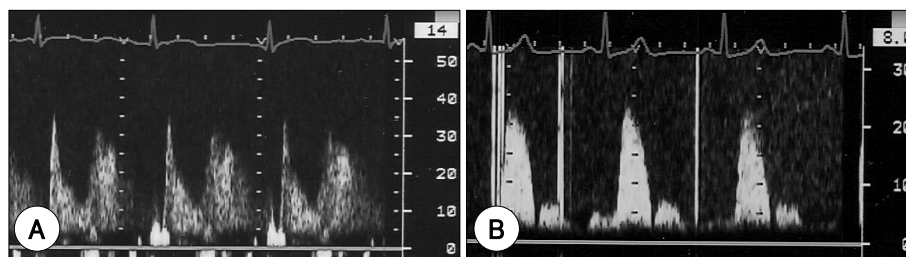


Fig. 4. A: pulsed doppler signals at the anastomosis site of the patent IMA graft, showing biphasic flow with dominant diastolic and smaller systolic components. B: pulsed doppler signals recorded from the occluded IMA graft, showing systolic dominant flow, similar to a native internal mammary artery. IMA: internal mammary artery.

tively), even in the absence of residual angiographic stenosis.¹¹⁸⁾ This phenomenon is explained by two complicating theories: microvascular stunning, where the microcirculation is not able to increase flow; or reactive hyperemia, where a high post-ischemic baseline flow velocity masks the normal reserve. Invasive CFR is obtained after multiple balloon inflation, injection of a contrast agent and the administration of vasoactive drugs that may produce immediate post-procedural vasomotion instability.¹¹⁹⁾¹²⁰⁾

After stenting, a decrease in the post-procedural baseline velocity was found, although intracoronary Doppler showed the same pre-procedural and post-procedural baseline values.¹¹⁷⁾ Coronary stenosis may induce flow acceleration or turbulence, or both, even at rest.¹²¹⁾ After stent implantation, the laminar flow may be restored and the velocity reset toward normal reference values.²⁶⁾ Accordingly, recovery of CFR after successful stenting is related to the normalization of

both the baseline and hyperemic flow velocities, indicating adequate lumen enlargement and normal vascular conductance have been obtained. Since the intracoronary Doppler was performed immediately after the intervention, it may not reflect the actual CFR. Measurement of the CFR using TTE several days after the intervention may provide more accurate information on the coronary hemodynamics.

Pizzuto et al.⁵⁹⁾ found a CFR of less than 1.0 in patients with severe LAD stenosis. This finding was in agreement with the experimental work of Gould et al,¹²²⁾ which showed hyperemia to disappear in 88 to 93% vessel stenosis. According to several studies using TTE,⁴⁵⁾⁴⁶⁾⁴⁸⁾⁵¹⁾⁵³⁾⁵⁴⁾ the cut-off value of the CFR is generally accepted to be less than 2.0 for predicting LAD stenosis of more than 70%.

Assessment of the CFR before and after coronary angioplasty may be useful in detecting early restenosis, which may serve as an index of outcome for the pro-

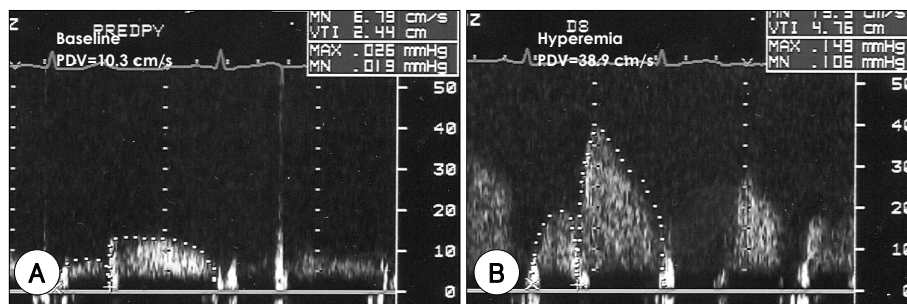


Fig. 5. Measurement of the CFR using TTE. A: pulse Doppler signals of the distal LAD at rest. B: systolic and diastolic coronary flow velocities markedly increase after adenosine infusion. The CFR is calculated as the ratio of the hyperemic peak diastolic velocity (PDV) after the intravenous infusion of Adenosine to that of the resting PDV. The CFR in this patient is 3.78. LAD: left anterior descending coronary artery, CFR: coronary flow reserve.

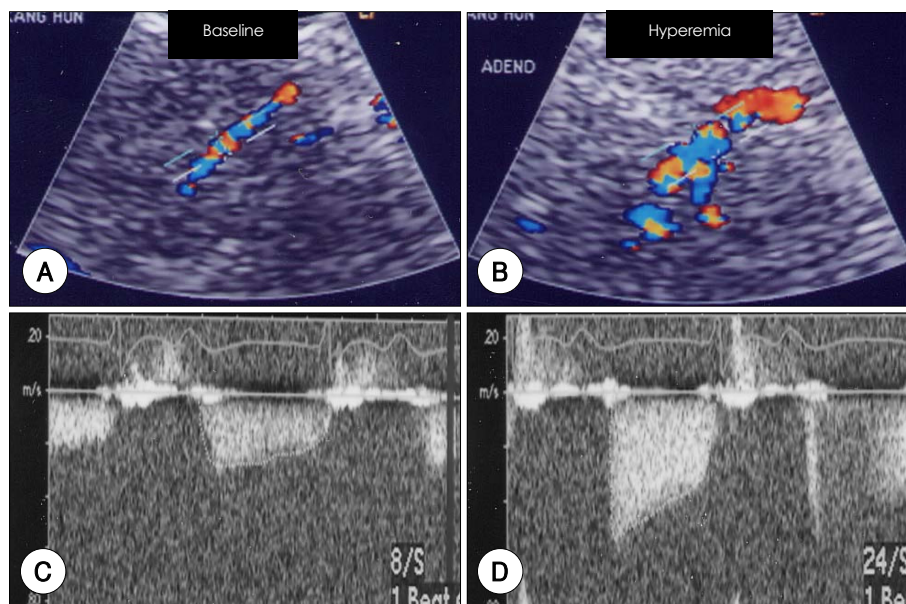


Fig. 6. The measurement method of the PICA-CFR. A: color Doppler signal of the PICA in the resting state. B: color Doppler signal of the PICA in maximal hyperemia. C & D: the PICA-CFR is calculated as the ratio of the hyperemic peak diastolic velocity (PDV) after the intravenous infusion of adenosine to that of the resting PDV. PICA-CFR: coronary flow reserve of penetrating intramyocardial coronary artery, PDV: peak diastolic velocity.

cedure. CFR measurement using TTE may be decisive for the functional assessment of intermediate lesions to find clear-cut arguments in favor of or against the indication for coronary intervention. It can also be used for the early detection of endothelial dysfunction since atherosclerotic acceleration changes after the cardiac transplantation.

New measurement method of CFR using TTE

Recently, the measurement method of PICA-CFR was introduced (Fig. 6). Measurement of the PICA-CFR showed more than a 90% success rate compared to that of CFR measurement of the epicardial coronary arteries using TTE.⁷³⁾ In this study, the group with apical hypertrophy had significantly higher baseline

coronary flow velocities of the PICA and lower PICA-CFR than those of the control group. Performing measurements of PICA-CFR, closer to the site of root arteries, which were previously measured in the distal epicardial coronary arteries, may be helpful in recognizing the influential factors that decrease the CFR, which may offer insight into the spectrum of coronary physiology in diseased myocardium.

Conclusions

TTE is emerging as a promising method for evaluating coronary artery disease. After a period of training, the detection and measurement of the distal LAD flow with TTE is feasible in more than 90 % of the patients.

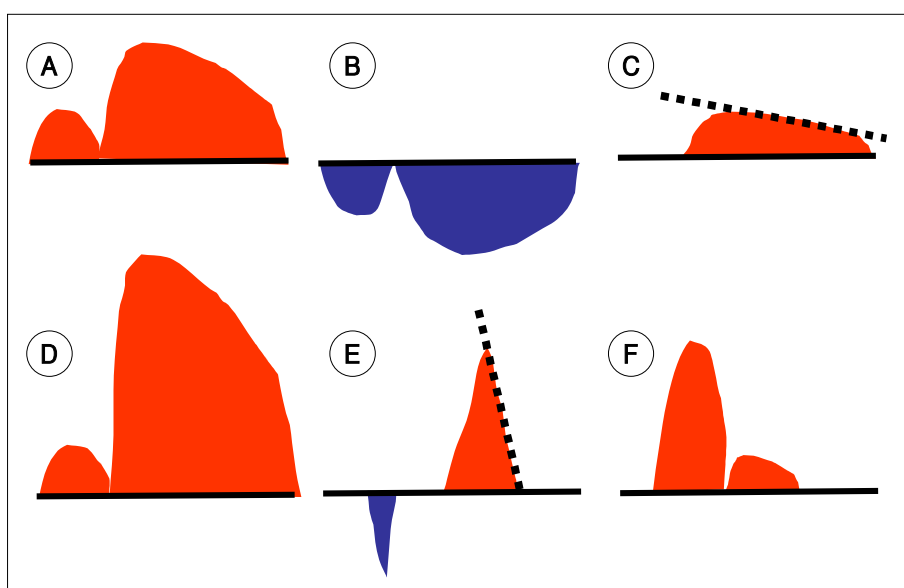


Fig. 7. Schematic representation of pathologic flow patterns using TTE. A: normal flow pattern of distal LAD showing biphasic flow, with dominant diastolic and smaller systolic components. B: retrograde flow suggesting filling via collateral circulation in the total occlusion of the LAD. C: slow flow, with a profoundly reduced diastolic velocity and prolonged deceleration slope. D: high velocity flow within the stenotic lumen. E: the rapid deceleration slope of the diastolic velocity and systolic flow reversal, suggesting extensive microvascular damage after an acute anterior myocardial infarction. F: systolic dominant flow at the anastomosis site of the IMA graft, suggesting occlusion of the graft vessel. LAD: left anterior descending coronary artery, IMA: internal mammary artery.

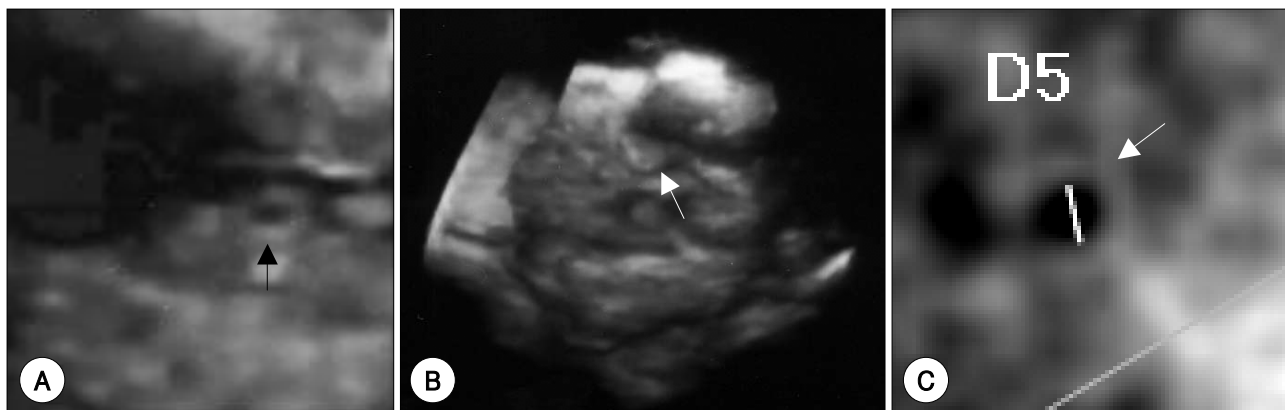


Fig. 8. Real time 3D images of the coronary artery. A: the arrow shows the cut section of ostium of left coronary artery. B: the arrow shows the mid portion of the RCA. C: the arrow shows the cut section of the stent inserted at the proximal LAD. RCA: right coronary artery, LAD: left anterior descending coronary artery.

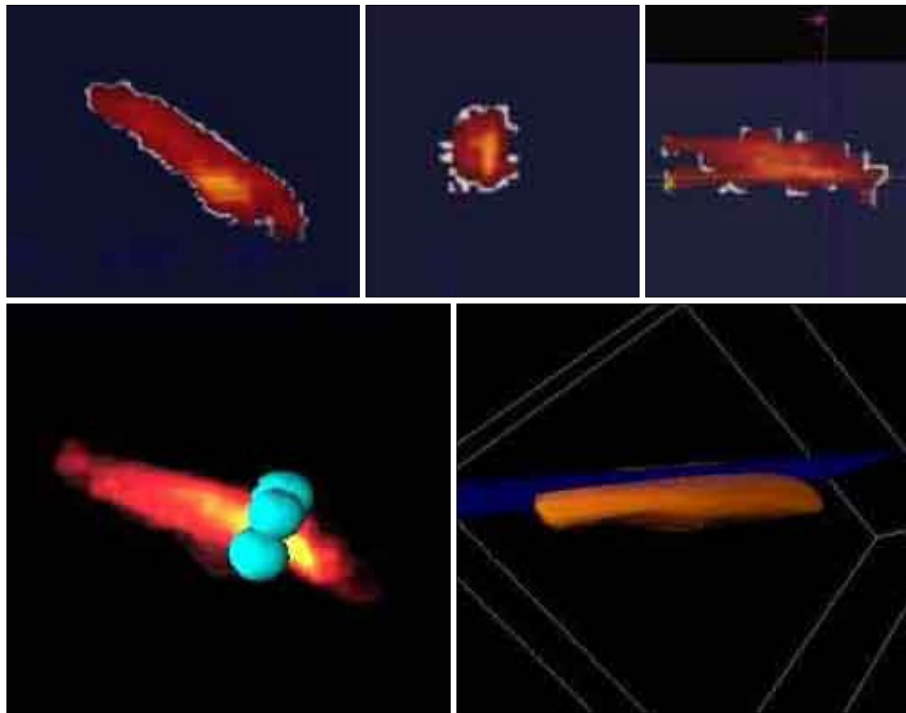


Fig. 9. An example of reconstructed coronary artery flow using freehand 3D Echocardiography with rotational scanning.

Using TTE, with a high frequency transducer and special setting of low Nyquist limits, the pathologic flow dynamics of LAD were demonstrated, as follows (Fig. 7) :

Retrograde flow suggests filling via the collateral circulation in the total occlusion of LAD. Not only the abnormally low velocity, but also the abnormally high velocity, suggested pathological conditions of the coronary artery at resting. Furthermore, extremely slow flows predict severe and diffuse atherosclerotic narrowing of the LAD, resulting in myocardial ischemia. A short DHT of the diastolic coronary flow velocity measured by TTE might be associated with more extensive microvascular damage after an acute anterior myocardial infarction. A systolic dominant flow pattern at the anastomosis site predicts the occlusion of graft vessels. A CFR of less than 2.0 predicts stenosis of more than 70%.

Live 3D visualization of the coronary artery (Fig. 8)¹²³⁾ and free hand 3D reconstruction of the coronary artery flow using TTE (Fig. 9) could be valuable supplements to 2D TTE in the assessment of the anatomic and functional severity of coronary artery disease in the near future.

REFERENCES

- 1) Bache RJ, Cobb FR. *Effect of maximal coronary vasodilation on transmural myocardial perfusion during tachycardia in the awake dog.* *Circ Res* 1977;41:648-53.
- 2) Marcus ML, Doty DB, Hiratzka LF, Wright CB, Eastham CL. *Decreased coronary reserve: a mechanism for angina pectoris in patients with aortic stenosis and normal coronary arteries.* *N Engl J Med* 1982;307:1362-6.
- 3) Klocke FJ. *Measurements of coronary flow reserve: defining pathophysiology versus making decisions about patient care.* *Circulation* 1987;76:1183-9.
- 4) Demer L, Gould KL, Kirkeeide R. *Assessing stenosis severity: coronary flow reserve, collateral function, quantitative coronary arteriography, positron imaging, and digital subtraction angiography. A review and analysis.* *Prog Cardiovasc Dis* 1988;30:307-22.
- 5) Youn, HJ, Foster E. *Transesophageal echocardiography (TEE) in the evaluation of the coronary arteries.* *Cardiol Clin* 2000; 18:833-48.
- 6) Youn HJ, Park CS, Moon KW, et al. *Relation between Duke treadmill score and coronary flow reserve using transesophageal Doppler echocardiography in patients with microvascular angina.* *Int J Cardiol* 2005;98:403-8.
- 7) Fusejima K. *Noninvasive measurement of coronary artery blood flow using combined two-dimensional and Doppler echocardiography.* *J Am Coll Cardiol* 1987;10:1024-31.
- 8) Ross JJ Jr, Mintz GS, Chandrasekaran K. *Transthoracic two-dimensional high frequency (7.5 MHz) ultrasonic visualization of the distal left anterior descending coronary artery.* *J Am Coll Cardiol* 1990;15:373-7.
- 9) Kenny A, Shapiro LM. *Transthoracic high-frequency two-dimensional echocardiography, Doppler and color flow mapping to determine anatomy and blood flow patterns in the distal left anterior descending coronary artery.* *Am J Cardiol* 1992;69: 1265-8.
- 10) Kenny A, Wisbey CR, Shapiro LM. *Measurement of left anterior descending coronary artery flow velocities by transthoracic Doppler ultrasound.* *Am J Cardiol* 1994;73:1021-2.
- 11) Jureidini SB, Marino CJ, Waterman B, et al. *Transthoracic Doppler echocardiography of normally originating coronary arteries in children.* *J Am Soc Echocardiogr* 1998;11:409-20.
- 12) Voci P, Testa G, Plaustro G. *Imaging of the distal left anterior*

- descending coronary artery by transthoracic color-Doppler echocardiography. *Am J Cardiol* 1998;81:74G-8G.
- 13) Bartel T, Muller S, Baumgart D, Mathew BT, Haude M, Erbel R. Improved high-frequency transthoracic flow velocity measurement in the left anterior descending coronary artery after intravenous peripheral injection of levovist. *J Am Soc Echocardiogr* 1999;12:252-6.
 - 14) Loperfido F, Lombardo A, de Luca M, Natali R, Manolfi M, Ierardi C. Echocardiographic imaging in coronary artery disease: new techniques. *Rays* 1999;24:60-72.
 - 15) Harada K, Orino T, Hironaka C, Takahashi Y, Takada G. Coronary blood flow velocity in normal infants and young adults assessed by transthoracic echocardiography. *Am J Cardiol* 1999;83:1583-5.
 - 16) Harada K, Tamura M, Orino T, Yasuoka K. Coronary blood flow assessed by transthoracic echocardiography in neonates. *Pediatr Cardiol* 2001;22:189-93.
 - 17) Voci P, Pizzuto F. Imaging of the posterior descending coronary artery: the last frontier in echocardiography. *Ital Heart J* 2001;2:418-22.
 - 18) Yasuoka K, Harada K, Tamura M, Takada G. Left anterior descending coronary artery flow and its relation to age in children. *J Am Soc Echocardiogr* 2002;15:69-75.
 - 19) Voci P, Pizzuto F. Coronary flow: how far can we go with echocardiography? *J Am Coll Cardiol* 2001;38:1885-7.
 - 20) Jureidini SB, Eaton C, Williams J, Nouri S, Appleton RS. Transthoracic two-dimensional and color flow echocardiographic diagnosis of aberrant left coronary artery. *Am Heart J* 1994;127:438-40.
 - 21) Crowley JJ, Shapiro LM. Analysis of phasic flow velocity dynamics in the left anterior descending coronary artery before and after angioplasty using transthoracic echocardiography in patients with stable angina pectoris. *Am J Cardiol* 1997;80:614-7.
 - 22) Crowley JJ, Shapiro LM. Noninvasive analysis of coronary artery poststenotic flow characteristics by using transthoracic echocardiography. *J Am Soc Echocardiogr* 1998;11:1-9.
 - 23) Birnbaum Y, Chaux A, Luo H, Nagai T, Naqvi T, Siegel RJ. Visualization of stents in the left anterior descending coronary artery by transthoracic echocardiography in pigs and humans. *Am J Cardiol* 1998;81:229-31.
 - 24) Ohta T, Shimizu H, Kobayashi S, Ishikawa S, Izumi S. Detection of coronary blood flow associated with right coronary ostial stenosis by means of transthoracic Doppler echocardiography. *J Am Soc Echocardiogr* 1998;11:984-5.
 - 25) Voci P, Testa G, Plaustro G, Caretta Q. Coronary Doppler intensity changes during handgrip: a new method to detect coronary vasomotor tone in coronary artery disease. *J Am Coll Cardiol* 1999;34:428-34.
 - 26) Hozumi T, Yoshida K, Akasaka T, et al. Value of acceleration flow and the prestenotic to stenotic coronary flow velocity ratio by transthoracic color Doppler echocardiography in noninvasive diagnosis of restenosis after percutaneous transluminal coronary angioplasty. *J Am Coll Cardiol* 2000;35:164-8.
 - 27) Saraste M, Koskenvuo JW, Mikkola J, Pelttari L, Toikka JO, Hartiala JJ. Technical achievement: transthoracic Doppler echocardiography can be used to detect LAD restenosis after coronary angioplasty. *Clin Physiol* 2000;20:428-33.
 - 28) Krzanowski M, Bodzon W, Brzostek T, Nizankowski R, Szczeklik A. Value of transthoracic echocardiography for the detection of high-grade coronary artery stenosis: prospective evaluation in 50 consecutive patients scheduled for coronary angiography. *J Am Soc Echocardiogr* 2000;13:1091-9.
 - 29) Takeuchi M, Miyazaki C, Yoshitani H, Otani S, Sakamoto K, Yoshikawa J. Assessment of coronary flow velocity with transthoracic Doppler echocardiography during dobutamine stress echocardiography. *J Am Coll Cardiol* 2001;38:117-23.
 - 30) Shintani Y, Ito H, Iwakura K, et al. Prediction of wall motion recovery from the left anterior descending coronary artery velocity pattern recorded by transthoracic Doppler echocardiography in patients with anterior wall myocardial infarction retrospective and prospective studies. *Jpn Circ J* 2001;65:717-22.
 - 31) Youn HJ, Park CS, Cho EJ, et al. Analysis of Coronary Artery Flow Patterns in Patients with Chest Pain and Normal Coronary Angiogram: Study Using Transthoracic Doppler Echocardiography. *Korean Circ J* 2003;33:205-11.
 - 32) Watanabe N, Akasaka T, Yamaura Y, et al. Noninvasive detection of total occlusion of the left anterior descending coronary artery with transthoracic Doppler echocardiography. *J Am Coll Cardiol* 2001;38:1328-32.
 - 33) Kenny A, Wisbey CR, Shapiro LM. Profiles of coronary blood flow velocity in patients with aortic stenosis and the effect of valve replacement: a transthoracic echocardiographic study. *Br Heart J* 1994;71:57-62.
 - 34) Crowley JJ, Dardas PS, Harcombe AA, Shapiro LM. Transthoracic Doppler echocardiographic analysis of phasic coronary blood flow velocity in hypertrophic cardiomyopathy. *Heart* 1997;77:558-63.
 - 35) Petkow Dimitrow P, Krzanowski M, Nizankowski R, Szczeklik A, Dubiel JS. Effect of verapamil on systolic and diastolic coronary blood flow velocity in asymptomatic and mildly symptomatic patients with hypertrophic cardiomyopathy. *Heart* 2000;83:262-6.
 - 36) Oskarsson G, Pesonen E. Coronary flow abnormalities in neonates with aortic stenosis. *J Pediatr* 2000;137:875-7.
 - 37) Youn HJ, Park CS, Cho EJ, et al. Coronary Artery Flow Velocity Pattern Predicting Myocardial Recovery after Acute Anterior Myocardial Infarction. *Korean Circ J* 2003;33:259-68.
 - 38) Youn HJ, Park CS, Cho EJ, et al. Clinical Significance of Slow Flow Velocity in the Distal Left Anterior Descending Coronary Artery Detected by Transthoracic Doppler Echocardiography. *Korean Circ J* 2002;32:299-308.
 - 39) Youn HJ, Foster E. Demonstration of coronary artery flow using transthoracic Doppler echocardiography. *J Am Soc Echocardiogr* 2004;17:178-85.
 - 40) Crowley JJ, Shapiro LM. Transthoracic echocardiographic measurement of coronary blood flow and reserve. *J Am Soc Echocardiogr* 1997;10:337-43.
 - 41) Hozumi T, Yoshida K, Ogata Y, et al. Noninvasive assessment of significant left anterior descending coronary artery stenosis by coronary flow velocity reserve with transthoracic color Doppler echocardiography. *Circulation* 1998;97:1557-62.
 - 42) Hozumi T, Yoshida K, Akasaka T, et al. Noninvasive assessment of coronary flow velocity and coronary flow velocity reserve in the left anterior descending coronary artery by Doppler echocardiography: comparison with invasive technique. *J Am Coll Cardiol* 1998;32:1251-9.
 - 43) Asami Y, Yoshida K, Hozumi T, et al. Assessment of coronary flow reserve in patients with hypertrophic cardiomyopathy using transthoracic color Doppler echocardiography. *J Cardiol* 1998;32:247-52.
 - 44) Caiati C, Montaldo C, Zedda N, Bina A, Iliceto S. New noninvasive method for coronary flow reserve assessment: contrast-enhanced transthoracic second harmonic echo Doppler. *Circulation* 1999;99:771-8.
 - 45) Lambert H, Bonhof J, Brechtken J, Stein T, Tries HP, Lethen H. Noninvasive determination of coronary flow reserve with signal enhanced high resolution transthoracic Doppler color echo-

- cardiography. *Herz* 1998;23:516-25.
- 46) Lambertz H, Tries HP, Stein T, Lethen H. Noninvasive assessment of coronary flow reserve with transthoracic signal-enhanced Doppler echocardiography. *J Am Soc Echocardiogr* 1999;12:186-95.
 - 47) Hildick-Smith DJ, Shapiro LM. Potential use of transthoracic echocardiography in the assessment of coronary flow reserve. *J Am Soc Echocardiogr* 1999;12:590-5.
 - 48) Caiati C, Zedda N, Montaldo C, Montisci R, Ilceto S. Contrast-enhanced transthoracic second harmonic echo Doppler with adenosine: a noninvasive, rapid and effective method for coronary flow reserve assessment. *J Am Coll Cardiol* 1999;34:122-30.
 - 49) Dimitrow PP, Krzanowski M, Nizankowski R, Szczeklik A, Dubiel JS. Verapamil improves the response of coronary vasomotion to cold pressor test in asymptomatic and mildly symptomatic patients with hypertrophic cardiomyopathy. *Cardiovasc Drugs Ther* 1999;13:259-64.
 - 50) Caiati C, Montaldo C, Zedda N, et al. Validation of a new noninvasive method (contrast-enhanced transthoracic second harmonic echo Doppler) for the evaluation of coronary flow reserve: comparison with intracoronary Doppler flow wire. *J Am Coll Cardiol* 1999;34:1193-200.
 - 51) Caiati C, Cioglia G, Montaldo C, et al. Correlation of 99mTc-sestamibi SPECT myocardial perfusion imaging with absolute coronary flow reserve by a new noninvasive Doppler method in patients with stenoses of the left anterior descending coronary artery: a preliminary report. *Cardiologia* 1999;44:809-16.
 - 52) Lim HE, Shim WJ, Rhee H, et al. Assessment of coronary flow reserve with transthoracic Doppler echocardiography: comparison among adenosine, standard-dose dipyridamole, and high-dose dipyridamole. *J Am Soc Echocardiogr* 2000;13:264-70.
 - 53) de Simone L, Caso P, Severino S, et al. Reduction of coronary flow reserve non-invasively determined by transthoracic Doppler echocardiography as a predictor of left anterior descending coronary artery stenosis. *Ital Heart J* 2000;1:289-94.
 - 54) Lethen H, Ekinici O, Tries HP, Lambertz H. Echocardiographic measurements of coronary flow reserves in the left anterior descending artery allows detection of significant stenosis. *Dtsch Med Wochenschr* 2000;125:551-6.
 - 55) Saraste M, Koskenvuo J, Knuuti J, et al. Coronary flow reserve: measurement with transthoracic Doppler echocardiography is reproducible and comparable with positron emission tomography. *Clin Physiol* 2001;21:114-22.
 - 56) Kuriki S, Nasu M, Fukami Ki K, Hiramori K. Noninvasive measurement of left coronary blood flow reserve by transthoracic Doppler echocardiography: comparison with Doppler guide-wire ultrasonography. *Echocardiography* 1999;16:547-57.
 - 57) Daimon M, Watanabe H, Yamagishi H, et al. Physiologic assessment of coronary artery stenosis by coronary flow reserve measurements with transthoracic Doppler echocardiography: comparison with exercise thallium-201 single positron emission computed tomography. *J Am Coll Cardiol* 2001;37:1310-5.
 - 58) Hozumi T, Akasaka T, Yoshida K, Yoshikawa J. Noninvasive estimation of coronary flow reserve by transthoracic Doppler echocardiography with a high-frequency transducer. *J Cardiol* 2001;37 (Suppl 1):43-50.
 - 59) Pizzuto F, Voci P, Mariano E, Puddu PE, Sardella G, Nigri A. Assessment of flow velocity reserve by transthoracic Doppler echocardiography and venous adenosine infusion before and after left anterior descending coronary artery stenting. *J Am Coll Cardiol* 2001;38:155-62.
 - 60) Hirata K, Shimada K, Watanabe H, et al. Modulation of coronary flow velocity reserve by gender, menstrual cycle and hormone replacement therapy. *J Am Coll Cardiol* 2001;38:1879-84.
 - 61) Dimitrow PP, Krzanowski M, Nizankowski R, Szczeklik A, Dubiel JS. Comparison of the effect of verapamil and propranolol on response of coronary vasomotion to cold pressor test in symptomatic patients with hypertrophic cardiomyopathy. *Cardiovasc Drugs Ther* 2000;14:643-50.
 - 62) Park CS, Youn HJ, Cho EJ, et al. Influence of Left Bundle Branch Block on Left Anterior Descending Coronary Artery Flow: Study Using Transthoracic Doppler Echocardiography. *Korean Circ J* 2003;33:484-90.
 - 63) Chung WY, Sohn DW, Kim YJ, et al. Absence of postprandial surge in coronary blood flow distal to significant stenosis: a possible mechanism of postprandial angina. *J Am Coll Cardiol* 2002;40:1976-83.
 - 64) Kim HK, Kim YJ, Sohn DW, Park YB, Choi YS. Transthoracic echocardiographic evaluation of coronary flow reserve in patients with hypertrophic cardiomyopathy. *Int J Cardiol* 2004;94:167-71.
 - 65) Youn HJ, Jeon HK, Rhim HY, et al. Transthoracic Echo-Doppler Detection of distal left anterior descending Coronary Artery Flow Initial Experience of Clinical Feasibility. *Korean Circ J* 2000;30:1220-9.
 - 66) Park CS, Youn HJ, Cho EJ, et al. Comparison between Pattern of ST Change during Exercise Treadmill Test and Coronary Flow Reserve in Patients with Chest Pain and Normal Coronary Angiogram. *Korean Circ J* 2002;32:322-9.
 - 67) Yagi T, Yoshida K, Hozumi T, et al. Transthoracic digital color Doppler assessment of the left anterior descending coronary artery and intramyocardial blood flow. *J Cardiol* 1997;30:9-12.
 - 68) Minagoe S, Toyama Y, Niizoe K, et al. Transthoracic Doppler echocardiographic detection of intramyocardial coronary artery flow in humans using high frequency transducer. *J Cardiol* 1997;30:149-55.
 - 69) Youn HJ, Redberg RF, Schiller NB, Foster E. Demonstration of penetrating intramyocardial coronary arteries with high-frequency transthoracic echocardiography and Doppler in human subjects. *J Am Soc Echocardiogr* 1999;12:55-63.
 - 70) Minagoe S. Transthoracic Doppler echocardiographic assessment of left anterior descending coronary artery and intramyocardial small coronary artery flow in patients with hypertrophic cardiomyopathy. *J Cardiol* 2001;37 (Suppl 1):115-20.
 - 71) Youn HJ, Chung WS, Hong SJ. Images in cardiology: echocardiographic demonstration of multiple coronary artery-left ventricular microfistulae. *Heart* 2001;86:671.
 - 72) Youn HJ, Lee JM, Park CS, et al. The impaired flow reserve capacity of penetrating intramyocardial coronary arteries in apical hypertrophic cardiomyopathy. *J Am Soc Echocardiogr* 2005;18:128-32.
 - 73) Youn HJ, Chung WS, Hong SJ. Tumor feeding vessel in metastatic intracardiac mass demonstrated by transthoracic Doppler echocardiography. *Heart* 2002;88:216.
 - 74) Pezzano A, Cali G, Milazzo A, et al. Transthoracic 2D echo color Doppler assessment of internal mammary artery to left anterior descending coronary artery graft. *Int J Card Imaging* 1995;11:177-84.
 - 75) Crowley JJ, Shapiro LM. Noninvasive assessment of left internal mammary artery graft patency using transthoracic echocardiography. *Circulation* 1995;92 (9 Suppl):II25-30.
 - 76) Voci P, Testa G, Plaustro G, Marino B, Campa PP. Study of the coronary flow with high resolution transthoracic echocardiography and nondirectional Doppler. *Cardiologia* 1997;42:849-53.

- 77) Ehrams JE, Spittell PC, Seward JB. *Internal mammary artery: 100% visualization with new ultrasound technology. J Am Soc Echocardiogr* 1998;11:10-2.
- 78) de Simone L, Caso P, Severino S, et al. *Noninvasive assessment of left and right internal mammary artery graft patency with high-frequency transthoracic echocardiography. J Am Soc Echocardiogr* 1999;12:841-9.
- 79) Katz WE, Zenati M, Mandarino WA, Cohen HA, Gorcsan J 3rd. *Assessment of left internal mammary artery graft patency and flow reserve after minimally invasive direct coronary artery bypass. Am J Cardiol* 1999;84:795-801.
- 80) Voudris V, Athanassopoulos G, Vassilikos V, et al. *Usefulness of flow reserve in the left internal mammary artery to determine graft patency to the left anterior descending coronary artery. Am J Cardiol* 1999;83:1157-63.
- 81) Chirillo F, Bruni A, Balestra G, et al. *Assessment of internal mammary artery and saphenous vein graft patency and flow reserve using transthoracic Doppler echocardiography. Heart* 2001;86:424-31.
- 82) Ueno Y, Nakamura Y, Takashima H, Kinoshita M, Soma A. *Noninvasive assessment of coronary flow velocity and coronary flow velocity reserve in the right coronary artery by transthoracic Doppler echocardiography: comparison with intracoronary Doppler guidewire. J Am Soc Echocardiogr* 2002;15:1074-9.
- 83) Iwakura K, Ito H, Takiuchi S, et al. *Alternation in the coronary blood flow velocity pattern in patients with no reflow and reperfused acute myocardial infarction. Circulation* 1996;94:1269-75.
- 84) Young DF, Tsai FY. *Flow characteristics in models of arterial stenosis: II. unsteady flow. J Biomech* 1973;6:547-59.
- 85) Young DF, Cholvin NR, Roth AC. *Pressure drop across artificially induced in the femoral arteries of dogs. Cir Res* 1975;36:735-43.
- 86) Gould KL. *Pressure-flow characteristics of coronary stenosis in unsedated dogs at rest and during coronary vasodilation. Circ Res* 1978;43:242-53.
- 87) Rossen JD, Winniford MD. *Effects of increase heart rate and arterial pressure on coronary flow reserve in humans. J Am Coll Cardiol* 1993;21:343-8.
- 88) Klocke FJ. *Measurements of coronary flow reserve: defining pathophysiology versus making decisions about patient care. Circulation* 1987;76:1183-9.
- 89) Maron BJ, Epstein SE, Roberts WC. *Hypertrophic cardiomyopathy and transmural myocardial infarction without significant atherosclerosis of the extramural coronary arteries. Am J Cardiol* 1979;43:1086-102.
- 90) Opher D, Mall G, Zebe H, et al. *Reduction of coronary reserve: a mechanism for angina pectoris in patients with arterial hypertension and normal coronary arteries. Circulation* 1984;69:1-7.
- 91) Pichard AD, Gorlin R, Smith H, Ambrose J, Meller J. *Coronary flow studies in patients with left ventricular hypertrophy of the hypertensive type. Am J Cardiol* 1981;47:547-54.
- 92) Tanaka M, Fujiwara H, Onodera T, et al. *Quantitative analysis of narrowings of intramyocardial small arteries in normal hearts, hypertensive hearts, and hearts with hypertrophic cardiomyopathy. Circulation* 1987;75:1130-9.
- 93) Cannon RO 3rd, Watson RM, Rosing DR, Epstein SE. *Angina caused by reduced vasodilator reserve of the small coronary arteries. J Am Coll Cardiol* 1983;1:1359-73.
- 94) Mosseri M, Yarom R, Gotsman M, Hasin Y. *Histologic evidence for small-vessel coronary artery disease in patients with angina pectoris and patent large coronary arteries. Circulation* 1986;74:964-72.
- 95) Marcus ML, Doty DB, Hiratzka LF, Wright CB, Eastham CL. *Decreased coronary flow reserve: a mechanism for angina pectoris in patients with aortic stenosis and normal coronary arteries. N Engl J Med* 1982;307:1362-6.
- 96) Pasternac A, Noble J, Streulens Y, Elie R, Henschke C, Bourassa MG. *Pathophysiology of chest pain in patients with cardiomyopathies and normal coronary arteries. Circulation* 1982;65:778-89.
- 97) Gould KL, Kirkeeide RL, Buchi M. *Coronary flow reserve as a physiologic measure of stenosis severity. J Am Coll Cardiol* 1990;15:459-74.
- 98) Serruys PW, Mario CD, Kern MJ. *Intracoronary Doppler. In: Topol EJ editor. Textbook of Interventional Cardiology. 2nd ed. Philadelphia: WB Saunders; 1994. p.1069-121.*
- 99) Sabiston DC Jr, Gregg DE. *Effect of cardiac contraction on coronary blood flow. Circulation* 1957;15:14-20.
- 100) Kawamoto T, Yoshida K, Akasaka T, et al. *Can coronary blood flow velocity pattern after primary percutaneous transluminal coronary angioplasty predicts recovery of regional left ventricular function in patients with acute myocardial infarction? Circulation* 1999;100:339-45.
- 101) Kajiya F, Tsujioka K, Ogasawara Y, et al. *Analysis of flow characteristics in poststenotic regions of the human coronary artery during bypass graft surgery. Circulation* 1987;76:1092-100.
- 102) Logan SE. *On the fluid mechanics of human coronary artery stenosis. IEEE Trans Biomed Eng* 1975;22:327-34.
- 103) TIMI Study Group. *The Thrombolysis in Myocardial Infarction (TIMI) trial: phase I findings. N Engl J Med* 1985;312:932-6.
- 104) Vogt A, von Essen R, Tebbe U, Feuerer W, Apple KE, Neuhaus KL. *Impact of early reperfusion status of infarct-related artery on short-term mortality after thrombolysis for acute myocardial infarction: retrospective analysis of four German multicenter studies. J Am Coll Cardiol* 1993;21:1391-5.
- 105) Anderson JL, Karagounis L, Becker LC, Srensen SG, Menlove RL. *TIMI perfusion grade 3 but not grade 2 results in involved outcome after thrombolysis for myocardial infarction 1993;87:1829-39.*
- 106) Nakamura M, Tsunoda T, Wakatsuki T, et al. *Distal coronary flow velocity immediately after direct angioplasty for acute myocardial infarction. Am Heart J* 1996;132:251-7.
- 107) Tambe AA, Demany MA, Zimmerman HA, Mascarenhas E. *Angina pectoris and slow flow of dye in coronary arteries: a new angiographic finding. Am Heart J* 1972;84:66-71.
- 108) van Lierde J, Vrolix M, Sionis D, de Geest H, Piessens J. *Lack of evidence for small vessel disease in a patient with "slow dye progression" in the coronary arteries. Cathet Cardiovasc Diagn* 1991;23:117-20.
- 109) Voelker W, Euchner U, Dittmann H, Karsch KR. *Long-term clinical course of patients with angina and angiographically normal coronary arteries. Clin Cardiol* 1991;14:307-11.
- 110) Mangieri E, Macchiarelli G, Ciavolella M, et al. *Slow coronary flow: clinical and histopathological features in patients with otherwise normal epicardial coronary arteries. Cathet Cardiovasc Diagn* 1996;37:375-81.
- 111) Burckhardt BA, Mukerji V, Alpert MA. *Coronary artery slow flow associated with angina pectoris and hypotension: a case report. Angiology* 1998;49:483-7.
- 112) Kapoor A, Goel PK, Gupta S. *Slow coronary flow: a cause for angina with ST segment elevation and normal coronary arteries. Int J Cardiol* 1998;67:257-61.
- 113) Goel PK, Gupta SK, Agarwal A, Kapoor A. *Slow coronary flow: a distinct angiographic subgroup in syndrome X. Angiology* 2001;52:507-14.

- 114) Yaymaci B, Dagdelen S, Bozbuga N, *et al.* The response of the myocardial metabolism to atrial pacing in patients with coronary slow flow. *Int J Cardiol* 2001;78:151-6.
- 115) Kurtoglu N, Akcay A, Dindar I. Usefulness of oral dipyridamole therapy for angiographic slow coronary artery flow. *Am J Cardiol* 2001;87:777-9.
- 116) Kern MJ, Dupouy P, Drury JH, *et al.* Role of coronary artery lumen enlargement in improving coronary blood flow after balloon angioplasty and stenting: a combined intravascular ultrasound Doppler flow and imaging study. *J Am Coll Cardiol* 1997;29:1520-7.
- 117) van Liebergen RA, Piek JJ, Koch KT, de Winter RJ, Lie KI. Immediate and long-term effect of balloon angioplasty or stent implantation on the absolute and relative coronary blood flow velocity reserve. *Circulation* 1998;98:2133-40.
- 118) Kern MJ, Puri S, Bach RG, *et al.* Abnormal coronary flow velocity reserve after coronary artery stenting in patients: role of relative coronary reserve to assess potential mechanisms. *Circulation* 1999;100:2491-8.
- 119) Fischell TA, Derby G, Tse TM, Stadius ML. Coronary artery vasoconstriction routinely occurs after percutaneous transluminal coronary angioplasty: a quantitative arteriographic analysis. *Circulation* 1988;78:1323-34.
- 120) Fischell TA, Nellessen U, Johnson DE, Ginsburg R. Endothelium-dependent arterial vasoconstriction after balloon angioplasty. *Circulation* 1989;79:899-910.
- 121) Anderson HV, Stokes MJ, Leon M, Abu-Halawa SA, Stuart Y, Kirkeeide RL. Coronary artery flow velocity is related to lumen area and regional left ventricular mass. *Circulation* 2000;102:48-54.
- 122) Gould KL, Lipscomb K, Hamilton GW. Physiologic basis for assessing critical coronary stenosis: instantaneous flow response and regional distribution during coronary hyperemia as measures of coronary flow reserve. *Am J Cardiol* 1974;33:87-94.
- 123) Vengala S, Nanda NC, Agrawal G, *et al.* Live three-dimensional transthoracic echocardiographic assessment of coronary arteries. *Echocardiography* 2003;20:751-4.