

## 경도의 승모판 폐쇄 부전증이 있는 승모판 협착증 환자에서의 경피적 승모판 풍선 성형술의 조기성적 및 단기간내 재협착율

배준호 · 신동구 · 김형준 · 홍그루 · 전대진  
석준호 · 박종선 · 이종석 · 김영조 · 심봉섭

### Early Outcome and Short Term Restenosis Rate of the Mitral Balloon Valvuloplasty in Mitral Stenosis Patients with Mild Mitral Regurgitation

Jun Ho Bae, MD, Dong Gu Shin, MD, Hyung Jun Kim, MD, Gue Ru Hong, MD,  
Dae Jin Jeon, MD, Jun Ho Seok, MD, Jong Seon Park, MD,  
Jong Seok Lee, MD, Yeong Jo Kim, MD and Bong Sup Shim, MD

Department of internal Medicine, College of Medicine, Yeungnam University, Taegu, Korea

#### ABSTRACT

**Background :** Percutaneous mitral balloon valvuloplasty (PMV) has been proposed as an alternative to surgery for selected patients with symptomatic mitral stenosis. The presence of mild mitral regurgitation (MR) in mitral stenosis is usually not considered as a contraindication for the procedure. But, the results of PMV in the subgroup of patients with concomitant mild MR are unknown. Accordingly, this study evaluates the clinical outcome of a consecutive series of patients with mitral stenosis and mild MR undergoing PMV. **Methods :** Between August 1992 and December 1996 we attempted to dilate the mitral valves of 43 consecutive patients with symptomatic mitral stenosis. Mean age of the group was  $45.9 \pm 10.6$  years and 37 patients were women. They were divided into two groups according to the presence or absence of mild MR before the procedure. Clinical feature, initial result, complication were compared. **Results :** 1) Age, gender, symptomatic status, and atrial fibrillation were similar in both groups. 2) Patients with MR had more thickened valve ( $2.50 \pm 0.33$  vs  $1.84 \pm 0.55$ ,  $p = 0.048$ ) and subvalvular tissue ( $2.55 \pm 0.73$  vs  $1.88 \pm 0.73$ ,  $p = 0.015$ ), higher echocardiographic score ( $8.44 \pm 1.01$  vs  $7.08 \pm 1.65$ ,  $p = 0.004$ ). 3) Mitral valve area gain on the first day after PMV was smaller in patients with MR ( $p = 0.008$ ). 4) The success rate of PMV, the incidence of severe MR after PMV, and the restenosis rate on 6 month were similar in both groups. **Conclusion :** Although the PMV in patients with mild MR obtained smaller increments in mitral valve area compared to those without MR, they showed similar immediate and short-term results after PMV. (Korean Circulation J 1999;29(6):596-601)

**KEY WORDS :** Mitral stenosis · Mild mitral regurgitation · PMV.

: 1998 7 20  
: 1999 6 9  
: , 705 - 035 317 - 1  
: (053) 620 - 3830 · : (053) 654 - 8386  
E - mail : yjkim@medical.Yeungnam.ac.kr

서론	10.6 ( : 24 67 )		6
	37	가	가 25
(Percutaneous mitral balloon valvuloplasty, Inoue <sup>1)</sup> )	(58.1%)	가	가 18 (41.9%)
	PMV	PMV	,
가	가	경피적 승모판 풍선 성형술	Brockenbrough needle
	(open mitral commissurotomy)	가	Inoue
가	가	가 4.1 cm <sup>2</sup> /m <sup>2</sup>	PMV
	가	26 28 mm	2 mm
가	가	PMV	Q <sub>p</sub> /Q <sub>s</sub>
	가	가	
가	가	심초음파 검사	PMV
	가	Wilkins <sup>6)</sup>	1 1 , 6
가	가	2 - D	3
	가	5	Doppler color flow
대상 환자	1992 8 96 12	4	, 1 <1.5 cm, 2 1.5 cm , 3
	PMV	cm , 3 3 cm , 4.5 cm , 4 4.5 cm	
43	1.5 cm <sup>2</sup>	NYHA	1.5 cm <sup>2</sup>
	(New York Heart Association) functional class 2	가	25% 가 ,
(grade<2)	45.9±	가 10 mmHg	Grade 3

MVA) 50%  
통 계  
±  
test student t - test  
0.05  
chi - square  
p

## 결 과

### 일반적 특징

48 ± 12 ,  
45 ± 11  
84.6%, 86.7%  
NYHA  
class 2 30.8%,  
30%  
가 가  
53.8%, 36.7%  
(Table 1).

### 승모판의 Wilkin's 점수

Wilkin's 가  
8.44 ± 1.01 ,  
7.08 ± 1.65  
가 (p=0.004).  
(subvalvular thicken -  
ing) (valvular thickening)  
2.55 ± 0.73 1.88 ± 0.73 , 2.50  
± 0.33 1.84 ± 0.55  
가  
( p=0.015, p=0.048). (mobility)  
(calcification) 1.89 ±  
0.33 1.84 ± 0.37 , 1.88 ± 0.60 1.48 ± 0.65  
(Fig. 1).

### PMV시술의 특성

가 13  
12 (92.3%),

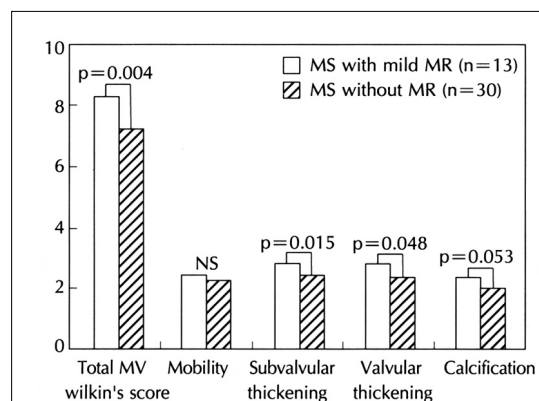
30 28 (93.3%) PMV가  
가 (8)  
0.94 ± 0.27 cm<sup>2</sup> 0.92 ± 0.25  
cm<sup>2</sup>, 1 1.64 ± 0.36 cm<sup>2</sup> 2.01 ± 0.32 cm<sup>2</sup>,  
6 1.56 ± 0.28 cm<sup>2</sup> 1.91 ± 0.31 cm<sup>2</sup>  
1  
가  
(p=0.008) 6  
(Fig. 2).  
27 ± 3.2 mm,  
27 ± 2.7 mm 가 .

### PMV시술후 합병증

**Table 1.** Baseline characteristics

	MS with mild MR (n = 13)	MS without MR (n = 30)	p value
Age (years)	48 ± 12	45 ± 11	NS
Sex Male	2 (15.4)	4 (13.3)	NS
Female	11 (84.6)	26 (86.7)	NS
NYGA class			
over 2	4 (30.8)	9 (30)	NS
Atrial fibrillation	7 (53.8)	11 (36.7)	NS
Pre-PMV			
Mitral valve area (cm <sup>2</sup> )	0.94 ± 0.27	0.92 ± 0.25	NS
MV Wilkin's score	8.44 ± 1.01	7.08 ± 1.65	0.004
PMV success	12 (92.3)	28 (93.3)	NS

Data presented are number of patients (%) or mean ± SD, NYHA class ; New York Heart Association Functional Classification, MV ; Mitral valve



**Fig. 1.** Mitral valve wilkin's score between patients groups.



가 .

가 13 12 (92.3%),  
30 28 (93.3%)

가 가 7.7% 3.3%

가 가

PMV

가 4 20%  
11 - 24) Nobuyoshi 19) PMV

가 , 가

19) Inoue PMV 50%

가

가 , Alfonso 18%

17) 가

7%  
6

30 50% 7.7% 3.3%

4 12% 16 - 21) , 가

PMV

20)21) 가

가 , 가

가 Alfonso 17)

가

가 4 - 21)

PMV

가

가 Roth 22)

가

Lau 5) Inoue

PMV

가 , 6 가

가 Alfonso 17)

가 PMV 가

## 결 론

가

중심 단어 :

## REFERENCES

- 1) Inoue K, Owaki T, Nakamura T, Kitamura F, Mivamoto N. *Clinical application of transvenous mitral commissurotomy by a new balloon catheter. J Thorac Cardiovasc Surg* 1984;87:394-402.
- 2) Lock JE, Khalilullah M, Shrivastava S, Bahl V, Keane JF. *Percutaneous catheter commissurotomy in rheumatic mitral stenosis. N Engl J Med* 1985;313:1515-8.
- 3) Hung JS, Chem MS, Wu JJ, Fu M, Yeh KH, Wu YC, et al. *Short-and long-term results of catheter balloon percutaneous transvenous mitral commissurotomy. Am J Cardiol* 1991;67:854-62.
- 4) Essop MR, Wisenbaugh T, Skoularigis J, Middlemost S, Sareli P. *Mitral regurgitation following mitral balloon valvotomy. Differing mechanisms for severe versus mild-to-moderate lesions. Circulation* 1991;84:1669-79.
- 5) Lau KW, Ding ZP, Hung JS. *Percutaneous Inoue-balloon valvuloplasty in patients with mitral stenosis and associated moderate mitral regurgitation. Cathet Cardiovasc Diagn* 1996;38:1-7.
- 6) Wilkins GT, Weyman AE, Abascal V, Block P, Palacios I. *Percutaneous balloon dilatation of the mitral valve: An analysis of echocardiographic variables related to outcome and the mechanism of dilatation. Br Heart J* 1988;60:299-308.
- 7) Lee MM, Yeon TJ, Son DW, Kim CH, Oh BH, Choi YS, et al. *Immediate and Late Outcomes after Percutaneous Mitral Commissurotomy. Korean Circulation J* 1997;27:318-25.
- 8) Kim JS, Kim CJ, Lee MM, Choi YS, Lee YW. *Immediate and Follow-Up Result after Percutaneous Mitral Valvuloplasty in Mitral Stenosis. Korean Circulation J* 1991;21:829-41.
- 9) Abascal VM, Wilkins GT, O'Shea JP, Choong CY, Palacios IF, Thomas JD, et al. *Prediction of successful outcome in 130 patients undergoing percutaneous balloon mitral valvotomy. Circulation* 1990;82:448-56.
- 10) The NHLBI Balloon Valvuloplasty Registry Participants. *Multicenter experience with balloon mitral commissurotomy. Circulation* 1992;85:448-61.
- 11) Abascal VM, Wilkins GT, Choong CY, Thomas JD, Palacios IF, Block PC, et al. *Echocardiographic evaluation of mitral structure and function in patients followed for at least 6 months after percutaneous balloon valvuloplasty. J Am Coll Cardiol* 1988;12:606-15.
- 12) Desideri A, Vanderperren O, Serra A, Barraud P, Petitcleic R, Lesperance J, et al. *Long-term (9 to 33 months) echocardiographic follow-up after successful percutaneous mitral commissurotomy. Am J Cardiol* 1992;69:1602-6.
- 13) Post JR, Feldman T, Isner J, Herrmann HC. *Inoue balloon mitral valvotomy in patients with severe valvular and subvalvular deformity. J Am Coll Cardiol* 1995;25:1129-36.
- 14) Hung JS, Chern MS, Wu JJ, Fu M, Yuh KH, Wu YC, et al. *Short-and long-term results of catheter balloon percutaneous transvenous mitral commissurotomy. Am J Cardiol* 1991;67:854-62.
- 15) Feldman T, Carroll JD, Isner JM, Chisholm RJ, Holmes DR, Massumi A, et al. *Effect of valve deformity on results and mitral regurgitation after Inoue balloon commissurotomy. Circulation* 1992;85:180-7.
- 16) Zhang HP, Gamra H, Allen JW, Lau FYK, Ruiz CE. *Balloon valvotomy for mitral stenosis associated with moderate mitral regurgitation. Am J Cardiol* 1995;75:960-3.
- 17) Alfonso F, Macaya C, Hernandez R, Banuelos C, Goicolea J, Iniguez A, et al. *Early and late results of percutaneous mitral valvuloplasty for mitral stenosis associated with mild mitral regurgitation. Am J Cardiol* 1993;71:1304-10.
- 18) Palacios IF, Block PC, Wilkins GT, Weyman A. *Follow-up of patients undergoing percutaneous mitral balloon valvotomy. Circulation* 1989;79:573-9.
- 19) Nobuyoshi M, Hamasaki N, Kimura T, Nosaka H, Yokoi H, Yasumoto H, et al. *Indications, complications, and short term clinical outcome of percutaneous transvenous mitral commissurotomy. Circulation* 1989;80:782-92.
- 20) Hernandez R, Macaya C, Banuelos C, Alfonso F, Goicolea J, Iniguez A, et al. *Predictors, mechanisms and outcome of severe mitral regurgitation complicating percutaneous mitral valvotomy with the Inoue balloon. Am J Cardiol* 1992;70:1169-74.
- 21) Herrmann HC, Lima JAC, Feldman T, Chisholm R, Isner J, O'Neill W (for the North American Inoue Balloon Investigators). *Mechanisms and outcomes of severe mitral regurgitation after Inoue balloon valvuloplasty. J Am Coll Cardiol* 1993;22:783-9.
- 22) Roth RB, Block PC, Palacios IF. *Predictors of increased mitral regurgitation after percutaneous mitral balloon valvotomy. Cathet Cardiovasc Diagn* 1990;20:17-21.
- 23) Vahanian A, Michel PL, Cormier B, Vitoux B, Michel X, Slama M, et al. *Results of percutaneous mitral commissurotomy in 200 patients. Am J Cardiol* 1989;63:847-52.
- 24) Chen CR, Cheng TO, Chen JY, Zhou YL, Mei J, Ma TZ. *Long term results of percutaneous mitral valvuloplasty with Inoue balloon catheter. Am J Cardiol* 1992;70:1445-8.