

급성 심근 경색증으로 인한 심인성 속 환자에서 대동맥 대위 박동 사용 후 발생한 급성 장간막 허혈증 및 장 협착증 1예

이현석 · 김태훈 · 조용범 · 문찬일 · 최재웅 · 송창섭

Bowel Stricture Caused by Acute Ischemic Colitis after Intraaortic Balloon Counterpulsation

Hyun Seog Lee, MD, Tae Hun Kim, MD, Yong Bum Cho, MD,
Chan Il Moon, MD, Jae Woong Choi, MD and Chang Seob Song, MD

Division of Cardiology, Department of Internal Medicine, Eulji General Hospital,
Eulji Medical College, Seoul, Korea

ABSTRACT

Intraaortic balloon counterpulsation (IAB) has been shown to prolong survival in the critically ill cardiac patients. Originally developed for use in the patients with cardiogenic shock, the indications have been expanded. But despite technical advances, the complication rate associated with IAB remains high. The most commonly reported complications include damage to the femoral artery and distal embolization. Other reported major complications are balloon rupture, limb loss, bleeding, systemic infection and bowel infarction. We report a patient complicated by ischemic colitis causing stenosis and intestinal obstruction after IAB insertion. (**Korean Circulation J 1999;29(12):1373-1377**)

KEY WORDS : Intraaortic balloon counterpulsation · Ischemic colitis · Intestinal obstruction.

서 론

가

³⁾

(IAB)

⁴⁾⁹⁾

¹⁾²⁾ IAB

IAB

⁵⁾ 가

: 1999 9 7

: 1999 11 18

: , 139 - 231 1 2801

: (02) 970 - 8203 · : (02) 970 - 8803

E - mail : cjw1108@eulji.or.kr

⁶⁾

0.019% 가 5) 36.8
가 . IAB . 2
2
IAB X -
(Fig. 1)
가 (Fig 2).

증 례

: , 48 .
: .
: 48
1 1 5
가 30
: 1 25 .
가 : .
: 80/50 mmHg 96
/min 18 /min 36.5 .

:
12000/mm³ 14.6 mg/dL 44%
176000/mm³ .
CPK 93 IU/L LDH 317
IU/L Troponin T 0.1 ng/L .
: 12
V1 V6 ST II, III,
aVF ST .
: X -
(EF=38%)
:
Seldinger IAB
Nir
(3.0×24 mm)
. 24
100/60 mmHg 72 /min 12 /min

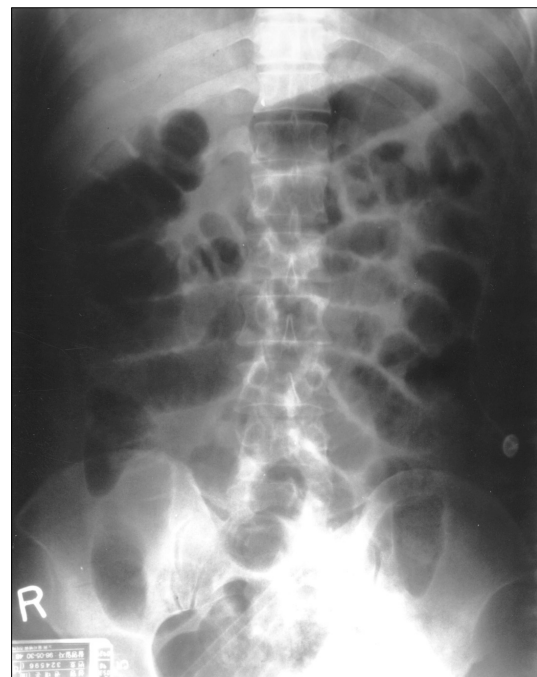

Fig. 1. Abdominal simple film reveals paralytic ileus.

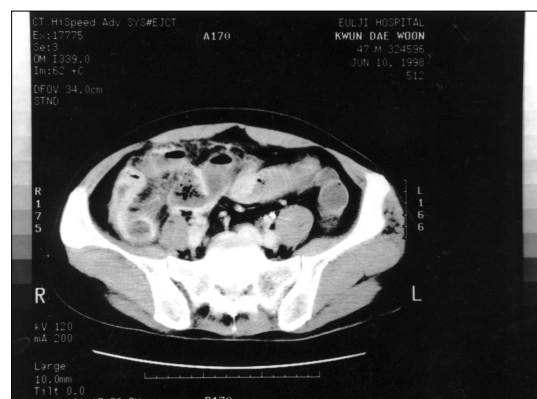

Fig. 2. Abdominal CT shows inflammatory process in the distal ileum.

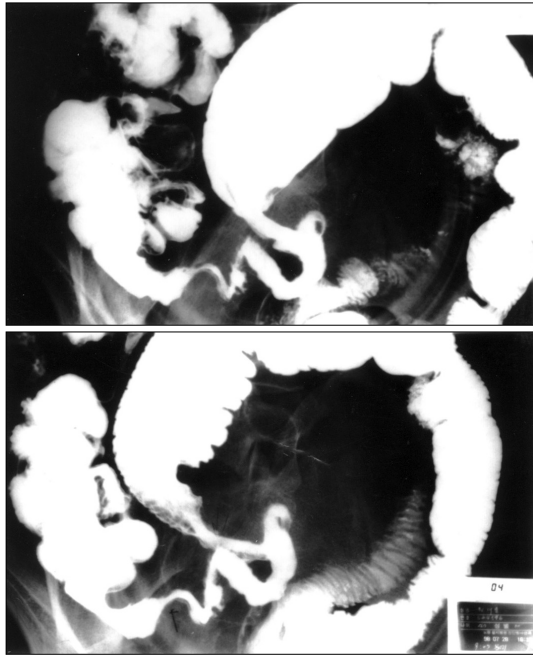


Fig. 3. Small bowel series shows a focal segmental narrowing in the distal ileum.

가

가 10

00/mm³(85%, 7.3%, 269

9.8 g/dL 29.5% 421

000/mm³

25

30 가 5)10)12) 가

(Fig. 3)

가 가 41

2

고 안

IAB Mouloupoulos 7) 가

Kantrowitz 8) IAB , 가

4)9) 가 가

IAB 가

3) IAB

12 42% . IAB

20%

4)5)10)11) 가

IAB IAB가

4)6)

4 - 6)10)12)

12)13)

14)

70 92%

가
 14)16)
 가 16)
 19)20)
 IAB
 IAB
 가
 50% 25% 25% 5%
 , 가 가
 17) Karen
 IAB 가
 X -
 18) 가
 22)
 IAB
 100/60 mmHg
 가
 가
 CT MRI
 20)
 가 21)
 가 가

중심 단어 :

REFERENCES

- 1) McCabe JC, Abel RM, Subramarian VA, Gay WA. *Complications of intraaortic balloon insertion and counterpulsation. Circulation* 1978;57:769-73.
- 2) Beckman CB, Geha AS, Hammond GL, Bane A. *Results and complication of intraaortic balloon counterpulsation. Am Thoracic Surg* 1977;24:550-9.
- 3) Dunkman WB, Leinbach RC, Buckley MJ, Mundth ED, Kantrowitz AR, Austen WG, *et al. Clinical and hemodynamic results of intraaortic balloon pumping and surgery for cardiogenic shock. Circulation* 1972;46:465.
- 4) Lefemine AA, Kosowsky B, Madaff I, Black H, Lewis M. *Results and complication of intraaortic balloon pumping in surgical & medical patients. Am J Cardiology* 1977;40:416-20.
- 5) Eltechaninoff H, Dimas AP, Whitlow PL. *Complication associated with percutaneous placement and use of intra-aortic balloon counterpulsation. Am J Cardiology* 1993; 71: 318-32.
- 6) Bregman D, Niclols AB, Weiss MB, Power ER, Martin EC, Casarella WJ. *Percutaneous intraaortic balloon insertion. Am J Cardiology* 1980;46:261-4.
- 7) Mouloupoulos SD, Topaz S, Eng BS, Kolff WJ. *Diastolic balloon pumping (with carbon dioxide) in the aorta-A mechanical assistance to the failing circulation. Am J Cardiol* 1962;63:669.
- 8) Kantrowitz A, Tjonneland S, Freed PS, Phillips SJ, Butner An, Sjerman JL. *Initial clinical experience with intraaortic balloon pumping in cardiogenic shock. JAMA* 1968;203:113.
- 9) Buckley MJ, Craver JM, Gold HK *et al. Intra-aortic*

- balloon pump assist for Cardiogenic shock after cardiopulmonary Bypass. *Circulation* 1973;46, 47 (Supp. III):90.
- 10) Barnett MG, Swartz MT, Peterson GJ, Naunheim KS, Pennington G, Baca KJ, et al. Vascular complications from intraaortic balloon: Risk analysis. *J Vasc Surg* 1994; 19:81-9.
 - 11) Isner JM, Cohen SR, Virmani R, et al. Complications of the intraaortic balloon counterpulsation device: Clinical and morphologic observations in 45 necropsy patients. *Am J Cardiol* 1980;45:260.
 - 12) Patel JJ, et al. Prospective evaluation of complications associated with percutaneous intraaortic balloon counterpulsation. *Am J Cardiol* 1995;76 (Dec 1):1205-7.
 - 13) Nash IS, Lorell BH, Fishman RF, Baim DS, Donahue C, Diver DJ. A new technique for sheathless percutaneous intra-aortic balloon catheter insertion. *Cathet Cardio-vasc Diagn* 1991;23:57-60.
 - 14) Pace PD, Tilney NL, Lesch M, Couch NP. Peripheral arterial complications of intraaortic balloon counterpulsation. *Surgery* 1977;82:685-8.
 - 15) Taylor LM, Moneta GL. Intestinal ischemia, basic data underlying clinical decision making in vascular surgery, Edited by Porter JM and Taylor LM, Quality medical publishing, Inc St Louis Missouri;1994. p.7-110.
 - 16) Clavien PA, Muller C, Harder F. Treatment of mesenteric infarction. *Br J Surg* 1987;74:500.
 - 17) Stoney RJ, Cunningham CG. Acute mesenteric ischemia. *Surgery* 1993;114:489.
 - 18) Karen B Karlson, Eric C. Martin, David Bregman, Ellioff I. Fankuchen, William J. Casarella: Superior Mesenteric artery obstruction by Intraaortic counterpulsation Balloon stimulating Embolism. *Cardiovascular Intervent Radiol* 1981;4:236-8.
 - 19) Boley SJ, Sprayregen S, Siegelman SS, et al. Initial results from an aggressive roentgenological and surgical approach to acute mesenteric ischemia. *Surgery* 1977; 82:848.
 - 20) Kim YW, Yoon BH, Park HY, Chun SH. Surgical results of acute mesenteric artery embolism. *The Journal of the Korean Vascular Surgery Society* 1995;11:291-8.
 - 21) Fuentes FT, Muerza GS, Belda AE, et al. Successful intraarterial fragmentation and urokinase therapy in superior mesenteric artery embolisms. *Surgery* 1995; 117:712.
 - 22) Longo WE, Ballantyne GH, Gusberg RJ. Ischemic colitis: Patterns and prognosis. *Dis Colon Rectum* 1992; 35:726-30.
 - 23) Landrenau RJ, Fry WJ. The right colon as a target organ of non occlusive mesenteric ischemia. *Arch Surg* 1990; 125:591-4.