

Hemophilus Paraphrophilus에 의한 감염성 심내막염 1예

유경훈¹ · 김상헌¹ · 최희정¹ · 오명돈¹ · 손대원¹ · 김의종² · 최윤식¹ · 최강원¹

A Case of Hemophilus Paraphrophilus Endocarditis with Cerebral Embolism and Hemorrhage

Kyong-Hoon You, MD¹, Sang-Hun Kim, MD¹, Hee-Jung Choi, MD¹,
Myoung-Don Oh, MD¹, Dae-Won Sohn, MD¹, Eui-Chong Kim, MD²,
Yun-Shik Choi, MD¹ and Kang-Won Choe, MD¹¹Department of Internal Medicine and ²Clinical Pathology, College of Medicine,
Seoul National University, Seoul, Korea

ABSTRACT

Infective endocarditis by Hemophilus species is very rare ; there are only 22 reported-cases of Hemophilus paraphrophilus endocarditis. We report a case of Hemophilus paraphrophilus endocarditis in a middle-aged woman with cerebral embolism and hemorrhage. (Korean Circulation J 1998;28(4):642-646)

KEY WORDS : Hemophilus paraphrophilus · Infective endocarditis.

서론		H. paraphrophilus		B. Coll - Vincent	
		1994		22	
가		. ¹⁾²⁾ H. paraphrophilus			
5 10%					
Hemophilus spe -		Cardiobacterium hominis			
cies, Actinobacillus actinomycetemcomitance, Ca -		3		, ³⁻⁵⁾ H.	
rdiobacterium hominis, Eikenella corrodens, Kin -		paraphrophilus		가	
gella kingae가		HACEK			
Hemophilus		증례			
0.5	1%	¹⁾ Hemophilus parap -			
: 1997 9 22					
: 1998 4 27		50		가 10	
: , 110 - 744		28		70	
: (02) 760 - 3889 ·		가			
: (02) 762 - 9662					
E - mail : ykhmed@chollian.net				40	

1000 , 152 /mm³(92%,
5%, 3%) ,

10
7

orthopnea . BACTEC 9240(Backtron Dickinson, USA)
11 (Standard 10 Aerobic/F bottle)
5
7 thioglycollate broth()
(blind culture)
, MacConkey enriched chocolate agar
110 mmHg, 37 , 5% CO
70 mmHg, 22 , 64 , 18 enriched chocolate agar
37.6 .

maxillary , catalase , indole
tenderness가 Roth's spot , oxidase , ONPG . VITEK Sys -
tem(Bio - Merieux, USA) NHI card *H.*
paraphrophilus(code No 25774) , X
factor V factor
Murphy's sign *H. paraphrophilus* . -
, Janeway lactamase .
lesion Osler's node, splinter hemorrhage 10 ceftriaxone . 39.5
6
37 . 15

6100/mm³(84%, 11%,
3%, 1%) 9.5 g/dl,
27.7%, 137,000/mm³ . (Fig. 2).
Na 127 mEq/L, K 3.9 mEq/L, Cl 100 mEq/L .
106 mg/dl, 6.5 g/dl,
2.5 g/dl, 1.0 mg/dl, AST/ALT . 23
28/14 U/L .
Erosive gastritis가 .

32
vegetation .
X - ray 가 . 32
2900/mm³(63%, 22%,
(12 cm) . 12.6%, 1.9%, 0.5%), 8.7
5 100 g/dl, 122,000/mm³ , 46
(20%, 29%), 1000 , 1300/mm³(23%, 45%,
pH 7.6, 1.5 g/dl, 140 mg/dl, LDH 24 U/L, 32%) . Ceftriaxone
Amylase 17 U/dl . 9 , 35
(Fig. 1), 2000/

mm³(33.5%, 51.3%, 13.9%,
0.2%, 1.1%) , coumadin

4

(Fig. 3).

고 안

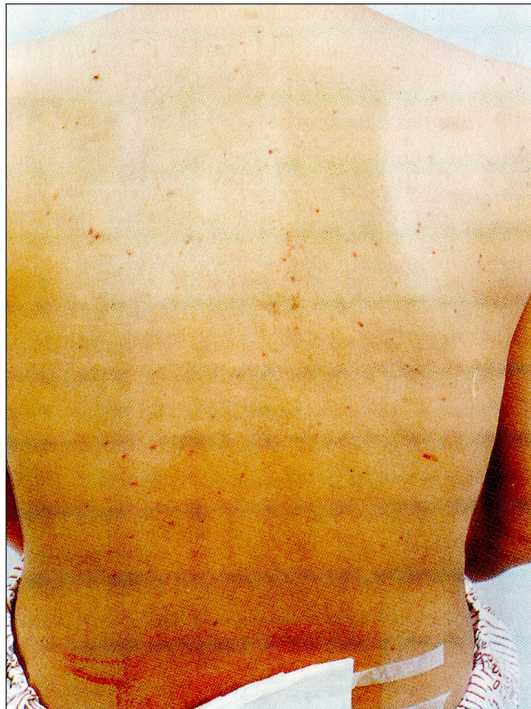


Fig. 1. Multiple petechiae on the back on the 9th hospital day.

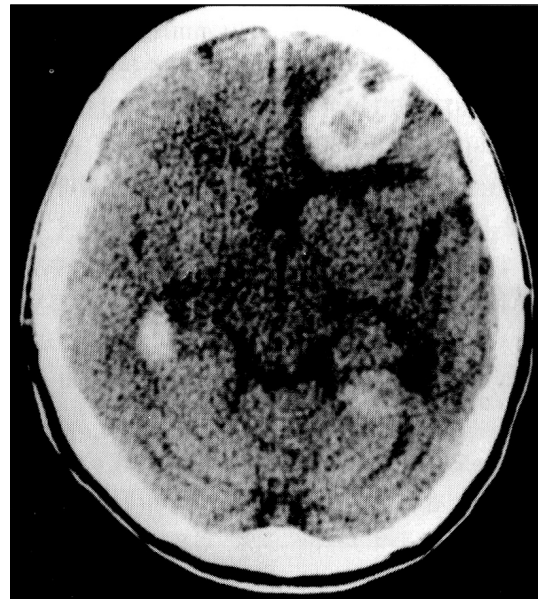


Fig. 2. Brain CT taken on the 15th hospital day shows multiple hemorrhagic infarctions of brain.

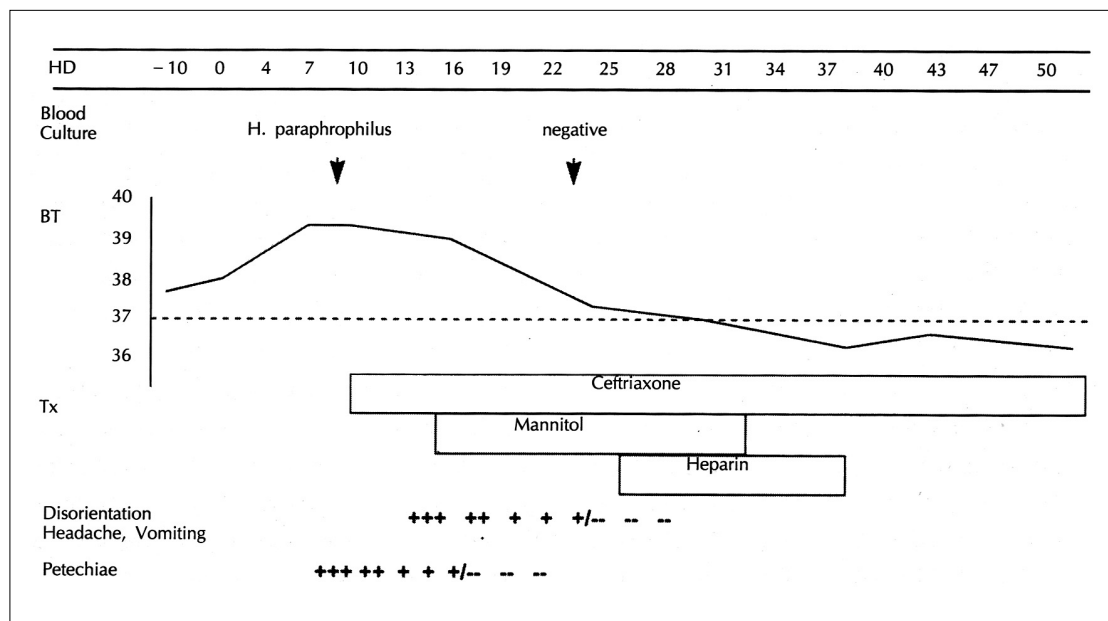


Fig. 3. Clinical course. HD : hospital day BT : body temperature Tx : treatment

가

coagulase - negative Sta -

phylococcus

¹²⁾ Geraci 5

4 가 ¹⁾

⁶⁾

HACEK 18 가

vegetation

⁷⁾ He -

mophilus 0.5 1%

⁸⁾ H. aphrophilus, H. parainfluenzae, H. influenzae, H. paraphrophilus

Hemophilus 가 212 21% ¹³⁾

coccobacilli 5%

⁸⁾

¹⁴⁾ Valtonen 20%

¹⁵⁾ Parker

Hemophilus 66

가

X factor(hemin) V factor(nicotina -

mide adenine dinucleotide)

⁹⁾ 가

V factor 가

가

가 X V factor

가

²⁾

chocolate agar plate

H. paraphrophilus

Hemophilus paraphrophilus 1968 Zinneman

¹⁰⁾ Hemophilus

15

17

V fator (10%) 가

가 Hemophilus

H. paraphrophilus

ampicillin Goseph 5

Silva¹¹⁾ mitral valve prolapse

ampicillin

Hammond H. paraphroph - ¹⁾

Coll - Vinent

H. paraphrophilus

가 - lactamase
 2) HACEK ampicillin amin -
 oglycoside ceftriaxone
 17) ceftriaxone

요 약

H. paraphrophilus

REFERENCES

- 1) Geraci JE, Wilkowske CJ, Wilson WR, Washington JA. *Haemophilus Endocarditis: report of 14 patients. Mayo Clin Proc* 1977;52:209-15.
- 2) Coll-Vinent B, Suris X, Lopez-Soto A, Miro JM, Coca A. *Haemophilus paraphrophilus Endocarditis: case and review. Clinical Infectious Disease* 1995;20:1381-3.
- 3) Myoung SJ, Lee CW, Kim EO, Park SW, Song JH, Lee JO, et al. *A case of bacterial endocarditis by Actinobacillus actinomycetemcomitans 16 months after treatment of Cardiobacterium hominis bacterial endocarditis. Korean J Med* 1994;46:422-6.
- 4) Kim NK, Kim KS, Lee WK, Park HS. *A case of subacute bacterial endocarditis caused by Cardiobacterium hominis. Korean J Clin Pathol* 1994;14:325-32.
- 5) Yoo SM, Peck KR, Kim SM, Oh MD, Park YB, Chae KW. *Infective endocarditis due to Cardiobacterium hominis. Korean J Med* 1995;48:388-93.
- 6) Karchmer AW. *Infective endocarditis. In: Braunwald E. Heart Disease. 5th ed. Philadelphia, WB Saunders Co; 1997. p.1077.*
- 7) Karchmer AW. *Infective endocarditis. In: Braunwald E. Heart Disease. 5th ed. Philadelphia, WB Saunders Co; 1997. p.1081.*
- 8) Weinstein L, Rubin RH. *Infective endocarditis 1973. Prog Cardiovasc Dis* 1973;16:239-74.
- 9) Kilian M. *Haemophilus. In: Balows A, Hausler WJ Jr, Herrmann KL, Isenberg HD, Shadomy HJ. Manual of Clinical Microbiology. 5th ed. Washington DC: American Society for Microbiology;1991. p463-70.*
- 10) Zinneman K, Rogers KB, Frazer J, Boyce MH. *A new V-dependent Haemophilus species preferring increased CO₂ tension for growth and named Haemophilus paraphrophilus. Pathol Bacteriol* 1968;96:413-9.
- 11) de Silva M, Rubin SJ, Lyons RW, Liss JP, Rotation ES. *Haemophilus paraphrophilus endocarditis in a prolapsed mitral valve. Am J Clin Pathol* 1976;66:922-6.
- 12) Hammond GW, Richardson H, Lian CJ. *Two Cases of Hemophilus Endocarditis of Prolapsed Mitral Valves-Hemophilus paraphrophilus or parainfluenzae? Am J Med* 1978;65:537-41.
- 13) Hart RG, Foster JW, Luther MF, Kanter MC. *Stroke in Infective Endocarditis. Stroke* 1990;21:695-700.
- 14) Hart RG, Kagan-Hallet MC, Joerns SE. *Mechanisms of Intracranial hemorrhage in infective endocarritis. Stroke* 1987;18:1048-56.
- 15) Valtonen V, Kuikka A, Syrjanen J. *Thromboembolic complications in bacteraemic infections. Eur Heart J* 1993; 14 Suppl K:20-3.
- 16) Parker SW, Apicella MA, Fuller CM. *Haemophilus Endocarditis: Two patients with complications. Arch Intern Med* 1983;143:48-51.
- 17) Wilson WR, Kachmer AW, Dajani AS. *Antibiotic treatment of adults with infective endocarditis due to streptococci, enterococci, staphylococci, and HACEK microorganism. JAMA* 1995;274:1706-13.