

Terfenadine과 Ketoconazole 병용투여에 의해 유발된 Torsade de Pointes 1예

오석규 · 국 향 · 임수빈 · 정진원 · 박양규 · 박옥규

= Abstract =

A Case of Torsade de Pointes after Treatment with Terfenadine and Ketoconazole

Seok-Kyu Oh, M.D., Hiang Kuk, M.D., Su-Bin Lim, M.D.,
Jin-Won Jeong, M.D., Yang-Kyu Park, M.D., Ock-Kyu Park, M.D.

Department of Internal Medicine, Wonkwang University School of Medicine, Iksan, Korea

Torsade de pointes(TdP) is a form of polymorphic ventricular tachycardia that is associated with prolongation of the QT interval. Although it occurs in many clinical settings, torsade de pointes is most commonly caused by drugs.

The second generation antihistamines, including terfenadine and astemizole, have little sedation or other adverse effects on the CNS. They have been used widely to treat various allergic diseases, but it has been reported that overdoses or combinations with antifungal agents or macrolide antibiotics may lead to TdP. We report a case of TdP that occurred during combination therapy of terfenadine and ketoconazole.

KEY WORDS : Torsade de pointes · Terfenadine · Ketoconazole.

서 론

Torsade de pointes(TdP) is a form of polymorphic ventricular tachycardia that is associated with prolongation of the QT interval. Although it occurs in many clinical settings, torsade de pointes is most commonly caused by drugs. The second generation antihistamines, including terfenadine and astemizole, have little sedation or other adverse effects on the CNS. They have been used widely to treat various allergic diseases, but it has been reported that overdoses or combinations with antifungal agents or macrolide antibiotics may lead to TdP. We report a case of TdP that occurred during combination therapy of terfenadine and ketoconazole.

교신저자 : , 570 - 711
) (0653) 850 - 1055,
) (0653) 52 - 8480

344 - 2

: 61

14

QT (820msec), Torsade de pointes(TdP)가
 가 TdP가 QT 620msec (Fig. 2).
 가 40 (bigeminy of premature ventricular
 beats)(Fig. 3) 2 4 (salvos
 of 2 to 4 consecutive beats)(Fig. 4) 2
 가 11).

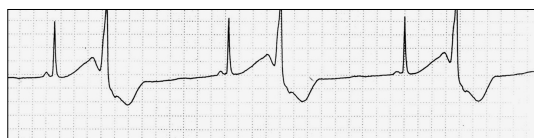

Fig. 3. Bigeminy of premature ventricular beats.

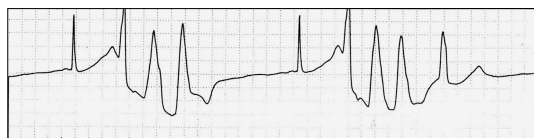


Fig. 4. Salvos of 2 to 4 consecutive beats.

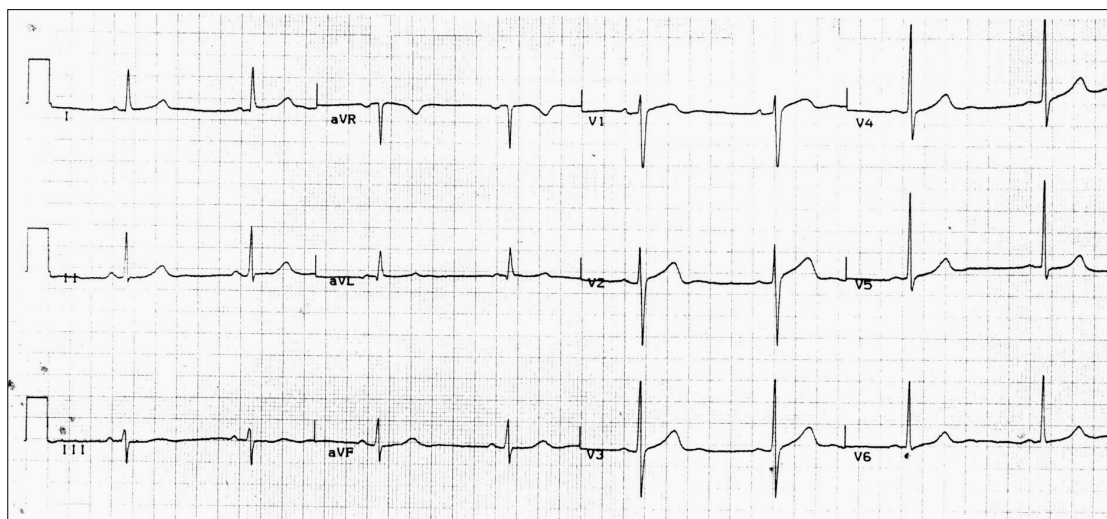


Fig. 5. An electrocardiogram taken on the 5th hospital day shows normalization of QT interval(460 msec).

가 QT 5
 51 , QT 460msec
 (Fig. 5), ST
 6
 QT 10 , 1
 57 , QT 420msec
 고 찰
 TdP long QT , (,)
 (class IA, IC, III)
 (, marolide) QT
 가 가 1-8).
 TdP
 - (early afterde-
 polarization, EAD) TdP
 . EAD
 (dispersion) (triggered

activity) (reentry) TdP clarithromycin, cimetidine, prepuclid
^{9,10)} TdP
 Terfenadine, astemizole, loratadine , ¹⁻⁸⁾
 2 TdP
 . Terfenadine butyrophenone .
 TdP가 MgSO₄
 가 ^{6,16)} Na⁺ - K⁺
 60mg 1 2
 가 , 1 2 ATPase K⁺
 , 8.5 , QT
 cytochrome P - 450 TdP
 , 24 48 60% , ^{16,17)} MgSO₄
 40% ^{12,13)} TdP
 Terfenadine astemizole , TdP가
 , ketoconazole
 erythromycin, clarithromycin
 macrolides , QT . MgSO₄
 TdP MgSO₄ 2g 2 3
¹⁻⁸⁾ Terfenadine 2 4mg/
 K⁺ , MgSO₄ 2g 6
¹⁴⁾ , 8mg/ 가 . 3
 MgSO₄ 2g 가 ,
 ketoconazole cytochrome P - 450
 terfenadine terfena -
 dine 가 QT 500msec
 가 ¹⁵⁾
 terfenadine ¹⁶⁾ TdP QT
 , terfenadine isoproterenol
 ketoconazole 가 TdP
 4 , isoproterenol
 ketoconazole 90 , 100 120
 terfenadine terfenadine ^{16,17)}
 가 TdP가 가
 .
 terfenadine ketoconazole
 , (TdP) terfenadine
 가 TdP 가 QT
 . terfenadine ketoconazole
 terfenadine cytochrome P -
 450 erythromycin, .

요 약

terfenadine
 , terfenadine ke -
 toconazole
 QT
 Torsade de pointes 1
 , terfenadine
 ,
 QT ,
 ,
 , TdP
 TdP MgSO₄

References

- 1) Davies AJ, Harindra M, Mc Ewan A, Ghose RR : *Cardiotoxic effect with convulsion in terfenadine overdose. Br Med J* 298 : 198-235, 1989
- 2) Monahan BP, Ferguson CL, Killeavy ES, Lloyd BK, Troy J, Cantilena LR : *Torsade de pointes occurring in association with terfenadine use. JAMA* 264 : 2788-2790, 1990
- 3) Zimmermann M, Duruz H, Juinand O, Broccard O, Lecy P, Latis D, Bloch A : *Torsade de pointes after treatment with terfenadine and ketoconazole. Eur Heart J* 13 : 1002-1003, 1992
- 4) Koh KK, Rim MS, Yoon J, Kim SS : *Torsade de pointes induced by terfenadine in a patient with long QT syndrome. J Electrocardio* 27 : 343-346, 1994
- 5) 이철환 · 두영철 · 송재관 · 김재중 · 박성욱 · 박승정 · 이종구 : *Astemizole에 의해 유발된 Torsade de Pointes 1예. 대한내과학회지* 43 : 701-705, 1992
- 6) 이철환 · 김재중 · 송재관 · 박성욱 · 박승정 · 이종구 : *Torsade de pointes의 치료에 있어 MgSO₄의 효과. 순환기학회지* 24 : 617-623, 1994
- 7) 윤성민 · 원준연 · 김영대 · 조용호 · 허성호 · 이두하 · 이상민 · 정태호 : *특발성 Long QT 증후군 1예. 순환기학회지* 27 : 658-665, 1997
- 8) 오인택 · 유규형 · 홍경표 · 임종윤 · 고영박 · 이영 : *Torsade de pointes의 임상관찰. 순환기학회지* 19 : 716-725, 1989
- 9) Surawicz B, FACC : *Electrophysiologic substrate of Torsade de pointes : Dispersion of repolarization or early afterdepolarizations?. J Am Coll Cardiol* 14 : 172-184, 1989
- 10) Roden DM : *Early after-depolarizations and torsade de pointes : Implications for the control of cardiac arrhythmias by prolonging repolarization. Eur Heart J* 14 (Suppl. H) : 56, 1993
- 11) Locati EH, Pierre MB, Dejode P, Cauchemez B, Coumel P, FACC : *Spontaneous sequences of onset of torsade de pointes in patients with acquired prolonged repolarization : Quantitative analysis of Holter recordings. J Am Coll Cardiol* 25 : 1564-1575, 1995
- 12) YLitvak K, Shannon EP, Welsh OH, Peterson J, Bedford LE, Schnell NC, Bollinger LA, Brady LK, Dewey DR, Fong PA, Melton GS, O'Rourke A, Kester L, Jiegler KM : *Antihistamine drugs. AHFS Drug Information* 97 : 1-38, 1997
- 13) Ambre JJ, Bennett DR, Cranston JW, Dickinson BD, McCann MA, Pang DC, Proudfit CM, Rapoza NP, Seidenfeld J, Smith SJ : *Histamine and Antihistamines. AMA Drug Evaluations* 7 : 1925-1939, 1995
- 14) Crumb WJ, Wible B, Arnold DJ, Payne JP, Brown AM : *Blockade of multiple human cardiac potassium currents by the antihistamine terfenadine : Possible mechanism for terfenadine-associated cardiotoxicity. Molecular Pharmacol* 47 : 181-190, 1995
- 15) Brown MW, Maldonado AL, Meredith CG, Speeg KV : *Effect of ketoconazole on hepatic oxidative drug metabolism. Clin Pharmacol Ther* 37 : 290-297, 1985
- 16) Banai S, Tzivoni D : *Drug therapy for torsade de pointes. J Cardiovasc Electrophysiol* 4 : 206-210, 1993
- 17) Tzivoni D, Banai S, Schuger C, Benhorin J, Keren A, Gottlieb S, Stern S : *Treatment of torsade de pointes with magnesium sulfate. Circulation* 77 : 392-397, 1988