

## 약물 정주 경력이 없고 심장의 구조적 이상이 없는 사람에게서 발생한 삼첨판 심내막염 1예

가

오은숙 · 노상영 · 김범준 · 이명아 · 유기동  
박지원 · 최정현 · 정옥성 · 신완식 · 홍순조

### A Case of Tricuspid Valve Endocarditis with Vegetation in a Non-Drug Addict without Underlying Cardiac Disease

Eun Sook Oh, MD, Sang Young Rho, MD, Bum Joon Kim, MD, Myoung A Lee, MD,  
Ki Dong Yoo, MD, Ji Won Park, MD, Chung Hyun Choi, MD,  
Wook Sung Chung, MD, Wan Sik Sin, MD and Soon Jo Hong, MD

Department of Internal Medicine, Catholic University Medical College, Seoul, Korea

#### ABSTRACT

Tricuspid valve endocarditis accounts for 5% to 10% of cases of infective endocarditis. It commonly occurs in intravenous drug abusers, intravenous catheters, alcoholism, immune deficiency and genital sepsis. But right sided infective endocarditis without predisposing factor is very rare. *S. aureus* is the usual pathogen. We experienced a case of tricuspid valve endocarditis in a 32 year old female with vegetation in a non drug addict without underlying cardiac disease. The vegetation on the septal cusp of tricuspid valve and tricuspid regurgitation were found by TTE & TEE. *S. aureus* was identified in 4 bottles of blood cultures. The diagnosis was delayed because the cardiac manifestations of the disease were subtle, and pleuropulmonary manifestations predominant. So we report a case of tricuspid valve endocarditis in a non drug addict without underlying cardiac disease with a review of literature. (**Korean Circulation J 1998;28(8):1372-1377**)

**KEY WORD :** Tricuspid valve endocarditis.

#### 서 론

5~10%

: 1998 8 6

: 1998 9 25

: , 137 - 040

505

가

: (02) 590 - 1422 · : (02) 599 - 3589

1997 7 가 , mEq/L, Chloride 101 mEq/L , Calcium 7.2 mg/dl, phosphorus 2.2 mg/dL . Total protein 6.19 gm, albumin 2.95 gm, AST 36 I.U/L, ALT 70 I.U/L, Alkaline - Phosphatase 282 I.U/L, r - GTP 55 I.U/L , Total cholesterol 95 mg/dl, trigly - ceride 66 mg/dl, HDL16 mg/dL L - DH 383 I.U/L, CPK 24 I.U/L .

증 례

병력 및 이학적 소견

32 10 가

90/60 mmHg, 100

24 , 38.4 .

가 pH 7.483, PCO<sub>2</sub> 36.3 mmHg, PaO<sub>2</sub> 72.6 mmHg , Bicarbonate 26.3 mmol /L 95.3% .

Janeway lesion , Splinter hemorrhage ) 가 ( Fig. 1).

임상경과

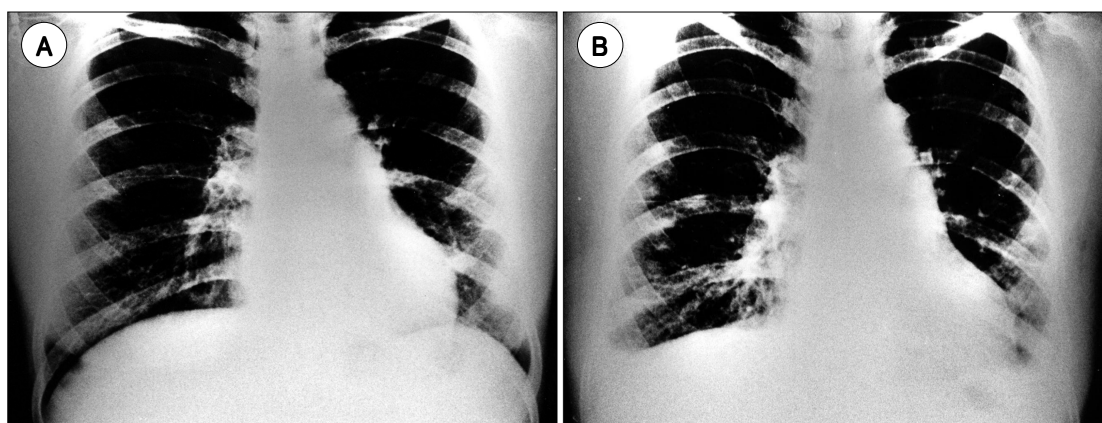
검사소견

9.4 gm/dL, 26.8% , 20,500/mm<sup>3</sup>( 93.4%, 4.1%, 2.3%) , 161,000/mm<sup>3</sup> .

FBS 106 mg/dL, BUN 5.6 mg/dl, Creatinin 0.86 mg/dl , Na 136 mEq/L, K 3.5

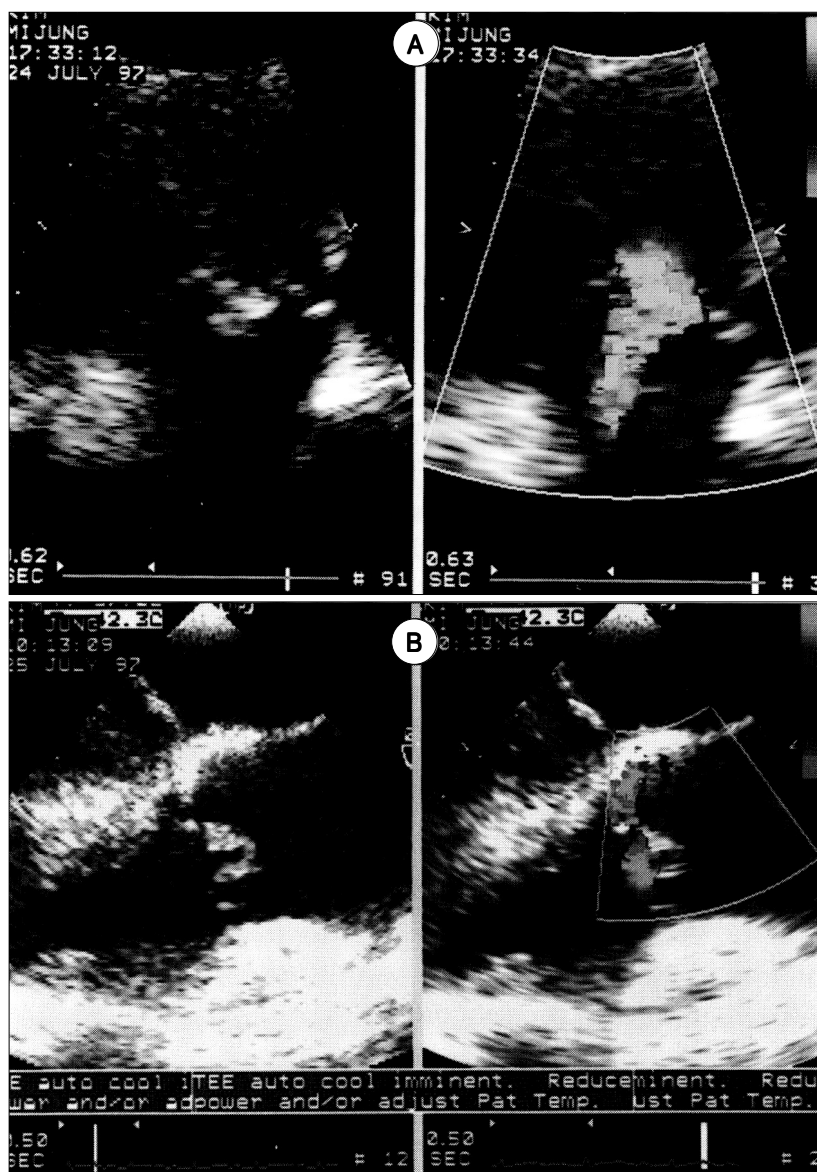
Roxithromycin , 3 Ceft - rioxone, Gentamicin 가 Methicillin 4

가 grade 2 , 52%



**Fig. 1.** A : Chest PA shows mild irregular increased opacities involving at base of the both lower lobe, especially left lower lobe on admission. B : On Hospital day 5, Pleural effusion was developed.

가 가 13 mm/hr, CRP 164 mg/L , Vancomy -  
 mm x 11 mm . cin, Amikacin, Metronidazole , 11  
 5 15 . 15  
 31,000/mm<sup>3</sup>( 97%,  
 3%), 2,900/mm<sup>3</sup> , 3.68 gm/  
 dL, 20 mg/dL, LDH 1,811 U/L, Chloride 104 chordae (Fig. 2). 17  
 mEq/L , Cefazolin,  
 , AFB Gentamicin .  
 smear ADA, AFB PCR , 20 Levofloxacin .  
 8 , 104 , Naxen



**Fig. 2.** A : Transthoracic two dimensional echocardiography on hopital day 4. There were TR (Grade II) & suspicioius vegetation or prolapse with thicked tricuspid valve. B : Transesophageal echocardiography on hopital day 15. Large vegetations are attached to the septal cusp of the tricuspid valve. Chordae rupture was also seen.



2D M mode  
80~100%  
chordae  
5)15)  
16)  
4~6 Penicillin, Cephal -  
osporin Vancomycin  
aminoglycoside  
Methicillin  
illinase - resistant penicillin  
17)  
Ceftriaxone, Gentamicin 5  
Vancomycin, Amikacin 2 , Va -  
ncomycin 3 Van -  
comycin 10  
, AIDS  
13)  
11)  
xen 2  
23%  
16)  
14~24%  
9)  
Robbins  
1 cm

가 1 cm 30%  
2)12)  
가  
, CRP  
가 가  
6  
요 약  
, 2  
Methicilin -  
, Cephalosporin Van -  
comycin 가  
가  
중심 단어 :

## REFERENCES

- 1) Chan P, Oglly JD, Segal B. *Tricuspid valve endocarditis. Am Heart J* 1989;117:1140-6.
- 2) Toru Iwama, Satoshi Shigematsu, Kouichi Asami, Ichirou Kubo, Hidemana Kitazume, Sadao Tanabe, et al. *Tricuspid Valve endocarditis with large vegetations in a non-drug addict without underlying cardiac disease. Int Med* 1996;35:203-6.
- 3) Reisberg BE. *Infective endocarditis in the narcotic addict. Prog Cardiovasc Dis* 1979;22:193.
- 4) Andy JJ, Sheikh MU, Ali N, Barnes BO, Fox LM, Curry CL, et al. *Echocardiographic observations in opiate addicts with active infective endocarditis. Am J Cardiol* 1977;40:L17.
- 5) Roberts WC, Buchbinder NA. *Right-sided valvulus endocarditis. A clinicopathological study of twelve necropsy patients. Am Heart J* 1986;111:128-35.
- 6) Clifford CP, Eykyn SJ, Oakley CM. *Staphylococcal tricuspid valve endocarditis in patients with structurally normal hearts and no evidence of narcotic abuse. Q J Med* 1994;87:755-7.
- 7) Ioannis PP, Morris NK, Gary SM, Bernard LS, John JR. *Right heart endocarditis. Clinical and echocardiographic features. Am heart J*;1984. p.759-64.
- 8) Banks T, Fletcher R, Ali N. *Infective endocarditis In heroin addicts. Am J Med* 1973;55:444.
- 9) Robbins MJ, Soeiro R, Frishman WH, Strom JA. *Right sided valvular endocarditis: Etiology, diagnosis and an approach to therapy. Am Heart J* 1986;111:128-35.
- 10) Naidoo DP. *Right sided endocarditis in the non-drug addict. Postgrad Med J* 1993;69:615.
- 11) Ginzton LE, Siegel RJ, Criley JM. *Natural history of tricuspid valve endocarditis: A two-dimentional echocar-*

- diographic study. Am J Cardio 1982;49:1853.*
- 12) Michael JR, Robert WM, Frater RS, William HF, Joel AS. *Influence of vegetation size on clinical outcome of right-sided infective endocarditis. Am J Med 1986;80:165-71.*
  - 13) Pingkwan CJ, David O, Bernard S. *Tricuspid valve endocarditis Am Heart J;1989. p.1140-6.*
  - 14) O'Brien JT, Gieser EA. *Infective endocarditis and echocardiography. Am Heart J 1984;108:386-94.*
  - 15) Musewe NM, Hecht BM, Hesselein PS, Rose V, Willians WG. *Tricuspid valve endocarditis in two children with normal hearts: Diagnosis and therapy of an unusual clinical entity. J Paeds 1987;110:735-8.*
  - 16) Come PC, Kurland GS, Vine HS. *Two-dimensional echocardiography in differentiating right atrial and tricuspid valve mass lesions. Am J Cardio 1979;44:1207.*
  - 17) Ribera E, gomez-Jimmenez J, Cores E. *Effectiveness of cloxacillin with and without gentamicin in short-term therapy for right-sided Staphylococcus aureus endocarditis. A randomized, controlled trial. Ann Int Med 1996;123: 969-74.*