

대동맥판 협착증에서 정상 관동맥을 보인 심근경색증 1예

박창규 · 오동주 · 서홍석 · 이은미 · 김응주 · 이승진
안정천 · 송우혁 · 임도선 · 심완주 · 노영무

= Abstract =

A Case Report of Acute Myocardial Infarction in a Patient with Severe Aortic Stenosis and Normal Coronary Arteries

Chang Gyu Park, M.D., Dong Joo Oh, M.D., Hong Seog Seo, M.D.,
Yeong Joo Kim, M.D., Seong Jin Lee, M.D., Eun Mi Lee, M.D.,
Jung Chun Ahn, M.D., Woo Heuk Song, M.D., Do Sun Lim, M.D.,
Wan Joo Shim, M.D., Young Moo Ro, M.D.

Department of Internal Medicine, College of Medicine, Korea University, Seoul, Korea

The incidence of angina pectoris(AP) in patients with severe aortic stenosis(AS) and normal coronary arteries has been reported to be 30 to 40%. The pathophysiologic mechanism suggests marked decrease in coronary reserve with left ventricular hypertrophy secondary AS and mismatched oxygen demand-supply by valvular pressure gradient, but only 1 case of acute myocardial infarction(AMI) was reported in severe AS and normal coronary arteries as far as we are concerned. We report a case of AMI occurring in a patient with severe AS and left ventricular hypertrophy. A coronary angiogram excluded coronary obstruction and spasm as the cause of AMI in this patient.

KEY WORDS : Aortic stenosis · Normal coronary artery · Acute myocardial infarction.

서 론

2 가

30 40%

가 가

1)

가

4 5

2,3)

5).

153mg/dl, 110mg/dl, HDL - C 61mg/dl,
LDL - C 64mg/dl, Lp(a) 16.5mg/dl

X

중 려

: , 53 . , V₁, V₂ Q
: (97 4 9). V₁ V₃ 3mm ST
: 6 V₄ - V₆ T
12 40 (Fig. 1).
가 (12) CK 671 (MB
16.8) 가 LD 1344 가 LD₁
34% LD₂ 33.6% flipped
: .
가 : 30 (3 4 18mm, 22mm)
: .
100/60mmHg,
84 / , 36.5 45%
(sternal angle) 3/6 0.8cm²
87mmHg
5

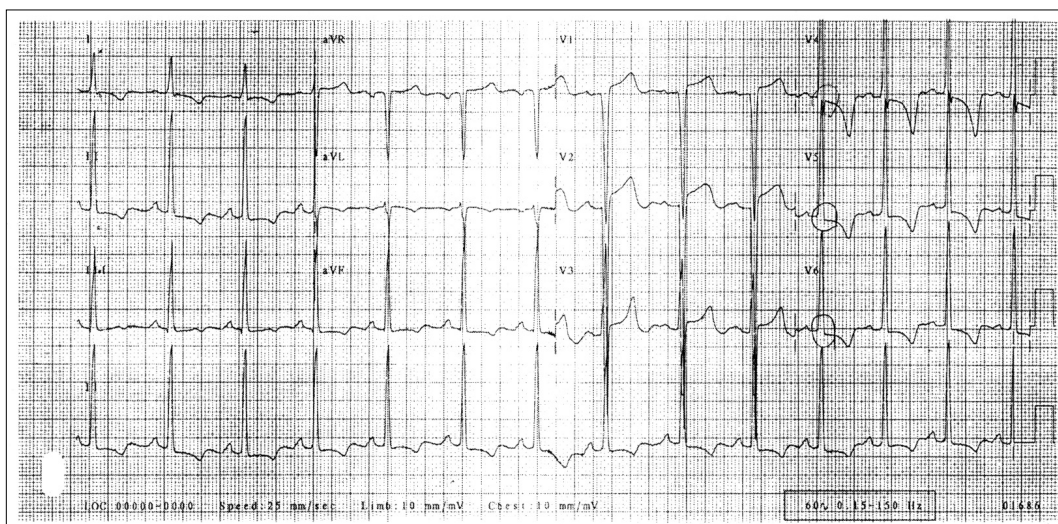


Fig. 1. ECG recorded on admission. The presence of Q wave and ST segment elevation (up to 4mm) in leads V₁, V₂ indicate acute anteroseptal wall myocardial infarction.

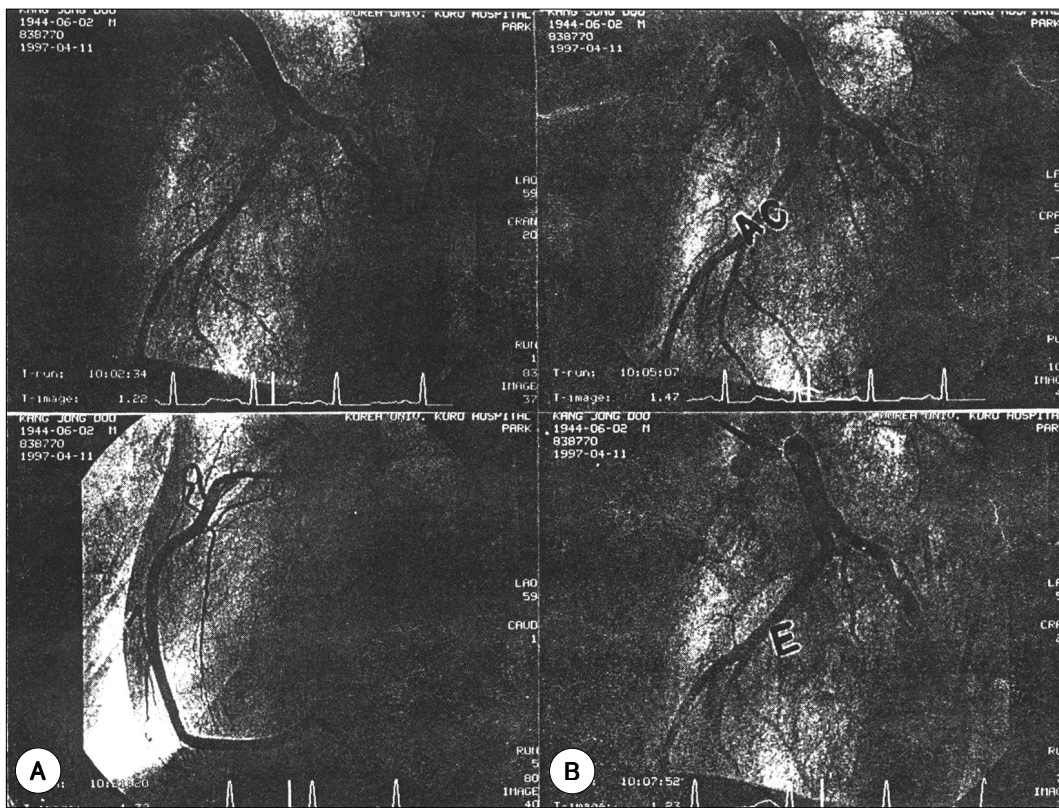


Fig. 2. Normal coronary angiogram of the left and right coronary (A) and no spasm after acetylcholine and ergonovine infusion into left coronary artery (B) during the acute phase of myocardial infarction(AC : acetylcholine, E : ergonovine).

coumadin

고 안

(20 μ g, 50 μ g) er -

gonovine(5 μ g, 10 μ g)

(Fig. 2).

6

, ACE

가(CK MB, LD 1)

가 48

13 ATS 21mm

3 coumadin

1 vine ergono -

65% 가

10

가 Jondeau ST

가

가

Jondeau 5)

(4 5)
가

Jondeau 53 가

가

5

가

(irregular) 가

가

가

Jondeau lead ST V₁ aVR Q

가 . Maraus 6)

가 . Smucker

7)

가 가

가

요 약

References

- 1) Hakki AH, Kimbiris D, Iskandrian AS, Segal BL, Mintz GS, Bemis CE : *Angina pectoris and coronary disease in patients with severe aortic valvular disease. Am Heart J* 100 : 441-449, 1980
- 2) Julius BK, Spillmann M, Vassalli G, Villari B, Eberli FR, Hess OM : *Angina pectoris in patients with aortic stenosis and normal coronary arteries. Circulation* 95 : 892-898, 1997
- 3) Lance G : *Why angina pectoris in aortic stenosis. Circulation* 95 : 790-792, 1997
- 4) Duke M, Eddy JR : *Aortic stenosis and transmural myocardial infarction without coronary artery disease, A case report and discussion. Angiology* 21 : 265-269, 1970
- 5) Jondeau G, Dubourg O, Partovian C, Dib JC, Lacombe P, Chikli F, Bourdarias JP : *Acute myocardial infarction in a patient with severe aortic stenosis and normal coronary arteries. Eur Heart J* 15 : 715-717, 1994
- 6) Marous ML, Doty DB, Hirataka LF, Weight CB, Eastbam CL : *Decreased coronary reserve, A mechanism for angina pectoris in patients with aortic stenosis and normal coronary arteries. N Engl J Med* 307 : 1362-367, 1982
- 7) Smucker ML, Tedesco CL, Manning SB, Owen RM, Feldman MD : *Demonstration of imbalance between coronary perfusion and excessive load as a mechanism of ischemia during stress in patients with aortic stenosis. Circulation* 78 : 573-582, 1988