

The effect of suture by absorbable material on corneal astigmatism after phacoemulsification

Jae Ho Yoo¹, Sang Joon Lee^{1,2}

¹Department of Ophthalmology, College of Medicine, Kosin University, Busan, Korea

²Institute for Medicine, College of Medicine, Kosin University, Busan, Korea

Objectives: To investigate the effect of absorbable suture on surgically-induced corneal astigmatism in 3.0-mm sclera tunnel cataract surgeries.

Methods: Medical records of patients who underwent phacoemulsification cataract surgery using a 3.0-mm sclera tunnel incision made by a single surgeon were reviewed. Uncorrected distant visual acuity, corneal astigmatism and surgically-induced astigmatism were measured in 56 patients' eyes that underwent sclera tunnel cataract surgery with absorbable sutures (sutured group) and in 23 patients' eyes without sutures (unsutured group). Uncorrected visual acuity, intraocular pressure, slit lamp examination, and automated keratometry were evaluated preoperatively and at 3 days, 2 weeks, 4 weeks, and 8 weeks after cataract operation.

Results: There were no significant differences in preoperative average uncorrected distant visual acuity of the two groups (sutured group: 0.79 ± 0.64 , unsutured group: 0.68 ± 0.72 , $P = 0.145$). Corneal astigmatism measured using keratometry in the sutured and unsutured group at postoperative day 3 were 2.27 ± 2.12 D versus 0.83 ± 0.55 D at ($P < 0.001$), a difference which had disappeared after 4 weeks. Surgically induced astigmatism using the Holladay and Vector methods showed similar outcomes, suggesting that the sutured group exhibited higher astigmatism compared with the unsutured group until 2 weeks post-surgery.


Conclusions: TPatients undergoing scleral tunnel cataract surgery with absorbable sutures have greater surgically induced astigmatism, especially in the early postoperative period, compared with those without sutures. However, this surgically induced astigmatism due to absorbable sutures in scleral tunnel cataract surgery is temporary and disappears at 4 weeks post-surgery.

Key Words: Cataract surgery, Scleral tunnel incision, Surgically induced astigmatism

According to a 2003 report of the American Society of Cataract and Refractive Surgery (ASCRS), more than half of the members have performed the clear corneal incision at the time of phacoemulsification and 92% of surgeons preferred sur-

gery with sutures.¹ This clear corneal incision is easier than the scleral tunnel incision and has fewer complications. Also, it induces less astigmatism and has the advantage of quick vision recovery.² However, this clear corneal incision has dis-

Corresponding Author: Sang Joon Lee, Department of Ophthalmology, College of Medicine, Kosin University, 262, Gamcheon-ro, Seo-gu, Busan 49267, Korea

 1-990-6140 Fax: +82-51-990-3026 E-mail: hhiatus@gmail.com

Received: Aug. 18, 2016
Revised: Nov. 03, 2016
Accepted: Dec. 14, 2016

Articles published in Kosin Medical Journal are open-access, distributed under the terms of the Creative Commons Attribution Non-Commercial License (<http://creativecommons.org/licenses/by-nc/4.0/>) which permits unrestricted non-commercial use, distribution, and reproduction in any medium, provided the original work is properly cited.

advantages such as instability of the initial wound after surgery, increased risks of wound leakage and infection, and increased loss of corneal endothelial cells.²⁻⁷ Therefore, some surgeons suture with 10-0 nylon, or prefer the scleral tunnel incision which can cover the incision site with a conjunctiva and the upper eyelid in order to correct for these weaknesses.

Surgically induced astigmatism varies based on the size and shape of the incision, the type and location of the incision, the presence of sutures and the type of suture. Although many surgeons prefer the clear corneal incision, some studies have reported that the scleral tunnel incision has less postoperative astigmatism than the clear corneal incision.⁸ When the scleral tunnel incision is sutured, astigmatism caused by the suture should be considered. Particularly, in underdeveloped countries with poor access to medical care where it is impossible to follow-up after cataract surgery, it is necessary to stitch the incision for endophthalmitis reduction, and stability of postoperative ocular hypotonia and wound healing. Therefore, the sclera should be stitched using absorbable suture, which does not require removal, and change in astigmatism due to surgery should be considered.

However, there have been many reports on the comparison of surgically induced astigmatism based on the anatomical location or size of the incision, or non-absorbable suture, but there has been no report on astigmatism change after stitching a 3 mm small scleral tunnel incision with ab-

sorbable suture.⁷⁻¹⁶ Therefore, for this study the authors compare surgery-induced astigmatism between sutureless scleral tunnel incision and scleral tunnel incision with absorbable suture.

MATERIALS AND METHODS

This study was conducted retrospectively with 78 people (79 eyes) who received cataract surgery from a single surgeon from November 2008 to January 2010. Subjects who had corneal disease or intraocular inflammatory disease, glaucoma, or a history of surgery which may affect the corneal astigmatism were excluded.

All of the surgeries were performed by a single surgeon with local anesthesia. First, subtenon or retrobulbar anesthesia was administered at a 1:1 ratio of 2% lidocaine hydrochloride and 0.5% bupivacaine hydrochloride. A 3.0 mm scleral tunnel incision at the 10:30 direction and 1.00 mm small incision at the 2 o'clock direction centered on the cornea with a keratotome were made. Then a continuous curvilinear capsulorhexis and local hydrodissection were performed. Phacoemulsification and cortical inhalation were performed with an ultrasonic emulsifier (Accurus®, Alcon, U.S.A). A posterior chamber foldable intraocular lens implant was inserted in the lens capsule by 3.0 mm scleral tunnel incision. After implantation of the intraocular lens, the viscoelastic materials remaining in the anterior and lens capsule were removed by irrigation-aspiration system. Then, the patients were classified

into two groups based on the incisional suture and patients were randomly selected for either suturing or stitching of the conjunctiva. If a one-time interrupted suture was performed for scleral tunnel incision with absorbable suture, then a stromal hydration was performed at the small incision site and the patient was classified in the suture group. And if the scleral tunnel incision was not sutured, but only the conjunctiva above it was stitched with non-absorbable suture (10-0 Nylon), the patient was classified in the nonsuture group.

In each group, the uncorrected visual acuity, corneal astigmatism and surgically induced astigmatism were measured preoperatively and at 3 days, 2 weeks, 4 weeks and 8 weeks after cataract surgery. Corneal astigmatism was measured with an automatic keratometry (KR-8800, Topcon, Japan) and the surgically induced astigmatism was analyzed using Holladay and Vector methods.

SPSS 18.0 for window (SPSS Inc.) was used for statistical analysis. t-test and Wilcoxon signed rank test were used to compare within the same group and Mann-Whitney U test was used to compare between different groups. If a p-value is < 0.05, it was considered statistically significant.

RESULTS

This study analyzed a total of 78 people (79 eyes), of which 29 were males and 49 were females. The mean age of participants was 66.5

± 10.8 years in the sutured group and 61.8 ± 14.0 in the unsutured group. LogMAR uncorrected visual acuity for the sutured group was measured as 0.79 ± 0.64 , 0.47 ± 0.44 , 0.40 ± 0.44 , 0.42 ± 0.47 , and 0.38 ± 0.54 at preoperation, 3 days, 2 weeks, 4 weeks and 8 weeks after surgery, respectively. For the unsutured group, it was measured as 0.68 ± 0.72 , 0.54 ± 0.74 , 0.48 ± 0.74 , 0.52 ± 0.73 , and 0.56 ± 0.80 at preoperation, 3 days, 2 weeks, 4 weeks and 8 weeks after surgery, respectively. There were significant vision differences over time after surgery within the same group, but there was no significant difference between both groups at the same time point (Table 1, Fig. 1A).

The mean corneal astigmatism in the suture group was measured as 0.83 ± 0.55 D, 2.27 ± 2.12 D, 1.36 ± 1.32 D, 1.13 ± 0.70 D, and 0.86 ± 0.50 D at preoperation, 3 days, 2 weeks, 4 weeks and 8 weeks after surgery, respectively, which showed significant difference in high surgically induced corneal astigmatism until 4 weeks after surgery compared to the preoperative measurement. However, at 8 weeks after surgery, the corneal astigmatism gradually decreased and there was no statistically significant difference compared to the one before surgery. For the unsutured group, the mean corneal astigmatism was measured as 1.11 ± 0.72 D, 1.36 ± 0.90 D, 1.33 ± 1.10 D, 1.12 ± 0.92 D, and 1.08 ± 0.75 D at preoperation, 3 days, 2 weeks, 4 weeks and 8 weeks after surgery, respectively. There was no significant difference when compared to the preoperative corneal as-

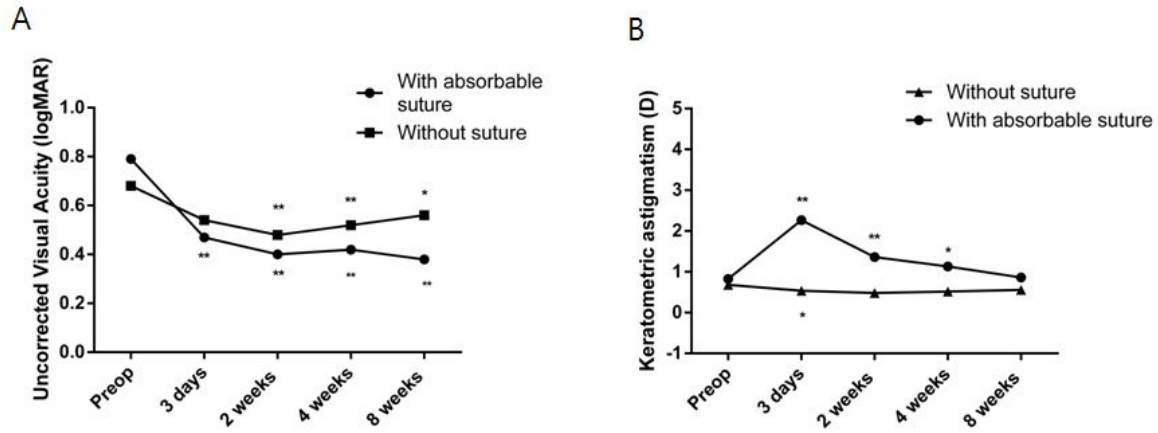


Fig. 1A. Changes in uncorrected distant visual acuity. These results showed significant changes over time within the same group. B. Changes of Keratometric astigmatism. Keratometric astigmatism of Group I was significantly different compared with preoperative values until 4 weeks post-surgery.

*, **: significant difference between preoperative corneal astigmatism and specific postoperative period on Student's t-test or Wilcoxon signed rank test ($P < 0.05$, < 0.01)

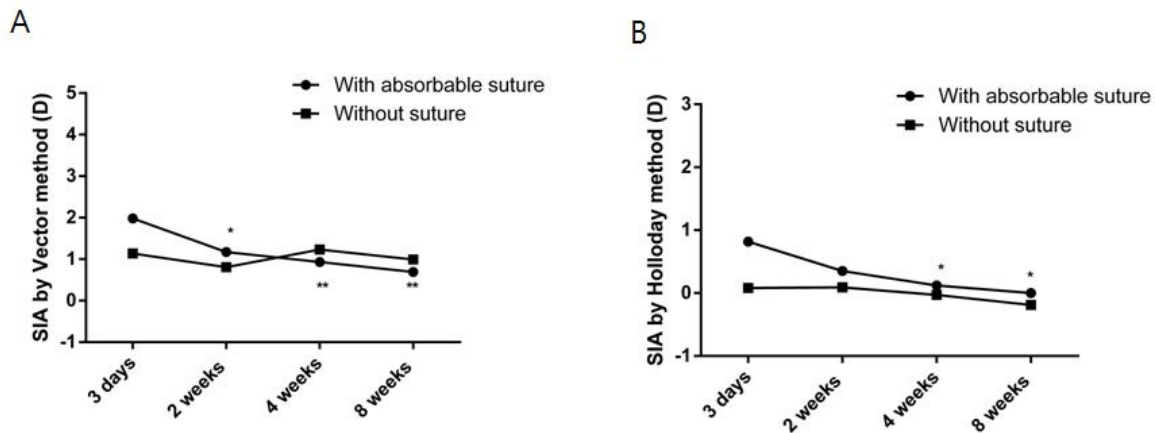


Fig. 2A. Surgically induced astigmatism by Vector method. Results of the sutured group showed a decrease in average corneal astigmatism over time. B. Surgically induced astigmatism by Vector method (with the wound astigmatism). Compared to surgically induced astigmatism at 3 days post-surgery, there was a significant decrease at 4 weeks post-surgery.

*, **: significant difference between preoperative corneal astigmatism and specific postoperative period on Student's t-test or Wilcoxon signed rank test ($P < 0.05$, < 0.01)

tigmatism (Table 2, Fig. 1B).

Surgically induced astigmatism using the Stephen's Vector method in the suture group was measured as $1.98 \pm 2.16D$, $1.17 \pm 1.31D$, $0.93 \pm 0.69D$, and $0.69 \pm 0.54D$ at 3 days, 2 weeks,

4 weeks and 8 weeks after surgery, respectively, which showed a gradually decreasing pattern over time ($P = 0.025, 0.003, 0.002$).¹⁷ In the unsutured group, it was measured as $1.14 \pm 1.07D$, $0.81 \pm 1.13D$, $1.23 \pm 1.55D$, and $0.99 \pm 0.99D$ at 3 days,

Table 1. Change of Uncorrected Visual acuity

	Group1 (n = 56)	<i>P</i> -value*,**	Group2 (n = 23)	<i>P</i> -value†, ††	<i>P</i> -value‡, ‡‡
Preoperative	0.79 ± 0.64		0.68 ± 0.72		0.145
Post 3 days	0.47 ± 0.44	< 0.001**	0.54 ± 0.74	0.080	0.330
Post 2 weeks	0.40 ± 0.44	< 0.001**	0.48 ± 0.74	< 0.001†	0.256
Post 4 weeks	0.42 ± 0.47	< 0.001**	0.52 ± 0.73	< 0.001††	0.688
Post 8 weeks	0.38 ± 0.54	< 0.001**	0.56 ± 0.80	0.010†	0.825

Values are presented as mean ± SD unless otherwise indicated.

Group 1: scleral tunnel incision with vicryl suture

Group 2: scleral tunnel incision with sutureless

*, **: significant difference between preoperative corneal astigmatism and specific postoperative period on Student's *t*-test ($P < 0.05$, < 0.01)

†, ††: significant difference between preoperative corneal astigmatism and specific postoperative period on Wilcoxon signed rank test ($P < 0.05$, < 0.01)

‡, ‡‡: significant difference between Group 1 and Group 2 on Mann-Whitney U test ($P < 0.05$, < 0.01)

Table 2. Changes of keratometric astigmatism (diopters)

	Group1 (n = 56)	<i>P</i> -value*,**	Group2 (n = 23)	<i>P</i> -value†, ††	<i>P</i> -value‡, ‡‡
Preoperative	0.83 ± 0.55		1.11 ± 0.72		0.139
Post 3 days	2.27 ± 2.12	< 0.001**	1.36 ± 0.90	0.066	0.021*
Post 2 weeks	1.36 ± 1.32	0.008**	1.33 ± 1.10	0.122	0.968
Post 4 weeks	1.13 ± 0.70	0.016*	1.20 ± 0.92	0.305	0.941
Post 8 weeks	0.86 ± 0.50	0.971	1.22 ± 0.83	0.340	0.081

Values are presented as mean ± SD unless otherwise indicated.

Group 1: scleral tunnel incision with vicryl suture

Group 2: scleral tunnel incision with sutureless

*, **: significant difference between preoperative corneal astigmatism and specific postoperative period on Student's *t*-test ($P < 0.05$, 0.01)

†, ††: significant difference between preoperative corneal astigmatism and specific postoperative period on Wilcoxon signed rank test ($P < 0.05$, < 0.01)

‡, ‡‡: significant difference between Group 1 and Group 2 on Mann-Whitney U test ($P < 0.05$, < 0.01)

2 weeks, 4 weeks and 8 weeks after surgery, respectively, which showed a relatively constant incidence of surgically induced astigmatism compared to Group 1 ($P = 0.050, 0.465, 0.116$). When we compared the surgically induced astigmatism between the two groups by each period with

Vector method, there was a significant difference until 2 weeks after surgery, but there was no statistically significant difference after 4 weeks (Table 3, Fig. 2A).

In the sutured group, the surgically induced astigmatism using Holladay method (with-the-wound

Table 3. Surgically induced astigmatism (diopters) by Vector method

	Group1 (n = 56)	P-value*,**	Group2 (n = 23)	P-value†, ††	P-value‡, ‡‡
Post 3 days	1.98 ± 2.16		1.14 ± 1.07		0.039‡
Post 2 weeks	1.17 ± 1.31	0.025*	0.81 ± 1.13	0.050	0.049‡
Post 4 weeks	0.93 ± 0.69	0.003**	1.23 ± 1.55	0.465	0.924
Post 8 weeks	0.69 ± 0.54	0.002**	0.99 ± 0.99	0.116	0.426

Values are presented as mean ± SD unless otherwise indicated.

Group 1 : scleral tunnel incision with vicryl suture

Group 2 : scleral tunnel incision with sutureless

*, **: significant difference between preoperative corneal astigmatism and specific postoperative period on Student's t test ($P < 0.05$, < 0.01)

†, ††: significant difference between preoperative corneal astigmatism and specific postoperative period on Wilcoxon signed rank test ($P < 0.05$, < 0.01)

‡, ‡‡: significant difference between Group 1 and Group 2 on Mann-Whitney U test ($P < 0.05$, 0.01)

change) was measured as $0.82 \pm 1.47\text{D}$ at 3 days after surgery, $0.35 \pm 1.00\text{D}$ at 2 weeks after surgery, $0.12 \pm 0.68\text{D}$ at 4 weeks after surgery, and $0.00 \pm 0.75\text{D}$ at 8 weeks after surgery.¹⁸ There was a significant decrease starting 4 weeks after surgery compared to 3 days after surgery. In the unsutured group, it was measured as $0.08 \pm 0.48\text{D}$ at 3 days after surgery, $0.09 \pm 0.49\text{D}$ at 2 weeks after surgery, $-0.03 \pm 0.45\text{D}$ at 4 weeks after surgery, and $-0.18 \pm 0.60\text{D}$ at 8 weeks after surgery. There was no significant difference in astigmatism values at 2 weeks, 4 weeks and 8 weeks after surgery when compared to the astigmatism value at 3 days after surgery ($P > 0.05$). When we compared the surgically induced astigmatism between the two groups by each period with Holladay method, there was a significant difference until 2 weeks after surgery, but there was no significant difference after 8 weeks (Table 4, Fig. 2B).

DISCUSSION

The unsutured scleral tunnel incision, which forms an incision 2 to 3 mm from behind the anterior border of the conjunctival vascular network, is a self-sealing incision technique in which a long scleral tunnel absorbs external pressure and acts as a valve or hinge on the internal corneal flap. This technique is superior to the clear corneal incision in terms of wound leakage,^{19,20} and incidence rate of endophthalmitis,^{6,21-23} and it is known to have a low incidence of surgically induced astigmatism for 3.0 to 3.5 mm incision.^{9,10} In addition, the sutureless scleral tunnel incision has other advantages such as prevention of iris prolapse or iris root rupture, decreased hyphema, and reduced postoperative inflammation. However, in cases of high possibility of infection or when self-sealing of the incision is not working, an absorbable suture may be needed to improve

Table 4. Surgically induced astigmatism (with the wound astigmatism, diopters) by Holloday method

	Group1 (n = 56)	P-value*,**	Group2 (n = 23)	P-value†, ††	P-value‡, ‡‡
Post 3 days	0.82 ± 1.47		0.08 ± 0.48		0.039‡
Post 2 weeks	0.35 ± 1.00	0.058	0.09 ± 0.49	0.794	0.049‡
Post 4 weeks	0.12 ± 0.68	0.030*	-0.03 ± 0.45	0.060	0.568
Post 8 weeks	0.00 ± 0.75	0.010*	-0.19 ± 0.60	0.125	0.221

Values are presented as mean ± SD unless otherwise indicated.

Group 1 : scleral tunnel incision with vicryl suture

Group 2 : scleral tunnel incision with sutureless

*, **: significant difference between preoperative corneal astigmatism and specific postoperative period on Student's t test ($P < 0.05$, < 0.01)

†, ††: significant difference between preoperative corneal astigmatism and specific postoperative period on Wilcoxon signed rank test ($P < 0.05$, < 0.01)

‡, ‡‡: significant difference between Group 1 and Group 2 on Mann-Whitney U test ($P < 0.05$, < 0.01)

the stability of the incision. There have been reports of surgically induced astigmatism after sutureless scleral tunnel incision^{8,14} and scleral tunnel incision using non-absorbable suture,^{12,13,15} but there have been no reports on astigmatism changes in 3 mm small scleral tunnel incision using absorbable suture.

In this study, the corneal astigmatism changes measured by automatic keratometer were significantly higher in the sutured group than in the unsutured group at the initial 3 days post-surgery. However, as the corneal astigmatism decreased after that, there was no statistical difference in corneal astigmatism between the sutured and unsutured groups from 2 weeks after surgery. This is thought to be the result of a rather strong suture in order to match the wound edge. Eight weeks after surgery, when corneal astigmatism became no statistically different in the sutured group compared to the presurgical condition, it was consid-

ered to be related to the disappearance of the tension of the absorbable suture.²⁴ There was no significant increase in the corneal astigmatism values between presurgery and post-surgery for the sutureless scleral tunnel incision, and it had a lower incidence of early astigmatism after surgery compared to the method using absorbable suture. In conclusion, the corneal astigmatism in scleral tunnel incision showed relatively consistent astigmatism after surgery in the unsutured group, while the sutured group showed higher corneal astigmatism than the unsutured group in early postoperative stage, which is thought to be stabilized over time.

When comparing the surgically induced astigmatism measured using the Vector method, the sutured group showed significantly higher astigmatism changes during the first 2 weeks after surgery compared to the unsutured group, but it showed a gradually decreased pattern and there

was no statistical difference between the two groups 2 weeks after surgery, showing similar changes to the corneal astigmatism as measured with keratometry. In the measurement of surgically induced astigmatism (with-the-wound astigmatism) using the Holladay method, it was possible to identify the flattening of the incision by the scleral tunnel incision and tissue compression and astigmatism induced by suture. The tendency of astigmatic change was similar to that of the precedent Vector method. In the group with the initial suture, surgically induced astigmatism (with-the-wound change) was 0.82D and 0.35D at 3 days and 2 weeks after surgery, respectively, in which many astigmatism resulted from wound compression by the suture. It was 0.12D and 0.00 D at 4 weeks and 8 weeks after surgery, which demonstrates that the effect of the suture disappeared over time. Vicryl, which was used as an absorbable suture, may differ depending on the suture site, thickness, and environmental causes, but is known to lose more than 50% of its tension usually after 2 weeks post-surgery based on the existing reports.²⁴ In this study, by looking at the pattern that when corneal astigmatism and surgically induced astigmatism were reduced and stabilized after 2 weeks post-surgery, it can be speculated that the astigmatism induced by the suture disappears when the tension of the suture is reduced by more than 50%.

At 8 weeks after surgery, the surgically induced astigmatism (with-the-wound change) was 0.0D and -0.18D in the sutured and unsutured groups,

respectively, with no statistical difference, but the degree of flattening by scleral incision was rather small in the sutured group. The surgically induced astigmatism was similar to that by Samuelson et al., in which the flattening effect was the mean of 0.24D at the 3 mm sutureless scleral tunnel incision with cadaver.²⁵ The difference between the two groups is thought to be due to less widening of the wound during suturing and faster healing of the wound. In the past, the use of non-absorbable sutures in conventional cataract surgery using a relatively large incision was reported to cause a steep incision at an early stage, but after a considerable period, a flattening of the incision occurred. More long-term follow-up is needed, but if the astigmatism caused by wound is stabilized within 2 months in recent small incision cataract surgery, the use of absorbable suture may have less incidence of astigmatism than sutureless surgery by adjusting the degree of flattening of the scleral incision site, even though there will be a difference depending on preoperative astigmatism and astigmatic axis. Therefore, further studies to analyze this are needed.

After a reduction of surgically induced astigmatism over time, there is an advantage of showing astigmatic variance similar to the sutureless method. In particular, surgery that increases the stability of the wound and has a relatively decreased incidence of astigmatism, can be considered in patients with high risk of endophthalmitis such as dacryocystitis, chronic conjunctivitis, and blepharitis, and patients with difficulty for out-

patient follow-up.

REFERENCES

1. Leaming DV. Practice styles and preferences of ASCRS members—2002 survey. *JCRS* 2003;29:1412–20.
2. Al Mahmood AM, Al-Swailem SA, Behrens A. Clear corneal incision in cataract surgery. *Middle East Afr J Ophthalmol* 2014;21:25–31.
3. Buzard KA, Febbraro JL. Transconjunctival corneoscleral tunnel "blue line" cataract incision. *J Cataract Refract Surg* 2000;26:242–9.
4. Beltrame G, Salvétat ML, Driussi G, Chizzolini M. Effect of incision size and site on corneal endothelial changes in cataract surgery. *J Cataract Refract Surg* 2002;28:118–25.
5. Hurvitz LM. Late clear corneal wound failure after trivial trauma. *Journal of cataract and refractive surgery* 1999;25:283–4.
6. Cooper BA, Holekamp NM, Bohigian G, Thompson PA. Case-control study of endophthalmitis after cataract surgery comparing scleral tunnel and clear corneal wounds. *Am J Ophthalmol* 2003;136:300–5.
7. Nielsen PJ. Prospective evaluation of surgically induced astigmatism and astigmatic keratotomy effects of various self-sealing small incisions. *J Cataract Refract Surg* 1995;21:43–8.
8. Hayashi K, Yoshida M, Hayashi H. Corneal shape changes after 2.0-mm or 3.0-mm clear corneal versus scleral tunnel incision cataract surgery. *Ophthalmology* 2010;117:1313–23.
9. Olsen T, Dam-Johansen M, Bek T, Hjortdal JO. Corneal versus scleral tunnel incision in cataract surgery: a randomized study. *J Cataract Refract Surg* 1997;23:337–41.
10. Huang FC, Tseng SH. Comparison of surgically induced astigmatism after sutureless temporal clear corneal and scleral frown incisions. *J Cataract Refract Surg* 1998;24:477–81.
11. He Y, Zhu S, Chen M, Li D. Comparison of the Keratometric Corneal Astigmatic Power after Phacoemulsification: Clear Temporal Corneal Incision versus Superior Scleral Tunnel Incision. *J Ophthalmol* 2009;2009:210621.
12. Mendivil A. Frequency of induced astigmatism following phacoemulsification with suturing versus without suturing. *Ophthalmic Surg Lasers* 1997;28:377–81.
13. Dam-Johansen M, Olsen T. Induced astigmatism after 4 and 6 mm scleral tunnel incision. A randomized study. *Acta ophthalmol Scandi* 1997;75:669–74.
14. Chen YC, Wu S. Keratometric astigmatism after cataract surgery using small self-sealing scleral incision. *Chang Gung Med J* 2001;24:19–26.
15. Gimbel HV, Sun R. Postoperative astigmatism following phacoemulsification with sutured vs. unsutured wounds. *Can J Ophthalmol* 1993;28:259–62.
16. Lyle WA, Jin GJ. Prospective evaluation of early visual and refractive effects with small clear corneal incision for cataract surgery. *J Cataract Refract Surg* 1996;22:1456–60.
17. Kaye SB, Campbell SH, Davey K, Patterson A. A method for assessing the accuracy of surgical technique in the correction of astigmatism. *Br*

- J Ophthalmol 1992;76:738-40.
18. Holladay JT, Cravy TV, Koch DD. Calculating the surgically induced refractive change following ocular surgery. J Cataract Refract Surg 1992;18:429-43.
19. McDonnell PJ, Taban M, Sarayba M, Rao B, Zhang J, Schiffman R, et al. Dynamic morphology of clear corneal cataract incisions. Ophthalmology 2003;110:2342-8.
20. Taban M, Sarayba MA, Ignacio TS, Behrens A, McDonnell PJ. Ingress of India ink into the anterior chamber through sutureless clear corneal cataract wounds. Arch Ophthalmol 2005;123:643-8.
21. Colleaux KM, Hamilton WK. Effect of prophylactic antibiotics and incision type on the incidence of endophthalmitis after cataract surgery. Can J Ophthalmol 2000;35:373-8.
22. Taban M, Behrens A, Newcomb RL, Nobe MY, Saedi G, Sweet PM, et al. Acute endophthalmitis following cataract surgery: a systematic review of the literature. Arch Ophthalmol 2005;123:613-20.
23. Lundstrom M, Wejde G, Stenevi U, Thorburn W, Montan P. Endophthalmitis after cataract surgery: a nationwide prospective study evaluating incidence in relation to incision type and location. Ophthalmology 2007;114:866-70.
24. Karabulut R, Sonmez K, Turkyilmaz Z, Bagbanci B, Basaklar AC, Kale N. An In Vitro and In Vivo Evaluation of Tensile Strength and Durability of Seven Suture Materials in Various pH and Different Conditions: An Experimental Study in Rats. Indian J Surg 2010;72:386-90.
25. Samuelson SW, Koch DD, Kuglen CC. Determination of maximal incision length for true small-incision surgery. Ophthalmic Surg 1991;22:204-7.