

# An atypical case of Lemierre syndrome following oropharyngeal infection

Seo Yeon Yang, Hae Yeul Park, Kyoung Hwa Lee, You Jin Chun, Hyo Eun Kim, Seong Han Kim, Su Jin Jeong

*Department of Internal Medicine, Yonsei University College of Medicine, Gangnam Severance Hospital, Seoul, Korea*

Lemierre syndrome is characterized by anaerobic bacterial infection in the head and neck and clinical or radiological evidence of internal jugular vein thrombophlebitis. The most common pathogens are *Fusobacterium* species, particularly *Fusobacterium necrophorum*. Septic emboli resulting from infected thrombophlebitis of the internal jugular vein leads to metastatic infections involving lung, liver, kidney, bone and central nervous system. The accurate diagnosis and treatment is important because it may be associated with a high mortality rate if untreated. We present a case of 28-year-old man with an atypical history for the diagnosis of Lemierre syndrome, which showed no definite evidence of internal jugular thrombophlebitis.

**Key words:** Empyema, *Fusobacterium*, Lemierre syndrome, Thrombophlebitis

Lemierre's syndrome refers to septic internal jugular vein thrombophlebitis, which is usually a complication of an anaerobic oropharyngeal infection such as tonsillitis and pharyngitis.<sup>1</sup> Lemierre's syndrome is mostly caused by infection with *Fusobacterium*, which normally exists in the oropharynx, urogenital organs, and gastrointestinal tract. Although Lemierre's syndrome was known in the past to cause lethal complications such as sepsis and septic embolism with fulminant catamenesis before antibiotics were universally applied, prevalence and mortality have been significantly decreased since the provision of an effective antibiotic, to the extent that it is called "a forgotten disease."<sup>2</sup> Despite the decrease in prevalence due to the early use of antibiotics and recent improve-

ments in oral hygiene, a late diagnosis may still cause a damaging effect. Therefore, it is important to suspect Lemierre's syndrome early on the basis of characteristic clinical symptoms and through noninvasive imaging diagnosis in order to prescribe an appropriate antibiotic.<sup>3</sup>

Most patients with Lemierre's syndrome may recover with conservative treatment such as antibiotic administration, but for some patients, even with antibiotic administration the symptoms may worsen, to the point of death in extreme cases. In such cases, a thorough examination of the accompanied underlying illness should be performed with proper treatment.

When thrombus is found inside the internal jugular vein, Lemierre's syndrome may be suspected

**Corresponding Author:** Su Jin Jeong, Department of Internal Medicine, Yonsei University College of Medicine, Gangnam Severance Hospital, 211 Eonju-ro, Gangnam-gu, Seoul 06273, Korea  
Tel: +82-2-2019-3304 Fax: +82-2-2019-3304 E-mail: JSJ@yuhs.ac.kr

**Received:** Oct. 26, 2015  
**Revised:** Oct. 26, 2015  
**Accepted:** Nov. 18, 2015

Articles published in Kosin Medical Journal are open-access, distributed under the terms of the Creative Commons Attribution Non-Commercial License (<http://creativecommons.org/licenses/by-nc/4.0/>) which permits unrestricted non-commercial use, distribution, and reproduction in any medium, provided the original work is properly cited.

earlier. We herein report a case of an atypical Lemierre's syndrome case, which first started with septic shock in a patient who had visited our institution with the complaint of quinsy, and which was later recovered but then turned to empyema without thrombus clearly identified in veins.

## CASE

A 28 year-old male patient, who had previously undergone treatment at a private clinic for sore throat, fever, headache, and muscle pain that had started two days earlier, visited the emergency room in our institution as his initial symptoms had not improved, and were then accompanied by nausea, vomiting, and consciousness fluctuation. The patient was hospitalized in the Division of Infectious Diseases due to the finding of continued fever and septic shock.

The patient did not have a significant medical history. Vital signs at the time of visiting our institution were blood pressure 90/53 mmHg, heart rate 122/min, respiratory rate 20/min, and body temperature 38.7°C. The physical examination showed enlargement of both tonsils with rubefaction as well as a white exudation.

The peripheral blood test performed at the time of visiting our institution showed white blood cells 18,120/ $\text{mm}^3$  (neutrophil 98.0%), hemoglobin 15.3 g/dL, hematocrit 42.3%, platelet 137,000/ $\text{mm}^3$ , erythrocyte sedimentation rate 22 mm/hr, and C-reactive protein 193.2 mg/L. The serum biochemistry test

showed blood urea nitrogen 15.7 mg/dL, creatinine 1.70 mg/dL, albumin 4.4 g/dL, and blood sugar 253 mg/dL. The serum electrolyte test showed sodium 131 mmol/L, potassium 3.1 mmol/L, chloride 96 mmol/L, and total carbon dioxide 19 mmol/L. The blood coagulation test showed PT 12.8 seconds and aPTT 26.8 seconds. Plain chest radiography showed no lesion in the lung parenchyma, and electrocardiography showed sinus tachycardia (Fig. 1).

The cervical CT performed for differentiating the cause of the infection showed enlargement of both tonsils and lymph node enlargement at the cervical II and III levels (Fig. 2A, B). Neither clear thrombus nor thrombophlebitis was found in the internal jugular vein (Fig. 2C). The abdominal CT showed a mild enlargement of the spleen. The chest CT showed mild bronchopneumonia at both inferior lobes. The cerebrospinal fluid puncture test showed no abnormal findings.

An empirical treatment for pharyngolaryngitis was

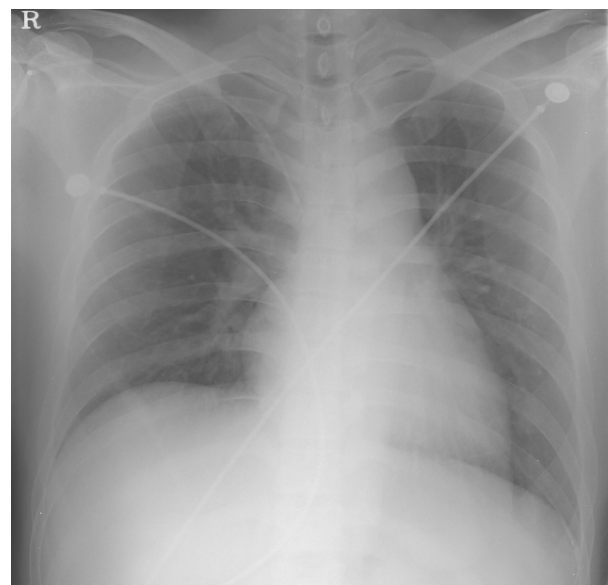


Fig. 1. Chest X-ray (Admission day)

started by intravenously injecting Ampicillin/Sulbactam 3000 mg four times per day. *Fusobacterium necrophorum* was identified in all of the three pairs of the blood culture tests that were performed at the time of visiting our institution. *α-Streptococcus* was identified from the sputum culture and the throat culture. Since the patient's fever continued, the antibiotic administration was changed on the second day of hospitalization to a combined administration of clindamycin 300 mg three times per day and levofloxacin 750 mg one time per day. The following blood culture test showed negative, and the clinical symptoms were improved gradually.

On the seventh day of hospitalization, the patient complained of respiratory distress, and the plain chest radiography showed pleural effusion at the left lung. Subsequent chest CT showed empyema accompanying necrotizing nodules, and thus pulmonary empyema by septic embolism was suspected (Fig. 3A, B). Considering the respiratory distress and empyema findings during the antibiotic treatment, a pulmonary complication due to Lemierre's syndrome was suspected. Thoracostomy was performed but no bacteria were identified in the pleural fluid culture test. Electrocardiography showed normal findings, with no heart murmur heard.

On the 12<sup>th</sup> day of hospitalization, decortication was performed due to the continued pleural effusion. No bacteria were identified from the pleural culture test. The pleural biopsy showed an abscess. Intravenous antibiotic treatment was continued after the surgery, and the clinical symptoms and the chest radiography findings were gradually

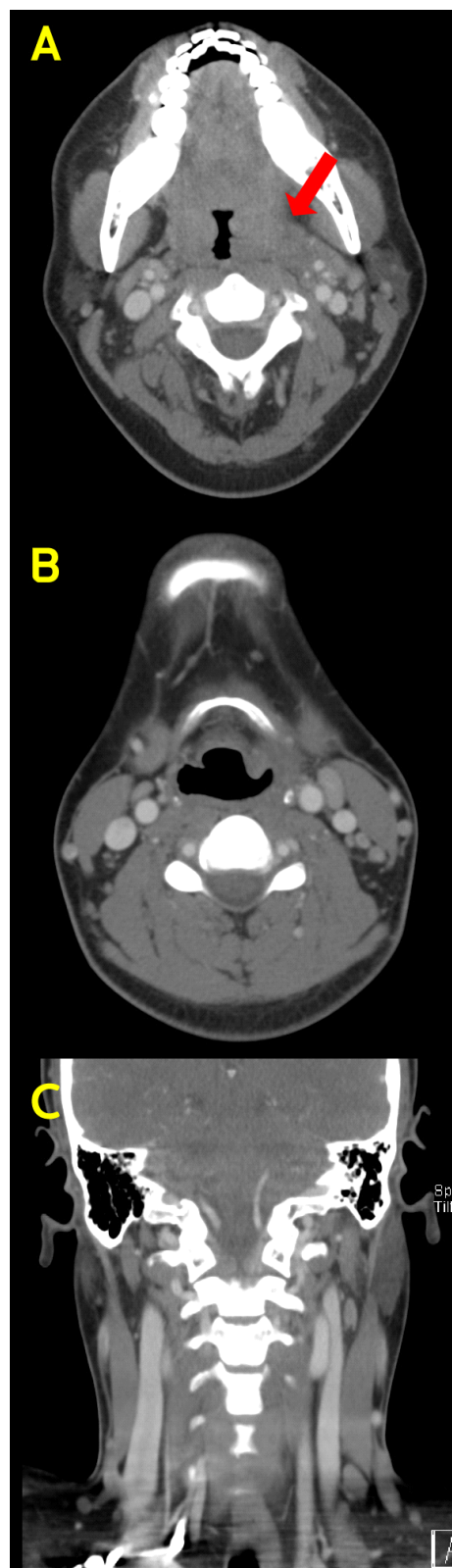


Fig. 2. Computed tomography of neck. It shows diffuse enlargement of both tonsil (A) and reactive lymph nodes in both neck level II, III. (B) There is no definite evidence of internal jugular thrombophlebitis. (C)

improved (Fig. 3C).

The patient was discharged on the 23<sup>rd</sup> day of hospitalization after three weeks of adjusted antibiotic administration. At the time of discharge, the blood test results were white blood cells 7,850/ $\text{mm}^3$  (neutrophil 48.4%), hemoglobin 11.8 g/dL, hematocrit 35.9%, and platelet 501,000/ $\text{mm}^3$ . The immune-serological test showed C-reactive protein 5.0 mg/L. The chest radiographic findings and the clinical symptoms showed a recovery.

## DISCUSSION

Lemierre's syndrome is a disease in which oropharyngeal infection or craniocervical infection is followed by anaerobic sepsis and thrombophlebitis in the internal jugular vein as well as septic embolism at the lungs and other organs. This disease was frequently reported in the 1920s and 1930s. In 1936, Andre Lemierre, a French microbiologist, reported 20 patients who had oropharyngeal infection followed by bacterial sepsis, and named the disease Lemierre's syndrome.<sup>1</sup> Since the 1960s, oropharyngeal infection has been treated with an antibiotic with the introduction of penicillin, and thus Lemierre's syndrome has become a very rare disease, with a reported prevalence of 0.6 to 2.3 cases per million.<sup>45</sup> However, the number of reports of the disease has been increasing recently, which may be due to the generalization of diagnostic methods such as chest CT and the high rate of report by the authors. . Alternatively,

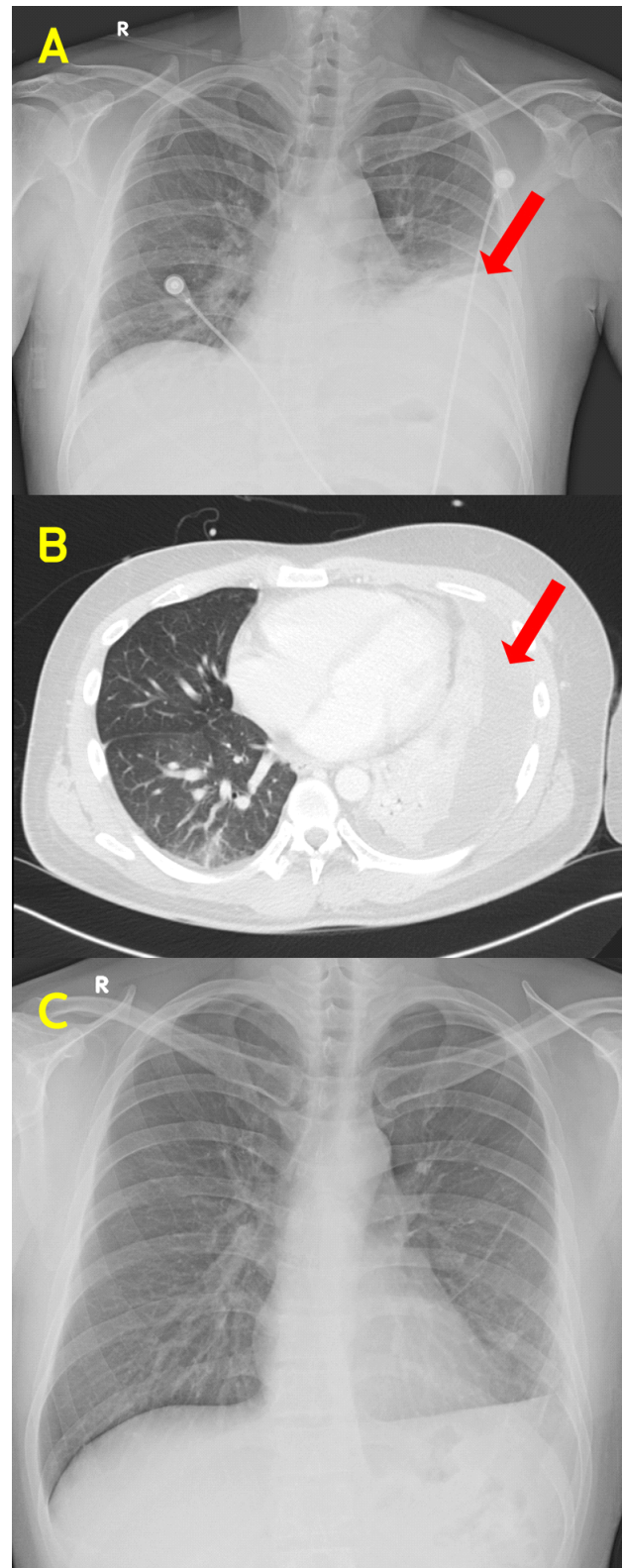


Fig. 3. Chest X-ray and Computed tomography of chest. It shows empyema of left lung (arrow).

the prevalence of the disease may have been increased because the causative bacteria are not sufficiently controlled, as the frequency of antibiotic administration has been changed from several times per day to one or two times per day due to the development of new antibiotics.<sup>6</sup> Lemierre's syndrome may occur in all age groups, but 70% of the reported patients are young adults between 16 and 25. Men are about two times more prone to the disease than women, and the rate of mortality is reported as 4 to 18%.<sup>5</sup>

The most common causative bacterium is *Fusobacterium necrophorum* (81.7%), but the disease may be caused by single or complex infection of *Fusobacterium nucleatum*, *Bacteroides*, *Streptococcus*, and *Proteus* bacteria. No bacteria are identified in 12.8% of cases.<sup>4</sup> *Fusobacterium necrophorum*, which is known as the most common causative bacterium, is an anaerobic Gram negative bacillus which shows symbiosis in the oral cavity. The bacteria has been known to have an endotoxin called lipopolysaccharide and secretes toxicity-related hemagglutinin, leukocidin, and leukocytolysin to destroy red blood cells and white blood cells, causing platelet agglutination and septic embolism.<sup>7</sup>

With respect to the onset mechanism, the infection started at the faucial tonsil and peritonsillar tissues in 87% of the case reports, while the first symptom was pharyngitis, parotiditis, sinusitis, mastoiditis, otitis media, oral infection, or odontogenic infection in 13% of the case reports.<sup>2</sup> In the next step, the oropharyngeal space along the carotid artery is infected, and the sepsis causes throm-

bophlebitis in the internal jugular vein. Finally, the bacteria are propagated through the blood flow, causing general complications in the lungs, heart, bones, and joints. Clinical symptoms include sore throat at the primary oropharynx accompanied by fever and chills in 80% of patients. Cervical lymphadenitis is generally found at the anterior triangle of the neck, and tenderness and swelling may be found unilaterally along the front side of the sternocleidomastoid muscle due to the thrombophlebitis in the internal jugular vein.<sup>4,5</sup> In 1989, Sinave et al. summarized the characteristic symptoms of Lemierre's syndrome and provided as diagnostic criteria 1) primary infection at the oropharynx, 2) sepsis in which at least one bacterium is cultured in a blood culture test, 3) clinical or radiographic evidence of thrombophlebitis in the internal jugular vein, and 4) transference to at least one body part.<sup>3</sup>

The most common complication of Lemierre's syndrome is pulmonary invasion, which occurs in the forms of pulmonary embolism, pleural effusion, pneumothorax, empyema, and others.<sup>3,4</sup> Invasion to the bones and joints may cause mild arthralgia, septic arthritis, and osteomyelitis, whereas invasion to the soft tissue and skin may cause abscess. Spread to the abdomen may cause abscess in the kidneys, liver, and spleen. Other complications include hepatomegaly, nephromegaly, acute renal failure, jaundice, and dyshepatia.<sup>3,8</sup>

In radiographic tests, the cervical ultrasonography may show thrombophlebitis in the internal jugular vein in the expanded veins, but it is limited to showing newly formed thrombus with

low shade density or the part under the clavicle or the jaw.<sup>4</sup> CT using a contrast agent is the most effective diagnostic method that may show expanded internal jugular vein, contrast enhanced vessel walls, filling defects, and soft tissue swelling.<sup>9</sup> Thrombophlebitis in the internal jugular vein is observed in 26 to 45% of Lemierre's syndrome patients. As in the present case report, a case has been reported in which a patient was diagnosed with Lemierre's syndrome without a clear finding of thrombophlebitis in the internal jugular vein in radiographic tests.<sup>10,15</sup> When a pulmonary complication is suspected, plain chest radiography and chest CT should be performed to diagnose on the basis of the findings of pulmonary infiltration, nodular lesions, pleural effusion, pneumothorax or empyema.<sup>11</sup>

When Lemierre's syndrome is suspected, intensive care is required, and extensive antibiotic treatment to defend all the Gram-positive, Gram-negative, and anaerobic bacteria is necessary. With respect to the choice of antibiotics, the bacterial culture test results should be referred to. However, since bacteria may not be well cultured when a patient has already been administered an oral antibiotic, and *Fusobacterium* is often unidentified by a culture test, it is recommended to perform the treatment by administering penicillin or cephalosporin type antibiotics in combination with clindamycin and metronidazole, which are effective against antibiotic bacteria.<sup>6,12</sup> For bacteria having  $\beta$ -lactam resistance, ampicillin/sulbactam or ticarcillin/clavulanate are recommended.<sup>13</sup>

Administration of antibiotics for a period of three to six weeks is generally recommended.<sup>5</sup> If abscess is found in a space where drainage is possible such as the oropharyngeal space or peritonsillar space, surgical drainage is necessary. Use of an anticoagulant for thrombophlebitis in the internal jugular vein is still controversial; there are reports that an anticoagulant should be administered to prevent a new transference lesion and to rapidly treat thrombophlebitis and bacteremia, while there is another report that an anticoagulant may be administered only in the presence of cavernous sinus thrombosis due to the risk of hemorrhage and deterioration of infection.<sup>9,14</sup>

The patient of the present case reported having received treatment from a private clinic for symptoms of quinsy which later progressed to sepsis with septic shock. The patient was diagnosed with Lemierre's syndrome because *Fusobacterium necrophorum* was identified in the blood culture test, and empyema which was believed to be caused by septic embolism was found, although the radiography did not show a distinctive finding of thrombophlebitis in the internal jugular vein. The number of cases of Lemierre's syndrome progressing to a severe catamnesis has been dramatically decreased due to the general application of antibiotics and the development of radiographic diagnostic methods. However, if not rapidly treated, Lemierre's syndrome may bring about fatal effects, causing complications in various organs. For this reason, the need for an early diagnosis is emphasized. As in the present case report, if a patient has quinsy

in which thrombus is not seen in the head or neck veins through radiography but shows septic shock or a severe atypical clinical pattern, the possibility of Lemierre's syndrome may be considered.

## REFERENCES

1. Lemierre A: On certain septicaemias due to anaerobic organisms. *The Lancet* 1936;227:701-3.
2. Golpe R, Marin B, Alonso M: Lemierre's syndrome (necrobacillosis). *Postgrad Med J* 1999;75:141-4.
3. Sinave CP, Hardy GJ, Fardy PW: The Lemierre syndrome: suppurative thrombophlebitis of the internal jugular vein secondary to oropharyngeal infection. *Medicine (Baltimore)* 1989;68:85-94.
4. Chirinos JA, Lichtstein DM, Garcia J, Tamariz LJ: The evolution of Lemierre syndrome: report of 2 cases and review of the literature. *Medicine (Baltimore)* 2002;81:458-65.
5. Syed MI, Baring D, Addidle M, Murray C, Adams C: Lemierre syndrome: two cases and a review. *Laryngoscope* 2007;117:1605-10.
6. Karkos PD, Asrani S, Karkos CD, Leong SC, Theochari EG, Alexopoulou TD, et al: Lemierre's syndrome: A systematic review. *Laryngoscope* 2009;119:1552-9.
7. Henry S, DeMaria A, Jr., McCabe WR: Bacteremia due to *Fusobacterium* species. *Am J Med* 1983;75:225-31.
8. Leugers CM, Clover R: Lemierre syndrome: post-anginal sepsis. *J Am Board Fam Pract* 1995;8:384-91.
9. Lustig LR, Cusick BC, Cheung SW, Lee KC: Lemierre's syndrome: two cases of postanginal sepsis. *Otolaryngology--Head and Neck Surgery* 1995;112:767-72.
10. Shakeel M, McCluney N, Li L, Newton JR: Oropharyngeal infection with metastatic hand infection: an uncommon variant of Lemierre's syndrome. *J Pak Med Assoc* 2010;60:494-6.
11. Williams A, Nagy M, Wingate J, Bailey L, Wax M: Lemierre syndrome: a complication of acute pharyngitis. *Int J Pediatr Otorhinolaryngol* 1998;45:51-7.
12. Ridgway JM, Parikh DA, Wright R, Holden P, Armstrong W, Camilon F, et al: Lemierre syndrome: a pediatric case series and review of literature. *Am J Otolaryngol* 2010;31:38-45.
13. Seidenfeld SM, Sutker WL, Luby JP: *Fusobacterium necrophorum* septicemia following oropharyngeal infection. *Jama* 1982;248:1348-50.
14. GOLDHAGEN J, ALFORD BA, PREWITT LH, THOMPSON L, HOSTETTER MK: Suppurative thrombophlebitis of the internal jugular vein: report of three cases and review of the pediatric literature. *The Pediatric infectious disease journal* 1988;7:410-3.
15. Riordan T, Wilson M.: Lemierre's syndrome: more than a historical curiosa. *Postgrad Med J* 2004;80:328-34.