

A Case of Ischemic Colitis Related with Usual Dosage of Ibuprofen in a Young Man

Eun Jeong Kim, Moo In Park, Seun Ja Park, Won Moon, Go Eun Yeo, Weon Hyoung Lee

Department of Internal Medicine, College of Medicine, Kosin University, Busan, Korea

젊은남자에서 상용량의 이부프로펜과 관련된 허혈성 대장염 1 예

김은정, 박무인, 박선자, 문원, 여고은, 이원형

고신대학교 의과대학 내과학교실

Ischemic colitis is a medical condition in which inflammation and injury of the large intestine result from inadequate blood supply. Although uncommon in the general population, ischemic colitis occurs with greater frequency in the elderly, and is the most common form of bowel ischemia. Other possible causes include medications such as NSAIDs(non-steroidal antiinflammatory drugs), oral contraceptives, diuretics and others. In recent years, many of NSAID use in young age can cause ischemic lesions, but it is not common. Here we report a case of ischemic colitis in a 31-year-old man who had no specific medical history except taking 200mg of ibuprofen three times a day for seven days. It suggests the importance of precise history taking, including medications usage such as NSAIDs and other risk factors.

Key Words: ischemic colitis, Ibuprofen, NSAID

Ischemic colitis is caused by a reduction in colonic blood flow, which most commonly arises from occlusion, vasospasm, and/or hypoperfusion of the mesenteric vasculature. Although uncommon in the general population, ischemic colitis is the most frequent form of mesenteric ischemia, affecting mostly the elderly because of age-related tortuosity of the colonic arteries.¹ Other predisposing factors include diseases of decreased blood flow (e.g., small vessel problems due to underly-

ing diseases such as thrombosis, hypertension, and diabetes mellitus), and iatrogenic causes such as surgery or drugs.² Medications, especially non-steroidal anti-inflammatory drugs (NSAIDs), have been reported as a rare cause of ischemic colitis in long-term NSAID users or in the setting of an acute overdose.³⁻⁶ We report a case of ischemic colitis developing after taking usual dosages of ibuprofen without particular comorbidity in a 31-year-old male.

Corresponding Author : Moo In Park, Division of Gastroenterology, Department of Internal Medicine, Kosin University Gospel Hospital, 262, Kamcheon-ro, Seo-gu, Busan, 602-702, Korea
TEL: +82-51-990-5133 FAX: +82-51-990-3049 E-mail: mipark@kosinmed.or.kr

Received : July 17, 2013

Revised : November 4, 2013

Accepted : December 16, 2013

CASE REPORT

A 31-year-old male visited the hospital for right-sided abdominal pain with watery diarrhea over 10 times, followed by two episodes of hematochezia during the previous day. One week prior, he had visited the hospital for a sore throat and was prescribed ibuprofen 200 mg three times daily for his throat pain. He had taken these drugs for seven days and stopped only when he was subsequently admitted to the hospital. There were no other specific findings from his past medical and social history. Blood pressure was 130/90 mm Hg, pulse rate 72/min, respiratory rate 20/min, and body temperature 36.7°C. Physical examination revealed an acutely ill-looking, with a soft abdomen and with tenderness on the right side of the abdomen. His complete blood count showed leukocyte count of $7,900/\text{mm}^3$, hemoglobin 15.6 g/dL, and platelet count $218,000/\text{mm}^3$. Blood chemistry was analyzed as total protein 6.9 g/dL, albumin 4.3 g/dL, total bilirubin 1 mg/dL, AST 17 U/L, ALT 32 U/L, alkaline phosphatase 82 U/L, amylase 43 U/L, lipase 21 U/L, blood urea nitrogen 12 mg/dL, creatinine 0.8 mg/dL, ESR 10 mm/hr, and CRP 0.07 mg/dL. Coagulation tests revealed a PT/aPTT of 10.3/29 seconds. Stool examination was white blood cell-positive with a negative culture result. Abdominal computerized tomography (CT) scans showed diffuse wall thickening of the colon, from the ascending to transverse colon, and a small amount of the fluid in the right lower abdomen (Fig. 1). A colonoscopy was performed on the second

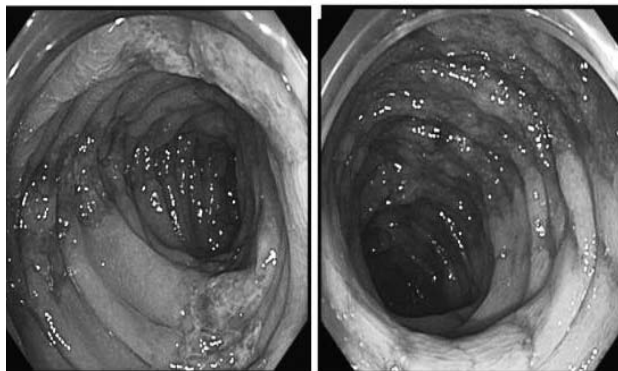


Fig 2. Colonoscopy showing hyperemic granular and easy friable mucosa, with linear ulcers running along the longitudinal axis from ascending to transverse colon.

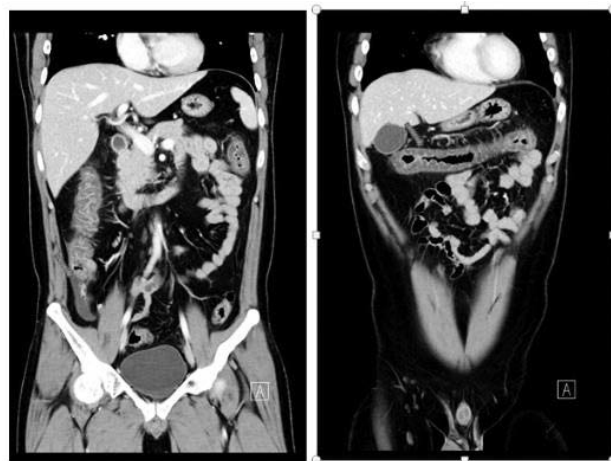


Fig 1. Abdominal computerized tomography showed the wall thickening of the colons, from ascending to transverse colon, and a small amount of the fluid in the right lower abdomen. The scans are otherwise unremarkable.

day of admission and showed hyperemic granular and easy friable mucosa, with linear ulcers running along the longitudinal axis from the ascending colon to transverse colon (Fig. 2). The descending colon mucosa was intact and without lesions. Biopsy was performed at 70 cm and 45 cm from anal verge, which revealed the loss of the surface epithelium, superficial mucosal necrosis, and hemorrhagic foci in the lamina propria and lymphocyte cell infiltration (Fig. 3). These findings were consistent with colonic ischemia. Autoimmune serologic tests (Antinuclear antibody, rheumatoid factor, antineutrophil cytoplasmic antibody, anti-cyclic citrullinated peptide antibody, Anti-ds DNA antibody) were all negative. Examinations evaluating acquired and hereditary thrombotic risk factors (antithrombin III, protein C, pro-

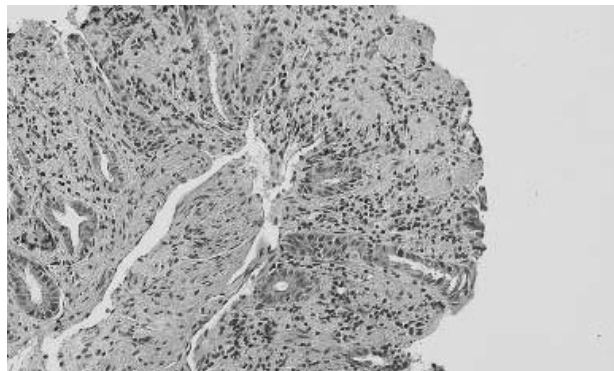


Fig 3. Colonoscopic biopsy showing loss of the surface epithelium, superficial mucosal necrosis, and hemorrhagic foci in the lamina propria and lymphocyte cell infiltration.

tein S, anticardiolipin Ab, lupus anticoagulant Ab) were also negative. Abdominal angiographic CT scans showed a patent mesenteric artery (Fig. 4). The patient was treated conservatively with bowel rest, intravenous fluids, and empirical antibiotics. His symptoms of abdominal pain, diarrhea, and hematochezia were relieved and colonoscopy was performed on the seventh day of admission. From the ascending to transverse colon, longitudinal hyperemic mucosa was noted, but in an improving state compared with the previous study (Fig. 5). The patient started a soft diet on day seven, and was discharged on day ten.

DISCUSSION

An association between non-selective NSAIDs and segmental ischemic colitis has been reported, but it is usually seen in elderly patients on long-term NSAID treatment. One additional case was reported, which was an acute overdose (8 g of ibuprofen for one day).³⁻⁶ In recent years, many of NSAID use in young age can cause ischemic lesions, but it is not common. Here we reported a case of transient ischemic colitis in a young patient, temporally related to the ingestion of a usual dose of ibuprofen. He presented typical symptoms of a sudden onset of abdominal pain followed within 24 hours by rectal bleeding. Endoscopic and pathological

findings were consistent to the diagnosis of ischemic colitis. The absence of any significant finding at the follow-up colonoscopy further supported this diagnosis. The symptoms of ischemic colitis occurred in a reasonable temporal sequence after treatment with the ibuprofen and resolved after drug withdrawal, suggesting the correlation. His medical history, clinical examination and extensive investigations excluded other possible causes of ischemic colitis.

Ibuprofen shares the same toxic profile as other NSAIDs. Like all other NSAIDs, the most frequent adverse effects of ibuprofen involve the GI tract. Usual dosages of ibuprofen generally have been associated with only minimal GI blood loss, and limited data indicate that the risk of GI tract bleeding and/or perforation with ibuprofen appears to be less than that with other prototypical NSAIDs (e.g., piroxicam, indomethacin, ketoprofen, naproxen, diclofenac).

Ibuprofen has been reported as the rare cause of ischemic colitis, however, in long-term NSAID users or the setting of an acute over dose.³⁻⁶ Ischemic colitis developing after taking a usual dosage of ibuprofen has not been reported in the literature. Generally, pathogenic mechanisms for NSAID-induced ischemic lesions are not only inhibition of prostaglandin synthesis via cyclooxygenase (COX) inhibition,⁷ but also uncouple mi-

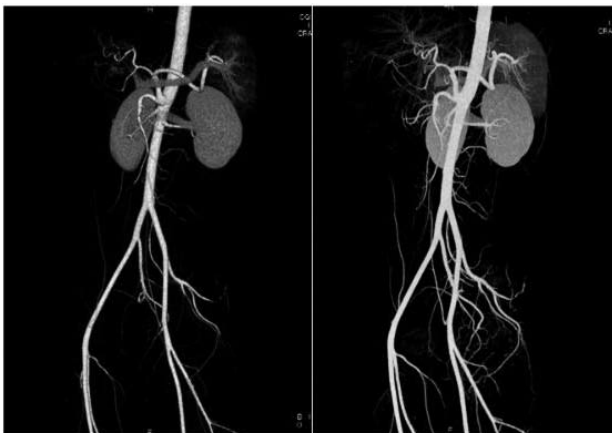


Fig 4. Abdominal angiographic computerized tomography showing patent mesenteric vessels and no other abnormal findings

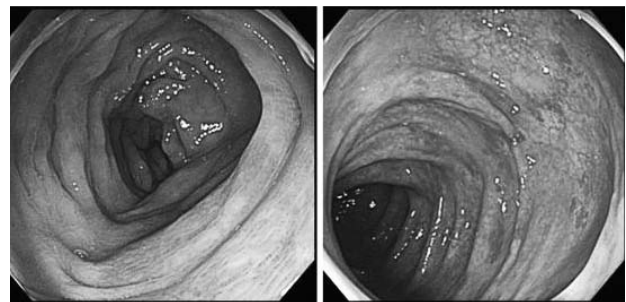


Fig 5. Colonoscopy performed at 7 days of admission showed several longitudinal hyperemic mucosa from ascending colon to transverse colon, improving compared with the previous study.

tochondrial oxidative phosphorylation.⁸ These substances also cause local topical toxicity.⁹ A connection between NSAID-induced microcirculatory disorders and the adhesion of neutrophil granulocytes to vascular endothelium was demonstrated.¹⁰⁻¹¹ In addition, liberation of TNF- α is triggered, which is responsible for the liberation of the intracellular adhesion molecule-1 at the vessel walls, and which can lead to local microcirculatory disorders due to vascular spasms.¹⁰⁻¹¹ All these synergistic interactions, particularly the microcirculatory disorders caused by spasms of the tiny blood vessels, can give rise to ischemic erosions and ulcerations in the GI tract.¹²⁻¹⁵

The treatment of ischemic colitis depends on the clinical manifestations and colonoscopic findings. Most patients with ischemic colitis improve with conservative management including bowel rest, intravenous fluids, and empiric antibiotics. Some cases may require surgery for gangrenous colitis or stricture. The prognosis depends on the extent of injury and comorbidities, but around 85% of patients improve within one to two days of conservative management and most fully recover within two weeks. About 20% of patients progress to a peritonitis requiring surgery. Our patient showed improvement with conservative management. He did not have a recurrence of the disease after stopping the ibuprofen.

As far as we know, a case of ischemic colitis in a young patient who presented with typical symptoms related to the ingestion of ibuprofen has never been reported and suggests the importance of precise history taking, including medications usage such as NSAIDs and other risk factors for thrombosis. The exact mechanisms that would explain this case remain unclear. Colonic ischemia in patients prescribed ibuprofen over a short period of time has not been clearly established. Further studies are needed to clarify the mechanism by which the usual dosage of NSAIDs can induce ischemic colitis.

REFERENCES

1. Higgins PD, Davis KJ, Laine L. Systematic review: the epidemiology of ischaemic colitis. *Aliment Pharmacol Ther* 2004;19:729-38.
2. Green BT, Tendler DA. Ischemic colitis: a clinical review. *South Med J* 2005;98:217-22.
3. Gibson GR, Whitacre EB, Ricotti CA. Colitis induced by Non-steroidal anti-inflammatory drugs. Report of and review of the literature. *Arch Intern Med* 1992;152:625-32.
4. Bjarnason I, Hayllar J, MacPherson AJ, Russell AS. Side effects of nonsteroidal anti-inflammatory drugs on the small and large intestine in humans. *Gastroenterology* 1993;104:183-47.
5. Carratu R, Parisi P, Agozzino A. Segmental ischaemic colitis associated with nonsteroidal antiinflammatory drugs. *J Clin Gastroenterol*. 1993;16:31-4.
6. Appu S, Thompson G. Gangrenous ischemic colitis following non-steroidal anti inflammatory drug overdose. *ANZ J Surg* 2001;71:694-5.
7. Vane JR. Inhibition of prostaglandin synthesis as a mechanism of action of aspirin - like drugs. *Nat New Biol* 1971;231:232-5.
8. Mahmud T, Rafi SS, Scott DL, Wrigglesworth JM, Bjarnason I. Nonsteroidal antiinflammatory drugs and uncoupling of mitochondrial oxidative phosphorylation. *Arthritis Rheum* 1996;39:1998-2003.
9. Brune K, Schweitzer A, Eckert H. Parietal cells of the stomach trap salicylates during absorption. *Biochem Pharmacol* 1977;26:1735-40.
10. Davies NM, Wallace JL. Nonsteroidal anti-inflammatory drug-induced gastrointestinal toxicity: New insights into an old problem. *J Gastroenterol* 1997;32:127-33.
11. Appleyard CB, McCafferty DM, Tigley AW, Swain MG, Wallace JL. Tumor necrosis factor mediation of NSAID-induced gastric damage: role of leukocyte adherence. *Am J Physiol* 1996;270:G42-8.
12. Aabakken L, Osnes M. Non-steroidal anti-inflammatory drug-induced disease in the distal ileum and large bowel. *Scand J Gastroenterol Suppl* 1989;163:48-55.
13. Gargot D, Chaussade S, d'Alteroche L, Desbazeille F, Grandjouis S, Louvel A, et al. Non-steroidal anti-inflammatory drug-induced colonic strictures: two cases and literature review. *Am J Gastroenterology* 1995;90:2035-8.
14. Gut A, Halter F, Ruchti C. Nonsteroidal antirheumatic drugs and acetylsalicylic acid: adverse affects distal to the duodenum. *Schweiz Med Wochenschr* 1996;126:616-25.
15. Bjarnason I, Hayllar J, MacPherson AJ, Russell AS. Side effects of nonsteroidal anti-inflammatory drugs on the small and large intestine in humans. *Gastroenterology* 1993;104:1832-47.