

# Bladder Pheochromocytoma Presented as Thunderclap Headache Triggered by Urination and Angina Pectoris

You Jin Han, Ho Sik Shin, Yeon Soon Jung, Hark Rim, So Young Ock, Eun Jeong Kim

*Department of Internal Medicine, College of Medicine, Kosin University, Busan, Korea*

## 배뇨 후벼락두통, 협심증으로 발현한 방광크롬친화세포종

한유진·신호식·정연순·임 학·옥소영·김은정

고신대학교 의과대학 내과학교실

Pheochromocytoma is a catecholamine-producing tumor characterized by hypertension, headache, tachycardia, excessive diaphoresis, and angina pectoris. The thunderclap headache is so named because the pain strikes suddenly and severely. Although the symptoms of bladder pheochromocytoma are rather evident, the diagnosis of this rare neuroendocrine tumor can be missed. This study reports the case of a woman diagnosed with bladder pheochromocytoma who experienced thunderclap headache triggered by urination and angina pectoris as an initial manifestation. This case study suggests that thunderclap headache and angina pectoris occurring concurrently with sudden blood pressure elevation during or immediately after urination are important diagnostic clues of bladder pheochromocytoma.

**Key Words:** Angina pectoris, Pheochromocytoma, Thunderclap headache, Urination

Pheochromocytoma, which is a catecholamine-producing tumor that causes secondary hypertension, arises from any location in which the chromaffin cells of the sympathetic nervous system are present.<sup>1</sup> In adults, approximately 90% of pheochromocytomas arise within the adrenal medulla and about 10% extra-adrenal pheochromocytomas arise from the chromaffin cells of the paraganglionic system in the bladder, cranium, and abdomen.<sup>2</sup> Bladder pheochromocytoma is an especially rare neuroendocrine tumor that accounts for less than 1% of all pheochromocytomas and less than 0.06% of all bladder tumors.<sup>3</sup> An elevated 24-h urinary excretion level of epine-

phrine and norepinephrine with its metabolites is the confirmatory diagnostic tool.<sup>4</sup> In most cases, history taking is the most important tool for the preoperative diagnosis of pheochromocytomas that primarily originate from the bladder. The typical clinical presentation of bladder pheochromocytoma is macroscopic hematuria, paroxysmal or persistent hypertension, tachycardia, angina, excessive diaphoresis, facial pallor, weakness, and approximately 50% of the patients experience thunderclap headache after urination.<sup>5,6</sup> We report the case of a patient diagnosed with bladder pheochromocytoma who had recurrent thunderclap headache after urination and angina

**Corresponding Author:** Ho Sik Shin, Department of Internal Medicine, Kosin University Gospel Hospital, 262 Gamcheon-ro, Seo-gu, Busan, 602-702, Korea  
TEL: +82-51-990-6108 FAX: +82-51-248-5686 E-mail: danieljoseph@hanmail.net

**Received:** July 11, 2013  
**Revised:** November 12, 2013  
**Accepted:** December 11, 2013

pectoris.

## CASE REPORT

A 61-year-old woman was admitted with recurrent headaches after urination and angina pectoris. She had experienced syncope during urination 15 years prior to admission, and she had undergone coronary angiography and ballooning for chest pain and a diagnosis of angina pectoris 3 years later. After 2 years, in 2002, the patient was found to have a bladder tumor. Imaging was the only form of follow-up performed for the tumor and it had remained the same size until 2007. For the 7 years prior to admission, she experienced recurrent thunderclap headache with hypertension immediately after urination or during urination, and treatment with antihypertensive medication had not resulted in improvement. Family history about pheochromocytoma was not known. The findings on physical examination, including fundoscopic findings, were unremarkable. Her blood pressure (BP) was 120/90 mmHg upon admission but became elevated to 230/110 mmHg after urination. An electrocardiogram revealed a 2-mm ST segment elevation on lead V2–3 and T wave inversion on V2–6. Coronary angiography did not reveal significant stenosis but a 30% tubular eccentric narrowing feature was found on the proximal left anterior descending artery, which implied minimal coronary artery disease. An echocardiogram showed that the ejection fraction of the left ventricle was 72% with intact wall motion. We suspected bladder pheochromocytoma on the basis of her history and symptoms, such as headache related to urination and angina pectoris. Her 24-h urinary biochemical analysis showed the following findings: vanillyl-mandelic acid (VMA), 5.93 mg/day (normal range: 2–8

mg/day); metanephrine, 473  $\mu$ g/day (normal range: 0–300  $\mu$ g/day); normetanephrine, 1,508  $\mu$ g/day (normal range: 0–600  $\mu$ g/day); epinephrine 10.4  $\mu$ g/day (normal range: 0–20  $\mu$ g/day); and norepinephrine 171.3  $\mu$ g/day (normal range: 15–80  $\mu$ g/day). The blood sampling analysis showed the following results: dopamine 0.042 ng/mL (normal range: 0–0.2 ng/mL); epinephrine 0.153 ng/mL (normal range: 0–0.3 ng/mL); norepinephrine 0.5 ng/mL (normal range: 0–0.8 ng/mL); renin activity 0.32 ng/mL/hr (normal range 0.1–0.0–6 ng/mL/hr); aldosterone 61.5 pg/mL (normal range 40–310 pg/mL); ACTH 46.3 pg/mL (normal range 0–80 pg/mL); cortisol 11.30  $\mu$ g/dL (normal range 4.30–22.40  $\mu$ g/dL); fasting glucose 103 mg/dL (normal range 70–124 mg/dL); WBC count 6,200 /uL; Hb 12.2g/dL; platelet 189,000 /uL. A contrast-enhanced computed tomography (CT) scan of her abdomen and pelvis revealed a 3  $\times$  3.2 cm-sized, well-enhanced, solid mass at the left lateral wall of the bladder (Fig. 1). The patient's BP was within the normal range when CT was taken. On the I-131 metaiodobenzylguanidine (I-131 MIBG) tumor single-photon emission computed tomography (SPECT),

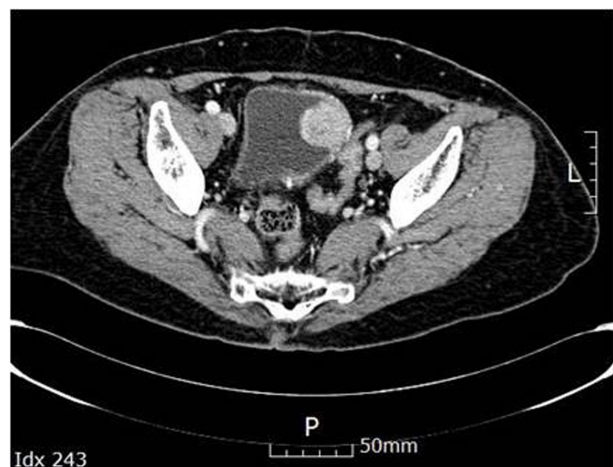

Fig. 1. Abdominal CT showed an intraluminal polypoid mass of approximately 3  $\times$  3.2 cm in size with heterogeneous enhancement at the left lateral wall of the urinary bladder.

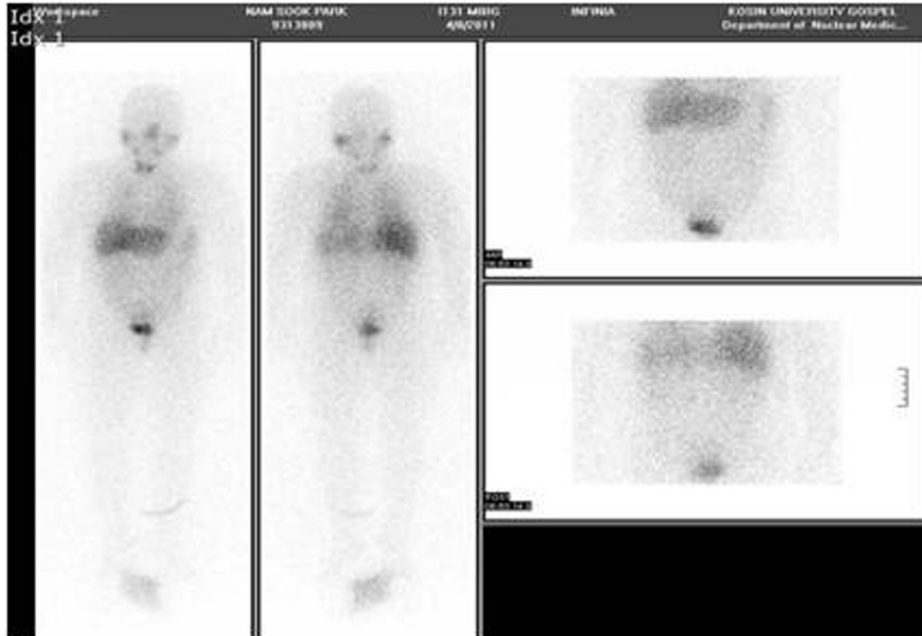


Fig. 2.  $^{131}\text{I}$ -MIBG scan showed partial uptake in the left side of the urinary bladder, which is consistent with pheochromocytoma.

increased uptake in the urinary bladder was found only at the left lateral wall of the bladder (Fig. 2). We diagnosed her with bladder pheochromocytoma and recommended surgery. After preoperative treatment with an  $\alpha$ -blocker (Doxazocin) for 2 weeks, the patient underwent partial cystectomy under general anesthesia. Immunohistochemical analyses revealed that the tumor cells were positive for CD56, chromogranin, and synaptophysin. On follow-up cystoscopy, no remnant tumor was detected and her BP decreased to 130/80 mmHg on average after the surgery. She no longer experienced angina pectoris and thunderclap headache triggered by urination.

Histological examination confirmed the diagnosis of bladder pheochromocytoma with morphological features that indicated benign behavior. Macroscopically, the surgical specimen measured  $3 \times 3.2$  cm in size and the lesion appeared yellow/brown in color and measured 3 cm at the cut surface (Fig. 3). Microscopically, the tumor was associated with the

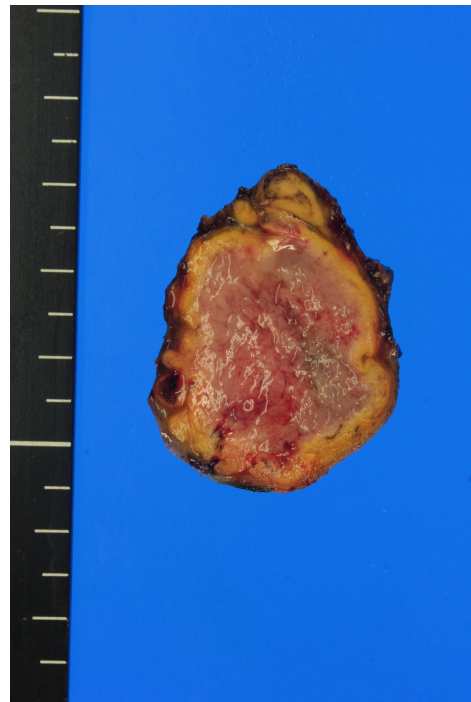


Fig. 3. Macroscopically, the pheochromocytoma was a  $3 \times 3.2$ -cm sized mass abutting from the left wall of the urinary bladder.

muscular bladder wall, whereas the bladder urothelium and the subepithelial stroma were preserved.

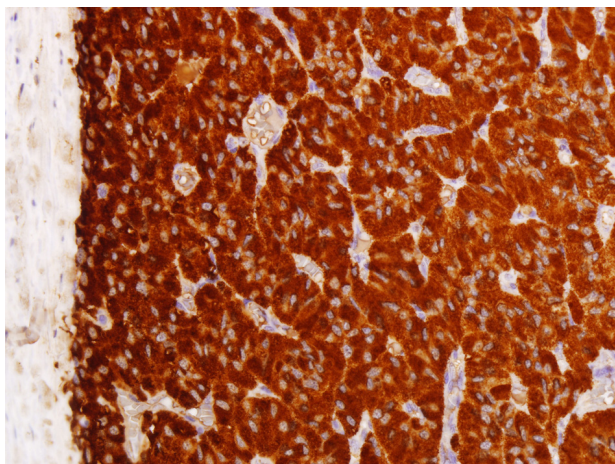


Fig. 4. Immunohistochemical analysis revealed that the tumor cells were positive for chromogranin A staining ( $\times 100$ ).

Immunohistochemical analysis revealed that the tumor cells were positive for chromogranin A staining ( $\times 100$ ) (Fig. 4). No evidence of vascular/capsular invasion, necrosis, mitosis, or hemorrhage was found. All of the morphological features included in the Pheochromocytoma of the Adrenal gland Scaled Score (PASS) were evaluated, resulting in a PASS score of  $<2/20$  (tumor with benign behavior).<sup>3</sup>

## DISCUSSION

Paragangliomas are rare neuroendocrine neoplasms that develop from the germinal cells of the neural crest and usually involve the adrenal glands. Bladder pheochromocytoma is a particularly unusual form of paraganglioma that represents less than 1% of all pheochromocytomas.<sup>7</sup> The clinical features of bladder pheochromocytoma are various and include hematuria and hypertensive crisis together with headache, angina, palpitation, hot flashes, sweating and sometimes with intense abdominal discomfort.<sup>8</sup> These crises are typically induced by urination or over distension of the bladder, which leads to systemic

release of catecholamines. However, not all bladder pheochromocytomas result in this syndrome and some show no hormonal activity. Signs of hormonal activity are seen in 83% of bladder pheochromocytomas in the literature.<sup>9</sup> In these cases, the diagnosis can be completely incidental. Therefore, detecting the disease requires a high degree of clinical suspicion based on the patient's symptoms owing to both the rarity of this lesion and the variety of its clinical features.<sup>10</sup> Thunderclap headache may be an indication of a medical emergency. Therefore, immediate medical attention is needed for any headache that comes on suddenly and severely. In our case, the patient's usual systolic BP and diastolic BP were 100–110 mmHg/60–70 mmHg, but the systolic BP increased to an average of 180–200 mmHg and the diastolic BP to 100–120 mmHg after urination. The underlying cause of recurrent thunderclap headache with these hypertensive crises was bladder pheochromocytoma, which can lead to a potentially lethal condition when unrecognized.

The diagnosis of pheochromocytoma is supported by measurements of catecholamines and their metabolites, metanephrine and normetanephrine, in plasma and 24-h urine samples.<sup>7</sup> In our case, the level of 24-h urine metanephrine was elevated to 473  $\mu\text{g}/\text{day}$ . After biochemical tests, imaging techniques such as CT or magnetic resonance imaging should be performed to locate the neoplasm. The diagnosis can be enhanced by iodine-MIBG scanning, which has a sensitivity of 78% for adrenal pheochromocytomas and 67–89% for extra-adrenal localizations.<sup>9</sup> We used the contrast-enhanced CT scan and Iodine-MIBG scanning to diagnose and determine the location of the tumor. Standardized histological features or a scoring system to distinguish benign from malignant

bladder pheochromocytomas have not been reported in the literature. A PASS system, which is usually utilized to study adrenal gland pheochromocytomas<sup>3</sup> was applied to determine whether the tumor had benign or aggressive behavior in the present case. The application of these criteria in a large series of bladder pheochromocytomas may help to evaluate the presence of malignant bladder pheochromocytoma. The PASS system can apply to bladder pheochromocytomas as well as to adrenal gland pheochromocytomas. This case showed a PASS score of  $<2/20$ , indicating benign tumor behavior and the tumor cells involved the muscle proper, submucosa, and mucosa layer with positivity for chromogranin A, S-100, and synaptophysin, and were confirmed as bladder pheochromocytoma.

In our case, the diagnosis was established by finding increased levels of catecholamine metabolites in the urine and CT imaging after clinical suspicion. The optimal treatment for pheochromocytoma is prompt surgical excision because patients are at a significant risk of lethal complications such as hypertensive crisis. Open surgery to perform a partial cystectomy is recommended because of the multilayer involvement of the bladder wall. Radical cystectomy with pelvic lymphadenectomy is recommended if metastasis is definitely present. Radiotherapy and chemotherapy have limited effectiveness.<sup>9</sup>

In summary, this case serves as a reminder of the importance of a thorough history and clinical examination in making diagnoses. Nephrologists, endocrinologists, cardiologists, and urologists should work

together to minimize the risk of misdiagnosis. This case study suggests that thunderclap headache and angina pectoris occurring concurrently with sudden blood pressure elevation during or immediately after urination are important diagnostic clues of bladder pheochromocytoma.

## REFERENCES

1. Whalen RK, Althausen AF, Daniels GH. Extra-adrenal pheochromocytoma. *J Urol* 1992;147:1-10.
2. Gifford RW Jr, Manger WM, Bravo EL. Pheochromocytoma. *Endocrinol Metab Clin North Am* 1994;23:387-404.
3. Thompson LD. Pheochromocytoma of the Adrenal gland Scaled Score (PASS) to separate benign from malignant neoplasms: a clinicopathologic and immunophenotypic study of 100 cases. *Am J Surg Pathol* 2002;26:551-66.
4. Pacak K, Linehan WM, Eisenhofer G, Walther MM, Goldstein DS. Recent advances in genetics, diagnosis, localization, and treatment of pheochromocytoma. *Ann Intern Med* 2001;134:315-29.
5. Bourne RB, Beltaos E. Pheochromocytoma of the bladder: case report and summary of literature. *J Urol* 1967;98:361-4.
6. Farley SE, Smith CL. Unusual location of pheochromocytoma in the urinary bladder. *J Urol* 1959;81:130-2.
7. Kappers MH, van den Meiracker AH, Alwani RA, Kats E, Baggen MG. Paraganglioma of the urinary bladder. *Neth J Med* 2008;66:163-5.
8. Choi EK, Kim WH, Park KY. A case of a composite adrenal medullary tumor of pheochromocytoma and ganglioneuroma masquerading as acute pancreatitis. *Korean J Intern Med* 2006;21:141-5.
9. Tazi MF, Ahallal Y, Tazi E, Benlemlih A, Chbani L, Amarti A, et al. Pheochromocytoma of the urinary bladder: a case report. *Cases J* 2009;2:8585.
10. Seki N, Mukai S, Gamachi A, Migita T, Maeda K, Ogata N. A case of bladder pheochromocytoma. *Urol Int* 2001;66:57-60.