

# Orbital complications of acute rhinosinusitis in adults: a 21-year experience

Yung Jin Jeon<sup>1,2</sup>, Woohyen Jin<sup>1</sup>, Yeon-Hee Joo<sup>2,3</sup>, Hyun-Jin Cho<sup>1,2</sup>, Sang-Wook Kim<sup>1,2</sup>

<sup>1</sup>Department of Otorhinolaryngology, Gyeongsang National University Hospital, Jinju, Korea

<sup>2</sup>Institute of Health Sciences, Gyeongsang National University, Jinju, Korea

<sup>3</sup>Department of Otorhinolaryngology, Gyeongsang National University Changwon Hospital, Changwon, Korea

**Background:** Orbital complications arising from acute rhinosinusitis (ARS) are a major concern for clinicians and serve as important warning indicators of ARS. Prompt recognition and appropriate management are crucial for preventing potential vision-threatening sequelae. Orbital complications of rhinosinusitis are markedly more common in children than in adults. The aim of this study was to investigate the clinical characteristics and treatment outcomes of orbital complications of ARS in adult patients.

**Methods:** This retrospective observational cohort study analyzed the medical records of 176 patients admitted for orbital cellulitis/abscess (ICD code: H050) who underwent orbit or paranasal computed tomography from January 2001 to February 2022 at a tertiary hospital.

**Results:** Eighteen adults with a mean age of  $53.2 \pm 18.9$  years were diagnosed with orbital complications due to ARS: five (27.8%) had preseptal cellulitis, eight (44.4%) had orbital cellulitis, and five (27.8%) had subperiosteal orbital abscess. None of the patients had an orbital abscess or cavernous sinus thrombosis. All patients had unilateral orbital complications (7 right and 11 left) and were managed with intravenous antibiotics for an average of  $10.3 \pm 6.6$  days. Five patients with subperiosteal orbital abscesses underwent intranasal endoscopic drainage at an average of  $1.4 \pm 1.9$  days after admission, while two patients required additional external drainage. Complete recovery was observed in all patients.

**Conclusions:** Conservative antimicrobial therapy can be effective for treating orbital complications from ARS, and not all adult patients require immediate surgical intervention for subperiosteal abscesses. Nonetheless, careful monitoring is essential, and an ophthalmologist must check patients' visual acuity to prevent irreversible blindness.

**Keywords:** Abscess; Adult; Cellulitis; Orbital diseases; Sinusitis

## Introduction

Acute rhinosinusitis (ARS) is a condition characterized by inflammation of the nasal cavity and paranasal sinuses that typically lasts for up to 12 weeks according to the European Position Paper on Rhinosinusitis and Nasal Polyps (EPOS) 2020

[1]. ARS is among the top five causes of antibiotic prescriptions, accounting for one in every five reasons for antibiotic prescriptions for adults [2]. Approximately 17% to 21% of adults are diagnosed with ARS each year [3,4]. Orbital complications arising from ARS are a major concern for clinicians, often presenting with periorbital swelling, pain, and potential visual dis-

Received: March 3, 2024; Revised: May 11, 2024; Accepted: May 17, 2024

Corresponding Author: Yung Jin Jeon, MD, PhD

Department of Otorhinolaryngology, Gyeongsang National University Hospital, 79 Gangnam-ro, Jinju 52727, Korea

Tel: +82-55-750-8178 Fax: +82-55-759-0613 E-mail: [myjin8704@gmail.com](mailto:myjin8704@gmail.com)

© 2024 Kosin University College of Medicine

© This is an Open Access article distributed under the terms of the Creative Commons Attribution Non-Commercial License (<https://creativecommons.org/licenses/by-nc/4.0/>) which permits unrestricted non-commercial use, distribution, and reproduction in any medium, provided the original work is properly cited.

turbances. Prompt recognition and appropriate management are crucial in preventing potential vision-threatening sequelae.

While orbital complications of rhinosinusitis are more commonly observed in children, they are also encountered in adults. However, there is limited information on the clinical features and treatment outcomes of orbital complications of rhinosinusitis in adult patients. Therefore, this retrospective observational cohort study aimed to investigate the clinical characteristics and treatment outcomes of adult patients diagnosed with orbital complications due to ARS admitted to Gyeongsang National University Hospital over the past two decades. The study included patients diagnosed with orbital complications such as cellulitis or abscess and evaluated the correlation with rhinosinusitis based on computed tomography (CT) findings.

## Methods

**Ethical statements:** This study was approved by the Institutional Review Board (IRB) of Gyeongsang National University Hospital (IRB No. 2023-08-013). Informed consent was waived.

Data from 176 patients older than 18 years of age who were admitted for orbital complications such as cellulitis or abscess at Gyeongsang National University Hospital from January 2001 to June 2022 were retrospectively collected from an electronic medical record database. Orbital complications were identified using the International Classification of Diseases, tenth revision (ICD-10) code (H050) occurring at least twice. Among 176 patients, 166 had a history of orbit or paranasal sinus CT. Non-enhanced or enhanced axial and coronal reformatted images were acquired for all cases. Two otorhinolaryngologists (YJJ and WH) who were blinded to patient clinical information and perioperative findings, evaluated the CT images and identified abnormalities in the sinuses and correlations between orbital complications and rhinosinusitis. Seventeen patients who did not show rhinosinusitis on CT were excluded. One hundred and thirty-one patients with orbital complications arising from dacryocystitis ( $n=114$ ), skin infection ( $n=15$ ), or other causes ( $n=2$ ) were also excluded. Preseptal cellulitis, commonly categorized as a skin infection, was included in our analysis as one of the orbital complications originating from ARS, classified according to Chandler's classification I [5]. Finally, eighteen patients were included out of the initial

176 patients (Fig. 1). The continuous data are presented as means $\pm$ standard deviation and categorical data are presented as number and percentages.

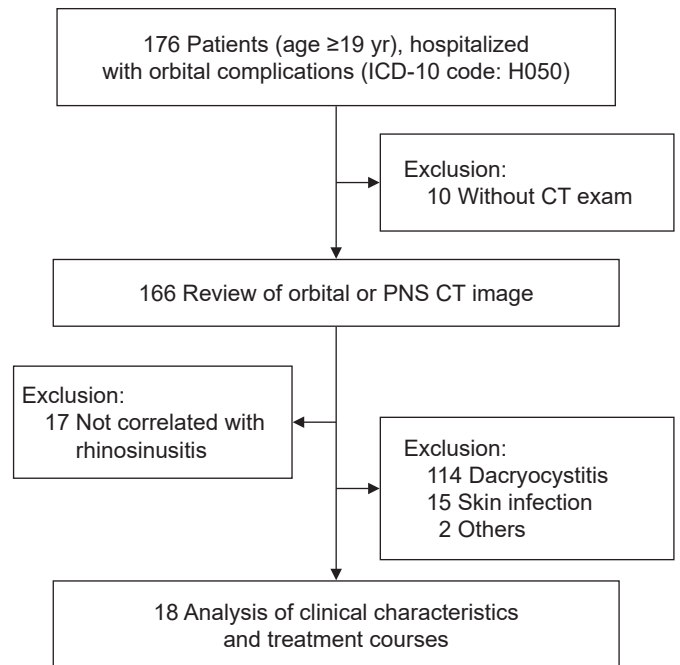
## Results

### 1. Demographic characteristics

A total of 18 patients (8 males and 10 females) with a mean age of  $53.2\pm 18.9$  years (range, 19–88 years) were included in this study. Pretreatment findings for the enrolled patients according to orbital complications are summarized in Table 1. Among them, seven patients had right-sided involvement and eleven patients had left-sided involvement. Three patients (16.7%) had a history of sinus surgery, and 14 patients (77.8%) were previously healthy. Among the underlying diseases, three patients had hypertension, and one patient was a carrier of the hepatitis B virus.

### 2. Clinical presentation

The most common chief complaint was periorbital swelling and pain, with mean onset time of  $2.2\pm 1.9$  days (range, 0–8 days) prior (Fig. 2). Other complaints included upper



**Fig. 1.** A schematic illustration of the participant selection process in the present study. ICD-10, International Classification of Diseases, tenth revision; CT, computed tomography; PNS, paranasal sinus.

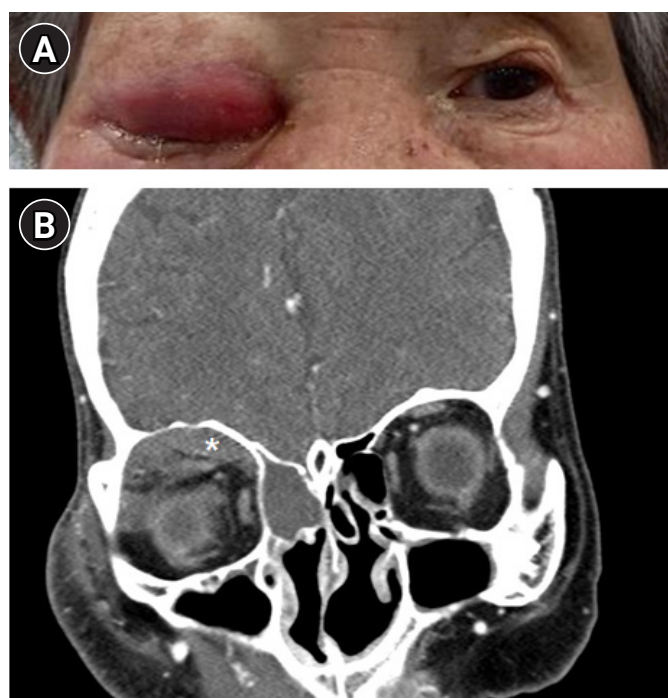**Table 1.** Demographic and clinical characteristics of patients

Characteristic	Preseptal cellulitis	Orbital cellulitis	Subperiosteal abscess	Total
No. of patients	5	8	5	18
Male sex	2 (40.0)	5 (62.5)	1 (20.0)	8 (44.4)
Age (yr)	51.6±23.7 (19–77)	48.9±19.7 (19–77)	64.6±11.4 (51–82)	53.2±18.9 (19–88)
Right side	2 (40.0)	3 (37.5)	2 (40.0)	7 (38.9)
Previous sinus surgery	1 (20.0)	0	2 (40.0)	3 (16.7)
Underlying diseases	0	2 (25.0) <sup>a)</sup>	2 (40.0) <sup>b)</sup>	4 (22.2)
Duration of periorbital swelling and pain (day)	2.4±1.1 (1–4)	2.5±2.2 (0–8)	1.6±0.9 (1–3)	2.2±1.9 (0–8)
Upper respiratory infection symptoms	0	2 (25.0)	3 (60.0)	5 (27.8)
Toothache	0	2 (25.0)	0	2 (11.1)
Diplopia	1 (20.0)	0	3 (60.0)	4 (22.2)
Reduced visual acuity	0	0	1 (20.0)	1 (5.6)
Involvement of sinuses				
Maxillary sinus	4 (80.0)	8 (100)	4 (80.0)	16 (88.9)
Ethmoid sinus	5 (100)	4 (50.0)	5 (100)	14 (77.8)
Frontal sinus	3 (60.0)	2 (25.0)	3 (60.0)	8 (44.5)
Hospital stay (day)	6.2±3.3 (3–11)	8.5±5.3 (5–22)	15.2±5.5 (9–24)	10.3±6.0 (3–24)

Values are presented as number (%) or mean±standard deviation (range).

<sup>a)</sup>Hepatitis B virus (n=1), hypertension (n=1).

<sup>b)</sup>Hypertension (n=2).



**Fig. 2.** Initial clinical presentation. (A) Preoperative photograph showing right periorbital swelling and erythema. (B) Computed tomography scan illustrating a subperiosteal abscess (indicated by an asterisk). The patient provided written informed consent for the publication and use of images.

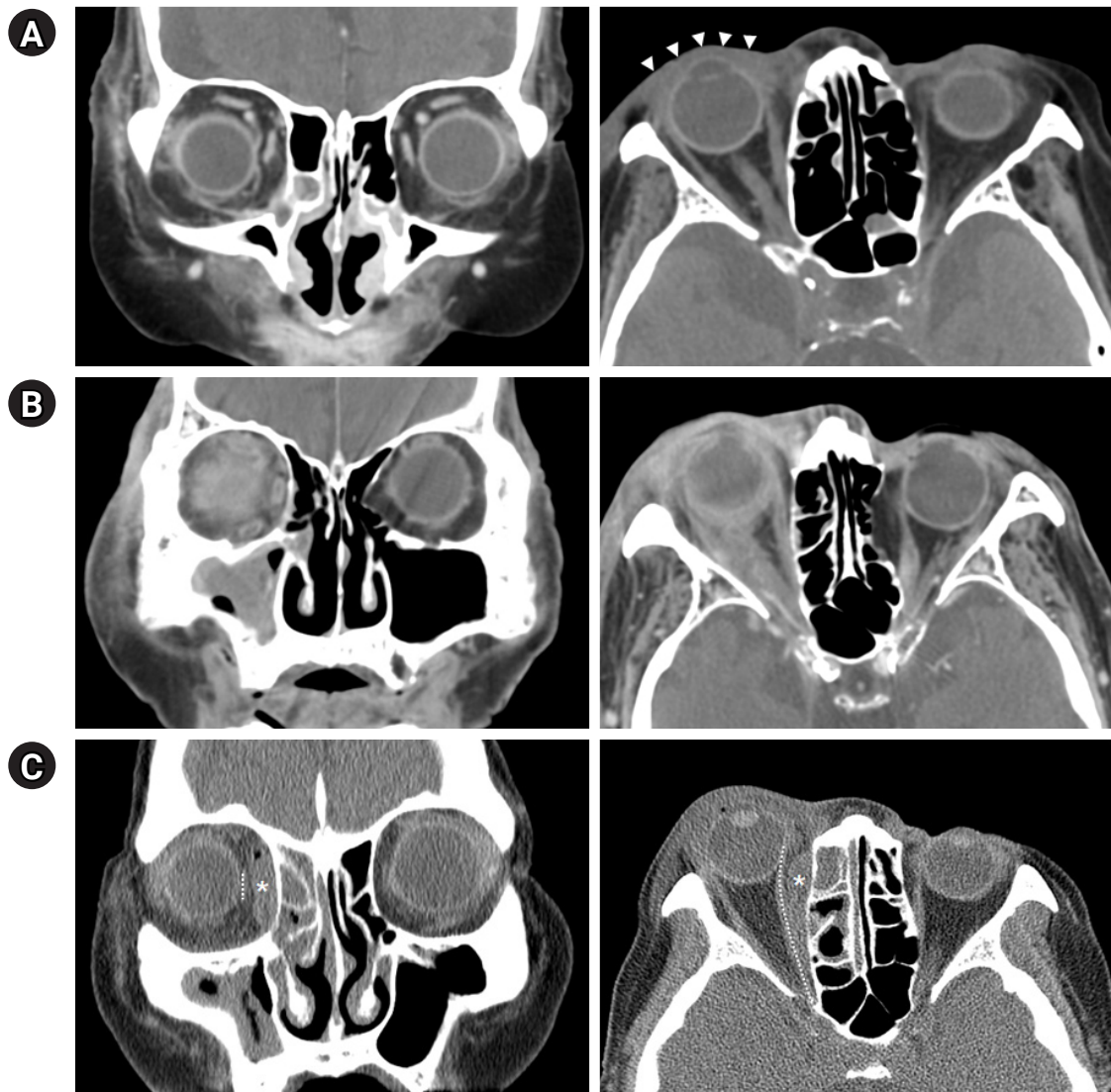
respiratory tract infection symptoms including cough, rhinorrhea or sputum (n=5) and toothache (n=2). The most common diagnoses were orbital cellulitis (n=8, 44.4%) (Fig. 3B), followed by preseptal cellulitis (n=5, 27.8%) (Fig. 3A), and subperiosteal abscess (n=5, 27.8%) (Fig. 3C). On initial ophthalmology examination, four patients (22.2%) had diplopia, and one (5.6%) had reduced visual acuity.

### 3. Laboratory findings

Findings from CT scans of paranasal sinus or orbit showed that the maxillary sinus was involved in 16 patients (88.9%), the ethmoid sinus in 14 (77.8%), and the frontal sinus in eight (44.5%). The culture results showed the presence of *Streptococcus pneumoniae* and *Prevotella intermedia* in only two patients each. However, no specific pathogens were identified in the results for the remaining patients (Table 1).

### 4. Management

The mean hospitalization period was 10.3±6.0 days (range, 3–24 days). Among the patients with pre-septal cellulitis, five were managed with medical treatment only. Among those with orbital cellulitis, seven were managed with medical treatment only, and one required surgical intervention. Among those with subperiosteal abscess, three underwent



**Fig. 3.** Representative computed tomography findings of right orbital complications originating from acute rhinosinusitis according to Chandler's classification. (A) Preseptal cellulitis (stage I) displays periorbital soft tissue swelling with inflammation confined to the eyelids and periorbital tissues on the axial view (arrowheads). (B) Orbital cellulitis (stage II) demonstrates the extension of inflammation beyond the eyelids to involve the orbit without abscess formation. (C) Subperiosteal abscess (stage III, marked with an asterisk) is located between the periosteum and the orbital bone, resulting in compression of the right medial rectus muscle (dotted line).

endoscopic sinus surgery, and two underwent both endoscopic sinus surgery and external drainage (Table 2). Ceftriaxone was the most used antibiotic (11 patients), followed by cefotaxime (6 patients) and ampicillin/sulbactam (1 patient). The mean timing of surgical drainage after admission was  $1.4 \pm 1.9$  (range, 0–4 days).

## Discussion

In this retrospective observational cohort study, we investigated the clinical characteristics and treatment outcomes of adult patients diagnosed with orbital complications resulting from ARS. Our findings elucidate this relatively unexplored area and provide valuable insights into patient management. Notably, there have been no reported cohort studies specifically focused on adult orbital complications



**Table 2.** Overview of clinical data related to subperiosteal abscesses

Patient no.	Sex	Age (yr)	Hospital stay (day)	Follow-up (mo)	Gaze restriction	Proptosis (right/left, mm)	Extraocular muscle(s) involved	Orbital fat involved	Sinus involved	Treatment
1	Male	59	16	1.5	Yes	Yes (12/17)	SO, MR, IR, LR	Yes	M, E, F	ESS, EX
2	Female	51	14	3	No	-	MR	No	M, E	ESS
3	Female	82	13	3.5	Yes	Yes (16/13)	SO, SR, MR	Yes	E, F	ESS
4	Female	66	24	1.5	Yes	No (19/18)	MR, IR	Yes	M, E	ESS, EX
5	Female	65	9	1.5	Yes	-	SO, SR, MR	No	M, E, F	ESS

SO, superior oblique; MR, medial rectus; IR, inferior rectus; LR, lateral rectus; SR, superior rectus; M, maxillary sinus; E, ethmoid sinus; F, frontal sinus; ESS, endonasal sinus surgery; EX, external drainage via transconjunctival approach.

of ARS. Furthermore, since 2009, no original reports have been published regarding orbital complications arising from ARS in adults. This cohort study represents the longest observation period conducted at a single institution. Based on data from a previous study on the Korean adult population from January 1985 through December 2007 [6-10], the mean incidence was 1.4 patients per year, ranging from 0.2 to 2.9. Interestingly, our study yielded a similar incidence of orbital complications of ARS in adults.

ARS is a common condition that can lead to serious complications, including orbital complications, which are particularly concerning due to the potential for vision loss or life-threatening outcomes. The increased susceptibility of children to orbital complications can be attributed to several anatomical differences between pediatric and adult populations, compounded by the heightened prevalence of upper respiratory infections in children [11]. Children typically exhibit diploic-type facial bones and thinner bony separation, coupled with increased vascularity, rendering them more vulnerable to the development of orbital complications. Furthermore, previous studies on pediatric populations found male dominance in orbital complications. The demographic characteristics of the study cohort revealed a relatively equal distribution between males and females, with a mean age of 53.2 years. While orbital complications are known to occur more frequently in pediatric populations, our study demonstrates that they can also affect adults, highlighting the importance of understanding this condition in all age groups.

The majority of patients were previously healthy, emphasizing that even individuals without underlying health issues are at risk of developing serious complications following ARS. Numerous studies have explored the various risk factors associated with these complications. A prior investigation

suggested that ethmoid sinusitis, male gender, dehiscence of lamina papyracea due to congenital defects or prior sinus surgery, and younger age (below 18 years) were positively correlated with ARS leading to orbital complications. Contrarily, allergic rhinitis did not exhibit any significant association with such complications [12]. Despite the abundance of studies exploring potential risk factors, a clear consensus on the definitive factors contributing to the development of ARS-related orbital complications remains elusive.

The predominant chief complaint among the patients was periorbital swelling and pain, which is consistent with previous literature on orbital complications of rhinosinusitis. In addition to periorbital swelling and pain, patients exhibited orbital symptoms such as diplopia, gaze restriction, and changes in visual acuity. These symptoms demonstrated a potential for rapid progression, underscoring the need for prompt diagnosis and intervention to avoid further deterioration and associated complications. While suspicion of an orbital complication is crucial with such symptoms, CT is considered the gold standard for diagnosis. In terms of imaging findings, CT revealed involvement of the maxillary and ethmoid sinuses in a significant proportion of patients, which is in line with the anatomical proximity of these sinuses to the orbit. Our findings corroborate previous studies, indicating a higher prevalence of orbital complications arising from maxillary and ethmoid sinusitis [12]. Frontal sinus involvement was observed in fewer patients, possibly due to the relatively less common occurrence of frontal sinusitis compared to maxillary and ethmoid sinusitis.

The identification of causative pathogens through culture results showed the presence of *S. pneumoniae* and *P. intermedia*, highlighting the importance of appropriate antibiotic selection in the management of these cases. While pathogens such as *Streptococcus milleri*, *Streptococcus pyo-*

genes, *Streptococcus viridans*, *Staphylococcus aureus*, *Haemophilus influenza*, and various anaerobes are recognized as potential contributors, the isolation of pathogens from abscesses may sometimes prove challenging [13]. In the current study, ceftriaxone emerged as the most frequently prescribed antibiotic, followed by cefotaxime and ampicillin/sulbactam. Antibiotic selection should be guided by the suspected or identified pathogens and their sensitivity profiles to ensure effective treatment.

Appropriate timing of surgical intervention was essential to optimize outcomes for patients requiring drainage procedures. Medical treatment alone was sufficient for some patients, particularly those with preseptal cellulitis, while others required surgical intervention, including endoscopic sinus surgery and external drainage for subperiosteal abscess cases. EPOS 2020 suggests that for orbital complications except for preseptal cellulitis, surgical drainage is recommended if there is no response to intravenous antibiotics within 48 hours [1]. In the present study, surgical interventions were eventually required for five patients with subperiosteal abscess.

Our study has several limitations that should be acknowledged. First, the retrospective nature of the study introduces inherent biases and limitations in data collection. Second, the relatively small sample size may limit the generalizability of our findings to larger populations. Third, the study was conducted at a single institution, potentially affecting the diversity and representation of cases. Nevertheless, this study provides valuable insights into the clinical characteristics and treatment outcomes of adult patients with orbital complications resulting from acute bacterial rhinosinusitis. The findings emphasize the significance of early recognition and prompt management of these complications to prevent severe consequences. Future prospective studies with larger, multicenter cohorts are warranted to further validate and expand on our findings and to develop evidence-based guidelines for managing these challenging cases. Improved understanding and management of adult orbital complications of ARS will contribute to better patient outcomes and reduce the burden of this condition on healthcare systems.

## Article information

### Conflicts of interest

No potential conflict of interest relevant to this article was reported.

### Funding

This study was supported by the Basic Science Research Program through the National Research Foundation of Korea (NRF) funded by the Ministry of Education (grant number: NRF-2022R1C1C1004860 to Yung Jin Jeon).

### Author contributions

Conceptualization: YJJ. Data curation: YJJ, WJ. Formal analysis: YJJ. Funding acquisition: YJJ. Investigation: WJ, YHJ, HJC, SWK. Methodology: WJ, YHJ, HJC, SWK. Project administration: YJJ. Resources: YJJ. Software: YJJ. Supervision: YJJ. Validation: YJJ. Visualization: YJJ. Writing - original draft: YJJ, WJ. Writing - review & editing: YJJ. Approval of final manuscript: all authors.

### ORCID

Yung Jin Jeon, <https://orcid.org/0000-0002-0285-5534>

Woohyen Jin, <https://orcid.org/0000-0002-3714-7538>

Yeon-Hee Joo, <https://orcid.org/0000-0003-4011-3475>

Hyun-Jin Cho, <https://orcid.org/0000-0002-6518-351X>

Sang-Wook Kim, <https://orcid.org/0000-0002-1681-0556>

## References

1. Fokkens WJ, Lund VJ, Hopkins C, Hellings PW, Kern R, Reitsma S, et al. European position paper on rhinosinusitis and nasal polyps 2020. *Rhinology* 2020;58(Suppl S29):1–464.
2. DeBoer DL, Kwon E. Acute sinusitis [Internet]. StatPearls Publishing; 2023 [cited 2024 May 11]. <https://pubmed.ncbi.nlm.nih.gov/31613481/>
3. Aring AM, Chan MM. Current concepts in adult acute rhinosinusitis. *Am Fam Physician* 2016;94:97–105.
4. Hoffmans R, Wagemakers A, van Drunen C, Hellings P, Fokkens W. Acute and chronic rhinosinusitis and allergic rhinitis in relation to comorbidity, ethnicity and environment. *PLoS One* 2018;13:e0192330.
5. Chandler JR, Langenbrunner DJ, Stevens ER. The pathogenesis of orbital complications in acute sinusitis. *Laryngoscope* 1970;80:1414–28.

6. Kim YJ, Min YG. Orbital complications of rhinosinusitis: characteristics in pediatric patients. *J Rhinol* 2000;7:109–12.
7. Kim JW, Ahn SK, Jeon SY, Kim JP, Kim BG. Clinical analysis of orbital subperiosteal abscesses as a complication of acute sinusitis. *Korean J Otolaryngol-Head Neck Surg* 2003;46:575–9.
8. Chung SW, Cho JG, Lee SH, Lee SH, Hwang SJ, Lee HM. Clinical analysis of orbital subperiosteal abscess. *J Rhinol* 2005;12:50–4.
9. Oh JH, Cho MJ, Mo JY, Song JW, Kahng H, Kim HJ. Clinical analysis of orbital complications of acute sinusitis according to age. *J Rhinol* 2006;13:22–5.
10. Lim GH, Kim JS, Kim YD, Ye MK, Shin SH. Orbital complications of sinusitis: a retrospective clinical analysis. *J Rhinol* 2009;16:35–8.
11. Dankbaar JW, van Bommel AJ, Pameijer FA. Imaging findings of the orbital and intracranial complications of acute bacterial rhinosinusitis. *Insights Imaging* 2015;6:509–18.
12. Snidvongs K, Chitsuthipakorn W, Akarapas C, Aeumjaturapat S, Chusakul S, Kanjanaumporn J, et al. Risk factors of orbital complications in outpatients presenting with severe rhinosinusitis: a case-control study. *Clin Otolaryngol* 2021;46:587–93.
13. Zhao EE, Koochakzadeh S, Nguyen SA, Yoo F, Pecha P, Schlosser RJ. Orbital complications of acute bacterial rhinosinusitis in the pediatric population: a systematic review and meta-analysis. *Int J Pediatr Otorhinolaryngol* 2020;135:110078.