

엄지의 수근중수관절염에 의한 장무지신건의 특발성 파열: 증례보고

이상기 · 김수민 · 최원식

을지대학교 의과대학 정형외과학교실

Idiopathic Rupture of the Extensor Pollicis Longus Tendon due to Carpometacarpal Joint Arthritis of the Thumb: A Case Report

Sang Ki Lee, Su Min Kim, Won Sik Choy

Departments of Orthopedic Surgery, Eulji University School of Medicine, Daejeon, Korea

A spontaneous rupture of the extensor pollicis longus (EPL) tendon is associated with rheumatoid arthritis, fractures of the wrist, systemic or local steroids, and repetitive and excessive abnormal motion of the wrist joint. Various causes of spontaneous rupture of the EPL tendon have been reported, but EPL rupture due to carpometacarpal (CMC) arthritis has not been reported. We had a case of an idiopathic rupture of the EPL tendon due to CMC joint arthritis of the thumb. The patient had no predisposing factors including trauma or steroid injection. The ruptured tendon was operated. During the surgery, both ends of the ruptured EPL tendon were found around the dorsum of the first CMC joint, and an osteophyte was observed in the dorsal aspect of the first CMC joint. The osteophyte was removed and an extensor indicis proprius tendon transfer was performed. Three monthss post-surgery, the patient was satisfied.

Key Words: Extensor pollicis longus, Spontaneous rupture, CMC arthritis, EIP tendon transfer

The most common cause of extensor pollicis longus (EPL) tendon rupture is a distal radius fracture; however, spontaneous EPL tendon rupture also shows a high frequency of occurrence, which cannot be ignored. A retrospective study of 27 EPL ruptures suggested that trauma or iatrogenic causes account for more than half of the cases, but spontaneous rupture is also considered an important etiological factor¹. The etiology of spontaneous EPL tendon rupture includes systemic or local steroid injections, tenosynovitis, synovitis, rheumatoid arthritis, and repetitive wrist motions².

This report presents a case of idiopathic EPL tendon rupture in a patient who was a daily laborer with repetitive wrist motion. No cases of EPL rupture caused by mechanical attrition due to an osteophyte caused by progression of carpometacarpal (CMC) arthritis, rather than the generally known etiology involving repetitive wrist motions, have been reported yet. Herein, we provide the case report and a review of the literature.

Received April 6, 2018, Revised May 10, 2018, Accepted May 13, 2018

Corresponding author: Sang Ki Lee

Department of Orthopedic Surgery, Eulji University School of Medicine, 95 Dunsanseo-ro, Seo-gu, Daejeon 35233, Korea
TEL: +82-42-611-3288, FAX: +82-42-259-1289, E-mail: sklee@eulji.ac.kr

Copyright © 2018 by Korean Society for Surgery of the Hand, Korean Society for Microsurgery, and Korean Society for Surgery of the Peripheral Nerve. All Rights reserved.
This is an Open Access article distributed under the terms of the Creative Commons Attribution Non-Commercial License (<http://creativecommons.org/licenses/by-nc/4.0/>) which permits unrestricted non-commercial use, distribution, and reproduction in any medium, provided the original work is properly cited.

CASE REPORT

A 42-year-old man visited our hospital complaining of limited thumb extension for six months, without trauma history. The patient had not received any injection since the onset of symptoms. As a daily laborer, he was a worker on a construction site for 8 hours a day, 5 to 6 days a week for a total of 15 years. Physical examination

was performed on the right wrist and a 1×1 cm mass was palpated around the first CMC joint of the right wrist, with tenderness. Plain radiography was performed, from which the osteophyte was suspected around the dorsum of the first CMC joint (Fig. 1A, B). Magnetic resonance imaging of the right wrist revealed an osteoarthritic change around the first CMC joint and a subcortical cyst on the first metacarpal base (Fig. 1C) and the osteophyte

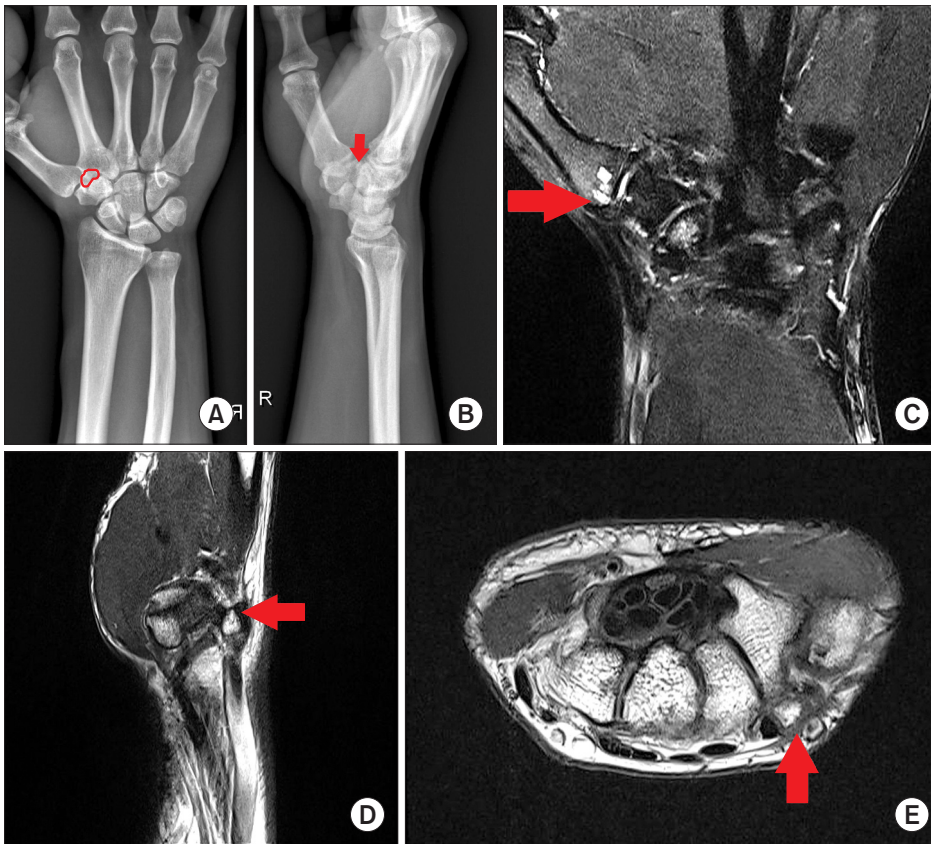


Fig. 1. On plain radiographs, an osteophyte (circle&arrow) is suspected around the dorsum of the right first CMC joint. (A, B) on the right wrist magnetic resonance imaging, osteoarthritic changes and subchondral cysts of the first metacarpal base (arrow) are observed around the first CMC joint (C) and the osteophyte (arrow) in the dorsum of the first CMC joint (D, E). CMC: carpometacarpal.

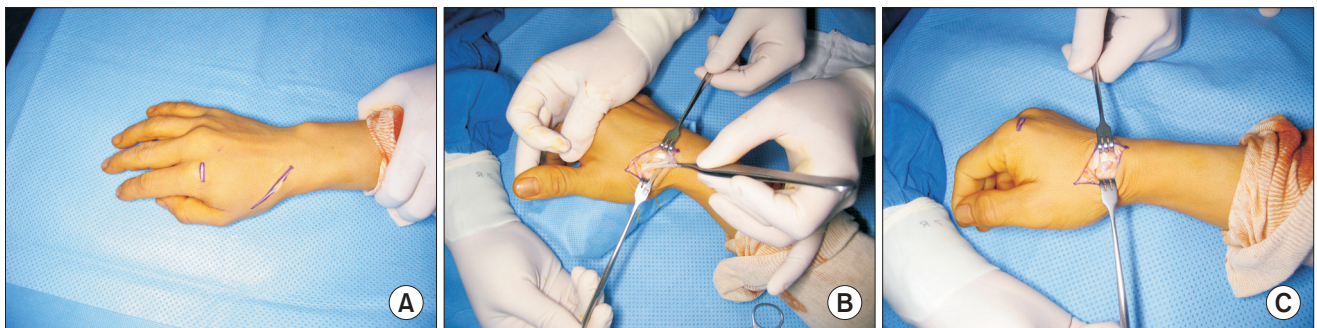


Fig. 2. (A) An incision was made in the anatomical snuff box of the hand following the running of the extensor pollicis longus tendon and dorsum of the second metacarpophalangeal joint. (B) In the incision of the anatomical snuff box, we identified only the tendon sheath where the tendon parenchyma itself does not exist. (C) We found the osteophyte in the dorsum of the first carpometacarpal joint.

in the dorsum of the first CMC joint (Fig. 1D, E). A chronic rupture of the EPL tendon around the dorsum of the first CMC joint was observed.

Surgery was performed by placing a tourniquet around the upper arm under regional anesthesia. An incision was made in the anatomical snuff box of the hand following the running of the EPL tendon (Fig. 2A). We found both ends of the ruptured EPL tendon (Fig. 2B), as well as the osteophyte in the dorsum of the first CMC joint (Fig. 2C), which was removed with an osteotome and rongeur. After removal, osteophyte was confirmed by histologic examination.

Tendon transfer using extensor indicis proprius (EIP) tendon was performed because the injured tendon could not be repaired end-to-end. A short incision was made

over the index metacarpophalangeal joint, and the EIP tendon was divided immediately proximal to the extensor hood. The EIP tendon was delivered into the incision made in the anatomical snuff box, and along with its muscle, it was freed of soft tissue attachments. The tendon was then transferred to the distal stump of the EPL tendon by using Pulvertaft's technique (Fig. 3).

Postoperative short arm thumb spica splint was applied for 4 weeks with the wrist in near full extension and the thumb extended and abducted. Then the thumb was gradually permitted to move with the wrist splinted in extension for another 4 weeks. Independent flexion and extension of the thumb was possible compared with the other side at the third postoperative month (Fig. 4A) and there was no recurrence of the osteophyte at the CMC joint of the thumb on computed tomography of the right wrist (Fig. 4B). It is scheduled to be followed regularly in the outpatient department in the future.

DISCUSSION

Spontaneous rupture of the EPL tendon is relatively common. Although it is mostly an inflammatory response, systemic or local steroid injections are considered one of the major causative factors. The most closely associated inflammatory disease is rheumatoid arthritis. Spontaneous rupture of the EPL tendon can also be caused by tophaceous gout infiltration, ankylosing spondylitis, wrist fractures, bone spurs developing after metastatic distal radius or scaphoid fractures, misplaced external fixators or metal plates, non-metastatic distal radius or scaphoid

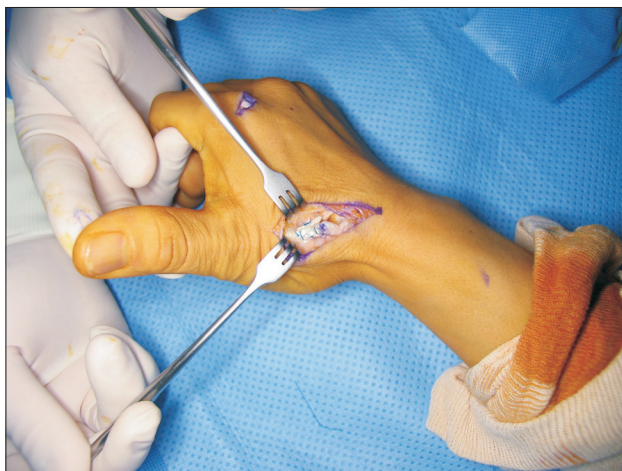

Fig. 3. The extensor indicis proprius tendon was transferred to the distal stump of the extensor pollicis longus tendon by using Pulvertaft's technique.

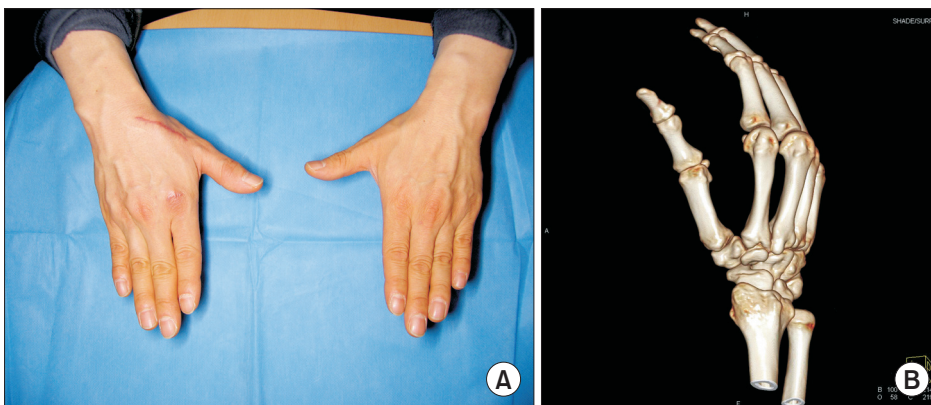


Fig. 4. Three months after the operation, the patient was examined in the outpatient clinic. The patient was allowed full extension of the right thumb (A) and there was no recurrence of the osteophyte at the carpometacarpal joint of the thumb on computed tomography of the right wrist (B).

fractures, prolonged nonunion of the scaphoid, dorsal subluxation of the distal ulna after trauma, and Madelung's deformity¹⁻⁴.

Moreover, the nutrition impairment theory is the main theory describing the cause of spontaneous tendon ruptures, and increased pressure on Lister's tubercle has been reported to lead to ischemia and subsequent spontaneous rupture of the EPL tendon⁵. The other mechanisms are nutrition impairment, pressure caused by necrosis, a sharp fragment of bone that erodes the tendon, crushing injury, non-union of Lister's tubercle, a roughened area of the radius caused by attrition of the tendon, repetitive activities that cause tenosynovitis, or a combination of these mechanisms⁶.

In contrast, there are a few reports concerning EPL tendon ruptures caused by repeated abnormal movements of the wrist joint. A case of spontaneous rupture of EPL due to repetitive movements in a housewife was reported². Another study reported a case of a spontaneous rupture of EPL due to repetitive movements in a tailor⁴.

A case of spontaneous rupture of the EPL tendon in a patient without severe trauma or inflammatory diseases, Lister's tubercle abnormalities, synovitis, or tenosynovitis was reported and the author concluded that EPL tendon rupture could occur without trauma due to attrition of the tendon around Lister's tubercle, regardless of age⁷. This conclusion was supported by other studies on EPL tendon ruptures in sports athletes who were engaged in excessive use of the wrist⁸.

CMC arthritis is the second most common arthritis afflicted by osteoarthritis⁹. It is widely known that use of the basal joint in work-related mechanical loading is one of the risk factors for CMC arthritis. Typical patients, especially men, have history of repetitive occupational joint use. Radiographic findings are considered in the diagnosis, and Eaton and Glickel's classification system is widely used to define the degree of severity of CMC arthritis. As the CMC arthritis progresses, the size of the osteophyte or joint fragment also increases¹⁰.

In the present study, a solid mass on the right wrist was identified on physical examination, which was later found to be an osteophyte of the first CMC joint, which

was in the second stage of Eaton and Glickel's classification system as per radiologic evaluation. The patient, being a daily worker, had a history of repeated wrist motion, which is a risk factor for CMC arthritis and an etiology of idiopathic EPL rupture. This suggests that the EPL tendon caused mechanical attrition with the osteophyte of the CMC joint, resulting in rupture of the EPL tendon spontaneously, because the EPL tendon passes over the dorsum of the first CMC joint after a sharp turn at Lister's tubercle.

Hence, we suggest that in cases of a suspicion of EPL tendon rupture without trauma history, the patient's occupation and history of repetitive wrist motion should be checked, in addition to the patient's medication history, including local steroid injection, and systemic disease such as rheumatoid arthritis, ankylosing spondylitis, and gout. If CMC arthritis is diagnosed, accurate physical examinations and stage evaluation of the disease should be undertaken. When planning the treatment, in addition to surgery for the ruptured tendon, careful treatment of CMC arthritis may improve the patient's pain and functional satisfaction.

CONFLICT OF INTEREST

The authors have nothing to disclose.

REFERENCES

1. Björkman A, Jörgsholm P. Rupture of the extensor pollicis longus tendon: a study of aetiological factors. *Scand J Plast Reconstr Surg Hand Surg*. 2004;38:32-5.
2. Taş S, Balta S, Benlier E. Spontaneous rupture of the extensor pollicis longus tendon due to unusual etiology. *Balkan Med J*. 2014;31:105-6.
3. Hung JY, Wang SJ, Wu SS. Spontaneous rupture of extensor pollicis longus tendon with tophaceous gout infiltration. *Arch Orthop Trauma Surg*. 2005;125:281-4.
4. Choi JC, Kim WS, Na HY, et al. Spontaneous rupture of the extensor pollicis longus tendon in a tailor. *Clin Orthop Surg*. 2011;3:167-9.
5. Engkvist O, Lundborg G. Rupture of the extensor pol-

- licis longus tendon after fracture of the lower end of the radius--a clinical and microangiographic study. *Hand*. 1979;11:76-86.
6. Fujita N, Doita M, Yoshikawa M, Fujioka H, Sha N, Yoshiya S. Spontaneous rupture of the extensor pollicis longus tendon in a professional skier. *Knee Surg Sports Traumatol Arthrosc*. 2005;13:489-91.
7. Zvijac JE, Janecki CJ, Supple KM. Non-traumatic spontaneous rupture of the extensor pollicis longus tendon. *Orthopedics*. 1993;16:1347-50.
8. Lloyd TW, Tyler MP, Roberts AH. Spontaneous rupture of extensor pollicis longus tendon in a kick boxer. *Br J Sports Med*. 1998;32:178-9.
9. Nicholas RM, Calderwood JW. De la caffinière arthroplasty for basal thumb joint osteoarthritis. *J Bone Joint Surg Br*. 1992;74:309-12.
10. Martou G, Veltri K, Thoma A. Surgical treatment of osteoarthritis of the carpometacarpal joint of the thumb: a systematic review. *Plast Reconstr Surg*. 2004;114:421-32.

엄지의 수근중수관절염에 의한 장무지신건의 특발성 파열: 증례보고

이상기 · 김수민 · 최원식

을지대학교 의과대학 정형외과학교실

장무지신건의 자발성 파열은 류마티스 관절염, 손목의 골절, 전신 혹은 국소 스테로이드, 그리고 손목 관절의 반복적이고 과도한 움직임과 관련이 있다. 장무지신건의 자발적 파열에 대한 다양한 원인들이 보고되어왔으나, 수근중수관절염에 의한 장무지신건의 파열은 보고되지 않았다. 저자들은 엄지의 수근중수관절염에 의해 발생한 장무지신건의 특발성 파열에 대한 증례를 경험하였다. 환자는 외상, 스테로이드 주사와 같은 기왕력은 없었다. 파열된 건에 대해 수술을 시행하였다. 수술 중, 첫 번째 수근중수관절의 배부에서 장무지신건의 파열된 양측 말단 및 관절의 배부에서 골편이 관절되었다. 골편은 제거되었고 시지신근을 이용한 건이전술을 시행하였다. 수술 3개월 후, 환자는 우측 엄지의 신전기능을 회복하였고 그에 대해 만족하였다.

색인단어: 장무지신건, 자발성 파열, 수근중수관절 관절염, 시지신근이전술

접수일 2018년 4월 6일 **수정일** 2018년 5월 10일

게재확정일 2018년 5월 13일

교신저자 이상기

35233, 대전시 서구 둔산서로 95, 을지대학교 의과대학 정형외과학교실

TEL 042-611-3288 **FAX** 042-259-1289 **E-mail** sklee@eulji.ac.kr