

사마귀양암종으로 발생한 발뒤꿈치 연부 조직 결손의 재건

안승기¹ · 최환준¹ · 장시형²

순천향대학교 의과대학 ¹성형외과학교실, ²병리학교실

Reconstruction of Heel Defect Occured by Verrucous Carcinoma

Seung Ki Ahn¹, Hwan Jun Choi¹, Si Hyong Jang²

Departments of ¹Plastic and Reconstructive Surgery and ²Pathology, College of Medicine, Soonchunhyang University, Cheonan, Korea

Verrucous carcinoma is a low-grade, well differentiated uncommon variant of squamous cell carcinoma and may grow large and can destroy adjacent tissue such as bone and cartilage. A 45-year-old male patient presented with chief complaints of growth mass of the left foot. He is known diabetic, hypertensive, chronic venous insufficiency and related ulcerations on the lower legs. There is a tender, ulcero-proliferative mass on foot. The result of biopsy showed a highly differentiated verrucous carcinoma. At first the patient underwent wide excision and biopsy with mesh split thickness skin graft. But after 4 months that surgery, verrucous carcinoma recurred with ulceration. Because tumor infiltrated the soft periosteal tissues and calcaneus, he need flap coverage or amputation. We decide to reconstruct heel with anterolateral thigh perforator free flap. The goal of heel reconstruction should be functional and aesthetic. Below knee amputation was not performed, so the patient's quality of life increased.

Key Words: Verrucous carcinoma, Anterolateral thigh free flap, Heel defect, Amputation, Diabetic foot

Verrucous carcinoma is a low-grade, well differentiated, uncommon variant of squamous cell carcinoma¹. It is also referred to as Ackerman's tumor because it was first described by Ackerman in 1948^{2,3}. The age of presentation ranges from 50 to 80 years, with a median age of 67 years, and it shows a male predominance⁴. The most common site of involvement is the oral mucosa⁵. It may occur in the head, neck region, and the genitalia. The

extremities are an unusual site of occurrence⁶. Verrucous carcinoma may grow very large and destroy adjacent tissues such as bone and cartilage. Surgery is considered as the treatment of choice. The extent of the surgical margin and the use of adjuvant radiotherapy are still controversial. Verrucous carcinoma on the foot is unusual.

Received July 24, 2017, Revised [1] August 13, 2017, [2] October 20, 2017, [3] December 2, 2017, [4] December 11, 2017, [5] January 9, 2018, [6] January 23, 2018, Accepted January 24, 2018

Corresponding author: Hwan Jun Choi

Department of Plastic and Reconstructive Surgery, Soonchunhyang University Cheonan Hospital, 31 Suncheonhyang 6-gil, Dongnam-gu, Cheonan 31151, Korea

TEL: +82-41-570-2195, FAX: +82-41-574-6133, E-mail: medi619@schmc.ac.kr

This work was supported by the Soonchunhyang University Research Fund.

Copyright © 2018 by Korean Society for Surgery of the Hand, Korean Society for Microsurgery, and Korean Society for Surgery of the Peripheral Nerve. All Rights reserved.

This is an Open Access article distributed under the terms of the Creative Commons Attribution Non-Commercial License (<http://creativecommons.org/licenses/by-nc/4.0/>) which permits unrestricted non-commercial use, distribution, and reproduction in any medium, provided the original work is properly cited.

CASE REPORT

A 45-year-old male patient presented with a growth over the shin of the left foot that had been growing in size over the past three years accompanied by pain for the past month. Past history revealed that he was a smoker and an alcoholic for the past 20 years. He had diabetes mellitus and hypertension. The patient had chronic venous insufficiency and ulcerations on the lower legs. There was a tender caulicle over an ulcero-proliferative-like growth with

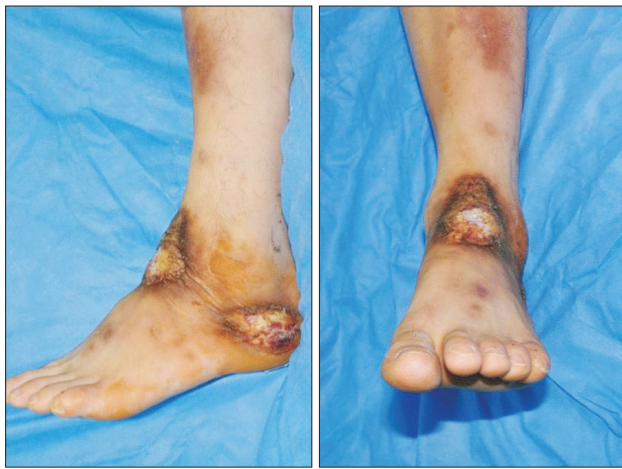

Fig. 1. Preoperative image of the ulcerative masses on both the ankle and heel.

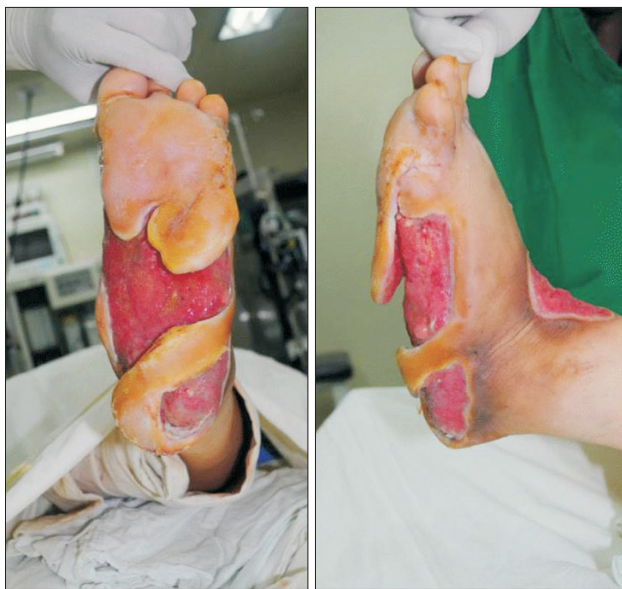

Fig. 2. After wide excision of the mass on the left foot and debridement.

a diameter of 4.5×4.0 cm on the left ankle and one with a diameter of 5.0×3.0 cm on foot (Fig. 1). Initially, laser therapy was done because the histology of the excisional biopsy specimen of the foot showed chronic inflammation. However, the wound increased progressively. After two months, the patient presented with painful discharge and swelling without bleeding, and was mobile over underlying structures. He underwent debridement with marginal excision, and multiple biopsies (Fig. 2). The histology of an excisional biopsy of the foot showed a highly differentiated verrucous carcinoma (formerly referred to as papillomatosis cutis carcinoides) as well as a *Pseudomonas aeruginosa* infected tissue. At first, the patient underwent wide excision and biopsy with mesh split thickness skin graft. No post-operative complication was noted after three months. But four months post-surgery, the skin graft of heel was lost with ulceration (Fig. 3). We did an excision and biopsy of the heel pad, and found that verrucous carcinoma has recurred. On microscopy, the tumor was seen to be composed of well-differentiated squamous epithelium with downward growth pattern exhibiting bulbous pushing margin, suggesting verrucous carcinoma (Fig. 4). The tumor infiltrated the soft periosteal tissues and calcaneus. The patient was advised below knee amputation (BKA) but did not consent. Thus, heel reconstruction with an anterolateral thigh (ALT) perforator free flap was performed instead. The primary goal of

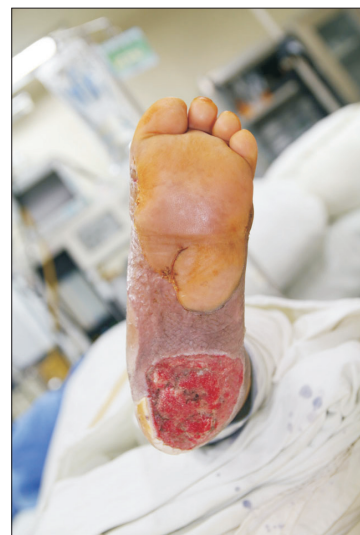

Fig. 3. Recurrence of verrucous carcinoma on the heel.

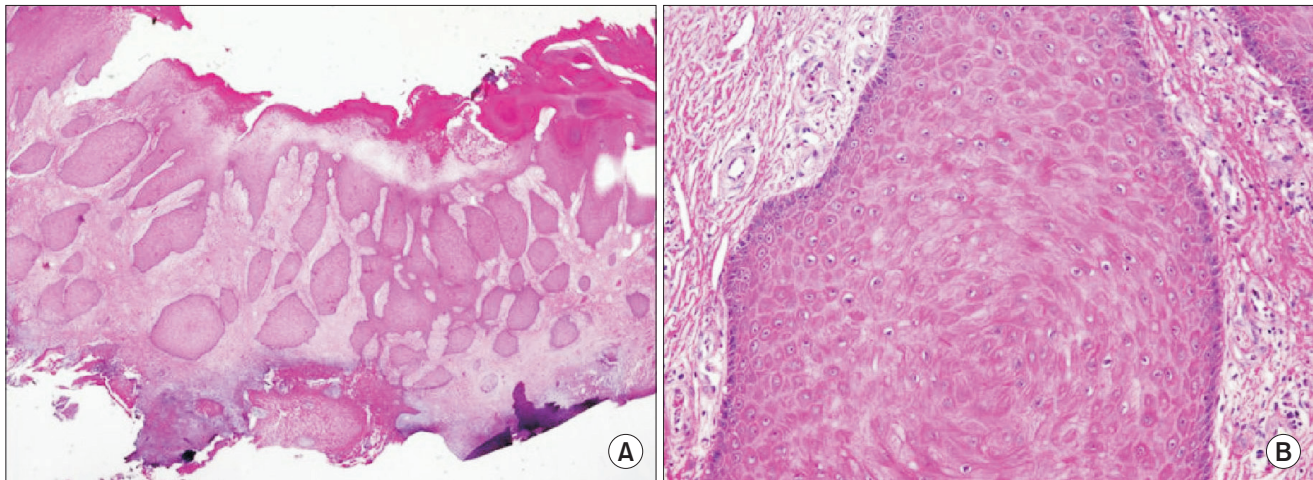


Fig. 4. (A) The tumor showed a downward growing solid bulbous infiltrative nest (H&E, $\times 12.5$). (B) The tumor consisted of well differentiated squamous cells (H&E, $\times 400$).

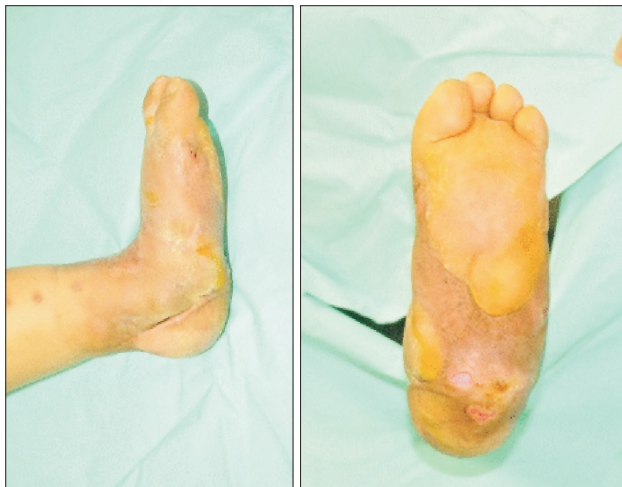

Fig. 5. After 1 year follow-up of anterolateral thigh free flap operation.

lower extremity reconstruction is to recover and maintain function wherein skeletal reconstruction with stable soft-tissue coverage is essential. In this aspect, ALT free flap can be a good option. Because the patient was diabetic, he was not an ideal candidate for vessel, but anastomosis of one artery and two veins was done. We used the posterior tibial artery for arterial anastomosis, and the flap size was 7.0×15.0 cm. Post-operatively, discharge was noted from the operative site due to osteomyelitis, but all the flaps survived well with dressing (Fig. 5). Furthermore, no notable complications were seen at the donor site of the flap and vessel, which suggests a successful healing

process.

DISCUSSION

In a patient with diabetic foot, fungal infection, callus formation, squamous cell carcinoma, and verrucous carcinoma occur frequently. Verrucous carcinoma of the foot is an uncommon low-grade variant of squamous cell carcinoma characterized by local aggressive clinical behavior but with a low potential for metastasis⁷. Verrucous carcinoma is a rare variant of squamous cell carcinoma. Past history of hyperthyroidism (increased appetite, loss of weight, tremors, and menorrhagia) may be present. The most common location of verrucous carcinoma is the oral cavity, and extra-oral sites such as the genitalia, but is rare on the foot. Verrucous carcinoma is often related to skin infection⁸; thus, it is essential to obtain a complete history to assess host risk factors, and wound healing⁹. Because of thin skin and subcutaneous tissue, and small foot muscles, focal carcinoma lesion is often complicated by local infection¹⁰. Wide local excision is the treatment of choice. There are various methods for the reconstruction of defects. The goal of heel reconstruction should be functional and aesthetic. These goals can be achieved by providing the heel with a durable and comfortable weight-bearing surface, adequate contour, protective sensation, and a solid anchor to deep tissue to resist shear-

ing. Various flaps such as fascio-cutaneous, musculo-cutaneous, or split skin grafted muscle flaps have been reported for the reconstruction of the weight-bearing foot. The perforator flap; however, deserves attention because of its anatomical characteristics. This study suggests that the ALT perforator free flap is a reliable option for heel reconstruction, resulting in acceptable functional and aesthetic outcome. In this case, a large defect occurred after wide excision. Because the tumor infiltrated the soft periosteal tissues and calcaneus, the patient needed flap coverage or amputation. BKA was not performed; thus, the patient's quality of life improved. In addition, this case shows that reconstruction using ALT free flap can be performed if the pedicle is stable even when a patient is in a poor condition.

CONFLICTS OF INTEREST

The authors have nothing to disclose.

REFERENCES

1. Abhivardhan D, Bhadram V, Kumar S, Jagadeesh AB, Sushma P. Verrucous carcinoma of the leg - a rare variant of squamous cell carcinoma in an unusual site: a case report. *Int J Sci Stud*. 2015;3:128-30.
2. Ackerman LV. Verrucous carcinoma of the oral cavity. *Surgery*. 1948;23:670-8.
3. Steffen C. The man behind the eponym: Lauren V. Ackerman and verrucous carcinoma of Ackerman. *Am J Dermatopathol*. 2004;26:334-41.
4. Tornes K, Bang G, Strømme Koppang H, Pedersen KN. Oral verrucous carcinoma. *Int J Oral Surg*. 1985;14:485-92.
5. Medina JE, Dichtel W, Luna MA. Verrucous-squamous carcinomas of the oral cavity. A clinicopathologic study of 104 cases. *Arch Otolaryngol*. 1984;110:437-40.
6. Delahaye JF, Janser JC, Rodier JF, Auge B. Cuniculatum carcinoma. 6 cases and review of the literature. *J Chir (Paris)*. 1994;131:73-8.
7. Green JG Jr, Ferrara JA, Haber JA. Epithelioma cuniculatum plantare. *J Foot Surg*. 1987;26:78-83.
8. Ascione T, Iannece MD, Rosario P, et al. Impact of therapeutic choices on outcome of osteomyelitis caused by MRSA. *J Infect*. 2011;63:102-4.
9. Tiemann AH, Hofmann GO. Principles of the therapy of bone infections in adult extremities: are there any new developments? *Strategies Trauma Limb Reconstr*. 2009;4:57-64.
10. Wright PK, Vidyadharan R, Jose RM, Rao GS. Plantar verrucous carcinoma continues to be mistaken for verruca vulgaris. *Plast Reconstr Surg*. 2004;113:1101-3.

사마귀양암종으로 발생한 발뒤꿈치 연부 조직 결손의 재건

안승기¹ · 최환준¹ · 장시형²

순천향대학교 의과대학 ¹성형외과학교실, ²병리학교실

사마귀양암종은 편평상피암의 분화도가 높은 저등급 종류 중 흔하지 않은 종으로, 매우 크게 성장하여 뼈나 연골 같은 인접 조직들을 파괴할 수 있다. 45세의 만성 질환을 가진 남자 환자가 왼쪽 발의 종괴를 주소로 내원하였다. 조직 병리학적 검사상 분화도가 높은 사마귀양암종으로 판명되어 광범위 절제술 및 그물망 부분층 피부이식을 시행하였다. 4개월 후 발뒤꿈치의 피부이식 부분이 궤양으로 손실되었고 암이 재발한 것을 확인하였다. 암이 발뒤꿈치뼈와 골막조직에도 침범을 하였기 때문에, 피판술 혹은 절단이 고려되어야 했다. 발뒤꿈치의 재건은 기능적인 면과 미용적인 면이 모두 고려되어야 하며 내구성이 있고 편안하게 무게를 지탱할 수 있는 피판술이 시행되어야 한다. 하퇴아래절단을 시행하지 않고 전외측대퇴부 유리 피판술을 통해 만족스러운 결과를 얻어 삶의 질을 향상시킬 수 있었다.

색인단어: 사마귀양암종, 전외측대퇴부 유리 피판술, 발뒤꿈치 피부결손, 절단술, 당뇨발

접수일 2017년 7월 24일 **수정일** 1차: 2017년 8월 13일, 2차: 2017년 10월 20일, 3차: 2017년 12월 2일, 4차: 2017년 12월 11일, 5차: 2018년 1월 9일, 6차: 2018년 1월 23일

게재확정일 2018년 1월 24일

교신저자 최환준

31151, 충남 천안시 동남구 순천향6길 30, 순천향대학교 의과대학 성형외과학교실

TEL 041-570-2195 FAX 041-574-6133 E-mail medi619@schmc.ac.kr