

공기주입 구혈대로 인한 상지마비 2예: 예방을 위한 수칙

김현석 · 김영호

단국대학교 의과대학 성형외과학교실

Two Cases of Pneumatic Tourniquet Paralysis: Points for Prevention

Hyonsurk Kim, Young Ho Kim

Department of Plastic and Reconstructive Surgery, Dankook University College of Medicine, Cheonan, Korea

Although nerve injury is the most common complication of pneumatic tourniquets, it is said to be rare, with few case reports. We describe two cases of paralysis after upper extremity surgery to highlight this risk. Ulnar, median and radial neuropathies were diagnosed after surgery was performed on a man for left hand reconstruction, presumably due to a prolonged total inflation time of 14 hours despite conventional break times. A woman who received surgery for a crushed hand presented with radial neuropathy, the most probable cause being malfunction and automatic inflation of the tourniquet. These cases illustrate the diversity of tourniquet paralysis, with symptomatic progress not necessarily following electromyography results. The considerable discomfort to patients warrants careful use of tourniquets for neuropathy prevention.

Key Words: Upper extremity, Radial neuropathy, Ulnar neuropathy, Tourniquet

Pneumatic surgical tourniquets, first introduced by Harvey Cushing in 1904, are widely used in extremity surgery to maintain a bloodless operative field. However, even when properly used and controlled, both local and systemic complications can occur¹. The most common complications observed in clinical settings are neurological injuries, which, although still rare, can also be the most devastating¹⁻³. We present two cases of neurological deficit of more than six months' duration following upper extremity surgery to highlight the risk and scope of such injuries.

CASE REPORT

1. Case 1

Several surgical procedures were performed on a 33-year-old male with no medical histories requiring secondary reconstruction on his left hand (Fig. 1). During the 17-hour prolonged surgery, a single tourniquet was inflated to 250 mmHg for six 2-hour periods with 30-minute breaks between each inflation, for a total ischemic time of 14 hours. Immediately after surgery, weakness of the left elbow, wrist and hand occurred, including

Received October 25, 2018, Revised October 27, 2018, Accepted November 4, 2018

Corresponding author: Hyonsurk Kim

Department of Plastic and Reconstructive Surgery, Dankook University Hospital, 201 Manghyang-ro, Dongnam-gu, Cheonan 31116, Korea
TEL: +82-41-550-6285, FAX: +82-41-556-0524, E-mail: kruezel@gmail.com

Copyright © 2018 by Korean Society for Surgery of the Hand, Korean Society for Microsurgery, and Korean Society for Surgery of the Peripheral Nerve. All Rights reserved.
This is an Open Access article distributed under the terms of the Creative Commons Attribution Non-Commercial License (<http://creativecommons.org/licenses/by-nc/4.0/>) which permits unrestricted non-commercial use, distribution, and reproduction in any medium, provided the original work is properly cited.

hampered wrist and ulnar digit extension. The patient felt difficulty in maintaining elbow flexion against gravity and required an arm sling. These signs were accompanied by diminished sensation. Physiotherapy with range-of-motion (ROM) exercises were started. Motor and sensory weakness gradually improved, and one month after surgery the patient no longer required the arm sling. However as he regained sensation, tingling and pins and needles occurred with increasing intensity. Two weeks after surgery the patient was started on gabapentin, tramadol and acetaminophen to control the tingling pain. Tingling and allodynia peaked at two months and then started to im-

prove, with the forearm almost free of symptoms by three months.

Electromyography (EMG) and nerve conduction studies performed three months after surgery revealed ulnar, median and radial neuropathies at the upper arm with predominant involvement of sensory fibers, and median and lateral antebrachial cutaneous neuropathies. At four months the forearm and wrist had recovered most sensory functions except for cold sensation. At postoperative six months motor and sensory function had recovered sufficiently to cause no discomfort in everyday life, however allodynia and tingling pain requiring medication persisted for over three years. One year follow-up EMG studies suggested improvement of median and ulnar neuropathies but no significant interval change of radial and antebrachial cutaneous neuropathies. These findings did not match the clinical state of the patient, who had fully recovered all motor function by this time.

2. Case 2

A 45-year-old woman with a history of right nephrectomy and chronic kidney disease (CKD) required delayed coverage for a crushed index finger. A medial sural artery perforator free flap was planned. Both donor and recipient dissection proved difficult, resulting in a prolonged surgical time of 19 hours, during which a tourniquet was inflated three times (one 60-minute session and two 30-minute sessions) to 250 mmHg for a

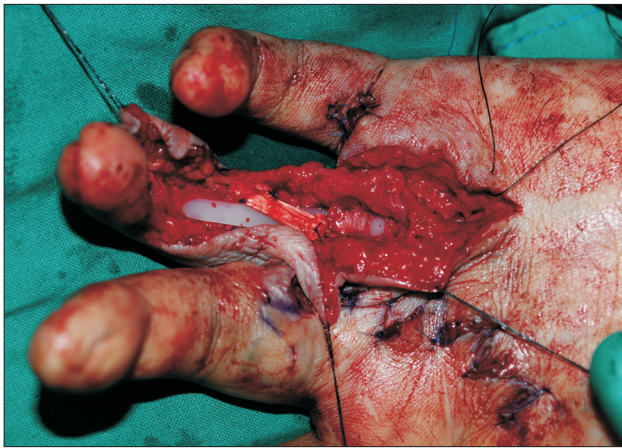


Fig. 1. Multiple Z-plasties for scar contracture release, neurolysis, Hunter rod insertion, pulley reconstruction, and osteotomy with autologous bone grafting were performed on a 33-year-old male for secondary hand reconstruction, which amounted to a total operative time of 17 hours (Case 1).

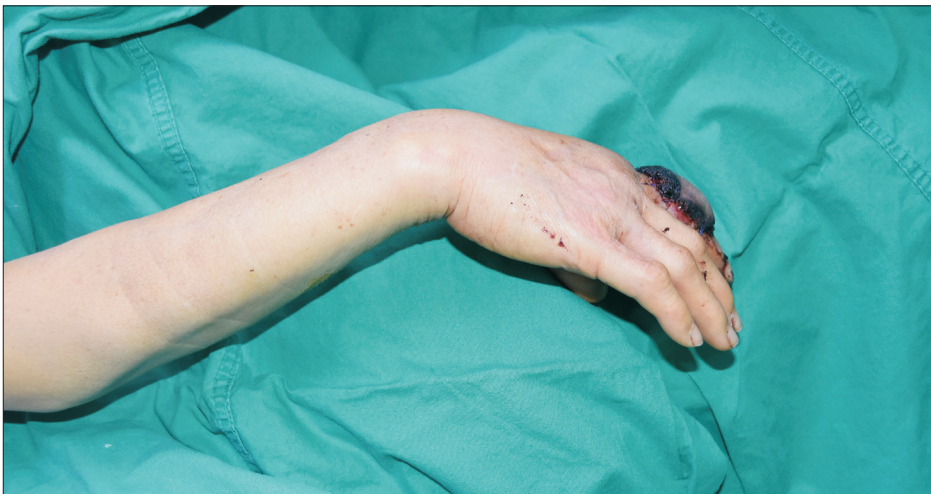

Fig. 2. After a prolonged free flap surgery of 19 hours, during which a tourniquet was inflated for less than two hours, wrist-drop and loss of finger extension accompanied by sensory change appeared in a 45-year-old woman (Case 2).



Fig. 3. One year later, with conservative treatment, the patient had almost fully recovered motor function except for joint stiffness in the reconstructed finger. Clinical improvement preceded recovery of electromyography results.

total of 120 minutes. Break time between each inflation was at least 20 minutes. Postoperative wrist-and finger-drop and cramping pain with tingling followed (Fig. 2). Splinting, physiotherapy and ROM exercises were prescribed. Nerve conduction studies performed two weeks after surgery revealed radial neuropathy at the upper arm with nearly complete axonotmesis. Five month follow-up nerve studies presented no interval changes, however the patient had significantly recovered motor function by that time. The patient, who had required oral gabapentin for six months to control the tingling and cramping pain, was almost free from these symptoms at eight months. By one year the patient had almost fully recovered motor function, and no sensory problems were observed above the wrist level; remnant sensory symptoms below the wrist were probably the result of surgical incisions and initial trauma (Fig. 3). Follow-up nerve conduction and EMG studies performed at this time suggested an improved but incomplete recovery state of the radial neuropathy.

DISCUSSION

Reports on upper limb paralysis after tourniquet use in surgery, first presented 130 years ago by Montes and Putnam, have become very rare since pneumatic tourniquets became common^{4,5}. The first reference was from Bruner in 1951, and in this case, as in several others reported later, a faulty pressure gauge was presumed to have led to

excessive cuff pressure^{4,5}. The incidence of nerve injury varies between 0.1%-7.7% in the literature^{1,5}. The reasons for this wide variation probably lies in underdiagnosis of mild injury. Postoperative limb weakness from muscle injury, rapid recovery of the nerve, and the fact that many patients are in splints or casts can easily lead to overlooked cases^{3,6}. Subtle or even subclinical lesions only detectable by nerve conduction and EMG studies may also occur more frequently than anticipated⁷. Thankfully, prognosis is generally good, usually recovering within six months with rare permanent deficits⁴.

Although the exact pathophysiology of tourniquet-associated neurological injury is not yet clear, it is generally suggested that mechanical compression and shearing forces have a more important role than ischemia^{3,5,6}. Most nerve damage occurs directly under and near the edges of the cuff, due to myelin disturbance and disruption of the nodes of Ranvier^{3,6}. Both longer durations and higher pressures are associated with increased risk of nerve injury, however safe duration and pressure guidelines remain controversial². A safe continuous inflation limit of 1.5-3 hours has generally been suggested, with a deflation break of 10-15 minutes every one to two hours for reperfusion, but concrete rules have not been definitely established^{2,3}. Surgeons commonly inflate tourniquets to a fixed pressure (250 mmHg for the upper extremity) or to a fixed amount of pressure (100 mmHg) above systolic blood pressure. These practices are not ideal, and

cases have been reported after using tourniquets within these guidelines, as was in both of our cases^{2,4,5,7}. Recent recommendations call for tourniquet inflation according to the limb occlusion pressure (LOP) at which the distal arterial blood flow (assessed by a Doppler probe) is occluded, and for deflation after 90 minutes for at least 10 minutes. A safety margin (according to the LOP) from 40 to 80 mmHg is added to the LOP for tourniquet pressure; for pediatric patients, a margin of 50 mmHg has been recommended^{2,3}.

In case 1, although each inflation session was within two hours, the prolonged 14-hour total inflation time was suspected as the main reason for nerve injury. According to Horlocker et al.⁸, nerve dysfunction risk significantly increases with total tourniquet time and deflation breaks only modestly decrease this risk. In situations similar to case 1 where protracted total tourniquet time is anticipated, using two tourniquet cuffs with alternate inflation at 1-hour intervals can reduce direct pressure time at each cuff¹. In case 2, despite the short tourniquet time, the patient may have been relatively vulnerable to nerve damage due to her general condition with stage 4 CKD¹. Moreover, there was an intra-operative episode of accidental automatic tourniquet inflation; the possibility of multiple or prolonged malfunction events such as this during the tedious donor site dissection as the main reason for nerve damage cannot be ruled out, which highlights the importance of regularly checking equipment maintenance^{5,6}. Other standard safety measures, such as using the widest contoured cuff possible, ensuring good padding beneath the cuff, applying to the proximal part of the limb with the greatest circumference (for more muscle bulk protection), and minimizing tourniquet time by making skin markings and other planning before inflation should always be implemented^{1,2,3,7}.

There were discrepancies in clinical recovery and EMG findings in both of our cases, with near-total symptomatic recovery while EMG findings suggested only partial improvement. Apart from neurological recovery, other factors such as adaptive biomechanical changes, functional compensation, muscle substitution patterns and overlapping contribution from other nerves could have also been

involved in improved strength and function while the affected nerves were still healing⁹.

These cases demonstrate the diverse clinical presentation of tourniquet paralysis, with symptomatic progress not necessarily following EMG results. Though symptoms resolve over time, the considerable discomfort to patients warrants careful use of tourniquets with preventive measures against such neuropathies.

CONFLICTS OF INTEREST

The authors have nothing to disclose.

ACKNOWLEDGEMENTS

The present research was conducted by the research fund of Dankook University in 2017. The authors have no other conflicts of interest to disclose.

The patients provided written informed consent for the publication and the use of their images.

REFERENCES

1. Wakai A, Winter DC, Street JT, Redmond PH. Pneumatic tourniquets in extremity surgery. *J Am Acad Orthop Surg*. 2001;9:345-51.
2. Sharma JP, Salhotra R. Tourniquets in orthopedic surgery. *Indian J Orthop*. 2012;46:377-83.
3. Van der Spuy L. Complications of the arterial tourniquet. *South Afr J Anaesth Analg*. 2012;18:14-8.
4. Rudge P. Tourniquet paralysis with prolonged conduction block. An electro-physiological study. *J Bone Joint Surg Br*. 1974;56:716-20.
5. Aho K, Sainio K, Kianta M, Varpanen E. Pneumatic tourniquet paralysis. Case report. *J Bone Joint Surg Br*. 1983;65:441-3.
6. Estebe JP, Davies JM, Richebe P. The pneumatic tourniquet: mechanical, ischaemia-reperfusion and systemic effects. *Eur J Anaesthesiol*. 2011;28:404-11.
7. Mingo-Robinet J, Castañeda-Cabrero C, Alvarez V, León Alonso-Cortés JM, Monge-Casares E. Tourniquet-related iatrogenic femoral nerve palsy after knee surgery: case

- report and review of the literature. *Case Rep Orthop.* 2013;2013:368290.
8. Horlocker TT, Hebl JR, Gali B, et al. Anesthetic, patient, and surgical risk factors for neurologic complications after prolonged total tourniquet time during total knee arthroplasty. *Anesth Analg.* 2006;102:950-5.
9. Feinberg J. EMG: myths and facts. *HSS J.* 2006;2:19-21.

공기주입 구혈대로 인한 상지마비 2예: 예방을 위한 수칙

김현석 · 김영호

단국대학교 의과대학 성형외과학교실

공기주입 구혈대 사용 시 가장 흔히 발생할 수 있는 합병증인 신경손상은 실제 발생은 드물며 발표된 증례도 많지 않다. 저자들은 상지 수술 후 발생한 신경손상 2예를 통해 이러한 위험을 알리고자 한다. 좌수 재건을 위해 수술을 받은 남성 환자에서 통상적인 감압 휴지기를 가졌음에도 불구하고 요골, 정중, 그리고 척골 신경의 손상이 확인되었고 이는 14시간의 총 누적 적용 시간으로 인한 결과로 추정되었다. 수부 압궤손상으로 재건 수술을 받은 여성 환자는 요골 신경 손상이 발생하였으며 수술 중 구혈대의 오작동으로 인한 사례로 추정되었다. 이 증례들은 구혈대로 인한 신경손상의 다양한 임상소견이 신경검사 결과와 불일치할 수 있으며, 장기간 불편을 야기하는 이 합병증을 예방하기 위해 구혈대 사용 시 주의를 요할 점들을 시사해준다.

색인단어: 상지, 요골신경손상, 척골신경손상, 구혈대

접수일 2018년 10월 25일 수정일 2018년 10월 27일 게재확정일 2018년 11월 4일

교신저자 김현석

31116, 충남 천안시 동남구 망향로 201, 단국대학교병원 성형외과

TEL 041-550-6285 FAX 041-556-0524 E-mail kruezel@gmail.com