

# 온도 감응형 유착 방지제의 수근관 유리술 후 임상 결과에 미치는 효과

차수민 · 신현대

충남대학교 의과대학, 충남대학교병원 권역 류마티스 및 퇴행성 관절염센터 정형외과

## Effects of a Temperature-sensitive, Anti-adhesive Agent on the Clinical Outcome of Carpal Tunnel Release Surgery

Soo Min Cha, Hyun Dae Shin

Department of Orthopedic Surgery, Daejeon Rheumatoid and Degenerative Arthritis Center, Chungnam National University Hospital, Chungnam National University School of Medicine, Daejeon, Korea

**Purpose:** We investigated the anti-adhesive effects of a temperature-sensitive poloxamer/alginate mixture (Guardix-SG<sup>®</sup>; Hanmi Medicare Inc., Korea) through a prospective randomized controlled study for carpal tunnel release surgery.

**Methods:** The 47 patients who received the infusion were classified as Group 1, and the 51 patients who did not were classified as Group 2. Basic demographic factors and preoperative clinical status were evaluated. At the postoperative 18 months, the degree of clinical recovery and adhesion around the median nerve for both groups were evaluated and compared using sonography.

**Results:** The clinical outcomes, which were assessed using the six-item carpal tunnel symptoms scale, were not significantly different between the groups. However, sonography showed that adhesions around the median nerve were significantly less common in the infusion group.

**Conclusion:** Although the anti-adhesive effects of the temperature-sensitive Guardix-SG<sup>®</sup> were apparent upon radiological investigation, its use was not associated with a significant difference in clinical outcome on the short-term period follow-up.

**Key Words:** Carpal tunnel syndrome, Transverse carpal ligament, Anti-adhesive agent

## INTRODUCTION

Carpal tunnel syndrome (CTS) is the most common nerve entrapment syndrome of the upper extremities, affecting 1% to 3% of the population<sup>1</sup>. Surgical treatment

of this compressive neuropathy aims to release the transverse carpal ligament (TCL) using various well known methods<sup>2</sup>. Usually these methods yield a satisfactory outcome, but sometimes the results are not as favorable as desired. The causes of unsatisfactory results include

Received April 12, 2018, Revised April 18, 2018, Accepted April 22, 2018

Corresponding author: Hyun Dae Shin

Department of Orthopedic Surgery, Chungnam National University School of Medicine, 266 Munhwa-ro, Jung-gu, Daejeon 35015, Korea  
TEL: +82-42-280-7349, FAX: +82-42-252-7098, E-mail: hyunsd@cnu.ac.kr

Copyright © 2018 by Korean Society for Surgery of the Hand, Korean Society for Microsurgery, and Korean Society for Surgery of the Peripheral Nerve. All Rights reserved.  
This is an Open Access article distributed under the terms of the Creative Commons Attribution Non-Commercial License (<http://creativecommons.org/licenses/by-nc/4.0/>) which permits unrestricted non-commercial use, distribution, and reproduction in any medium, provided the original work is properly cited.

recurrence due to adhesion of the median nerve, incomplete release of the ligament, or injury of the cutaneous sensory branches.

Postoperative adhesions are a major concern in many types of surgery including that of the abdomen, breast (particularly augmentation), urogenital tract, and in ophthalmic and orthopedic/plastic neural surgeries. Many factors have been suggested as triggers of adhesion formation including foreign materials (e.g., starch, surgical gloves, and suture materials), infection, and increased duration of surgery<sup>3</sup>. However, even careful management of these factors has not reduced the incidence of adhesions. For example, since 1990, physical barriers have been used to reduce postoperative epidural fibrosis and adhesions after spinal surgery<sup>4-6</sup>. However, for anti-adhesive agents to be beneficial, they need to remain in place until healing begins and then be absorbed into the body. Several types of adhesion barrier bioresorbable membranes have been available since early 2010 and are now widely used. Among them, Guardix-SG<sup>®</sup> (Hanmi Medicare Inc., Seoul, Korea), a temperature-sensitive, anti-adhesive agent, transforms from a solution to a gel at body temperature, enhancing its properties as a physical barrier.

In this study, we evaluated the efficacy of the injection

of this agent into the intracarpal tunnel space just after TCL release to treat CTS. The effects were evaluated both radiologically and clinically through prospective trials.

## MATERIALS AND METHODS

### 1. Patient selection

The Institutional Review Board of Chungnam National University Hospital (IRB No. 2015-04-007) approved the registry, and all of the patients provided informed consent before participation. This study included 132 patients who were diagnosed with CTS between March 2014 and April 2016; they were randomized into two groups using a single-blinded method and allocated using the permuted block method (Fig. 1)<sup>7</sup>. The inclusion criteria were as follows: (1) patients who met the clinical criteria suggested by Graham et al.<sup>8</sup>, (2) positive findings on the electrodiagnostic test (nerve conduction velocity/electromyography), (3) grades 2, 3, or 4 on the Bland scale of electrodiagnostic examination<sup>9</sup>, and (4) no improvement after 6 months of conservative treatments. All of the enrolled patients had been newly diagnosed with

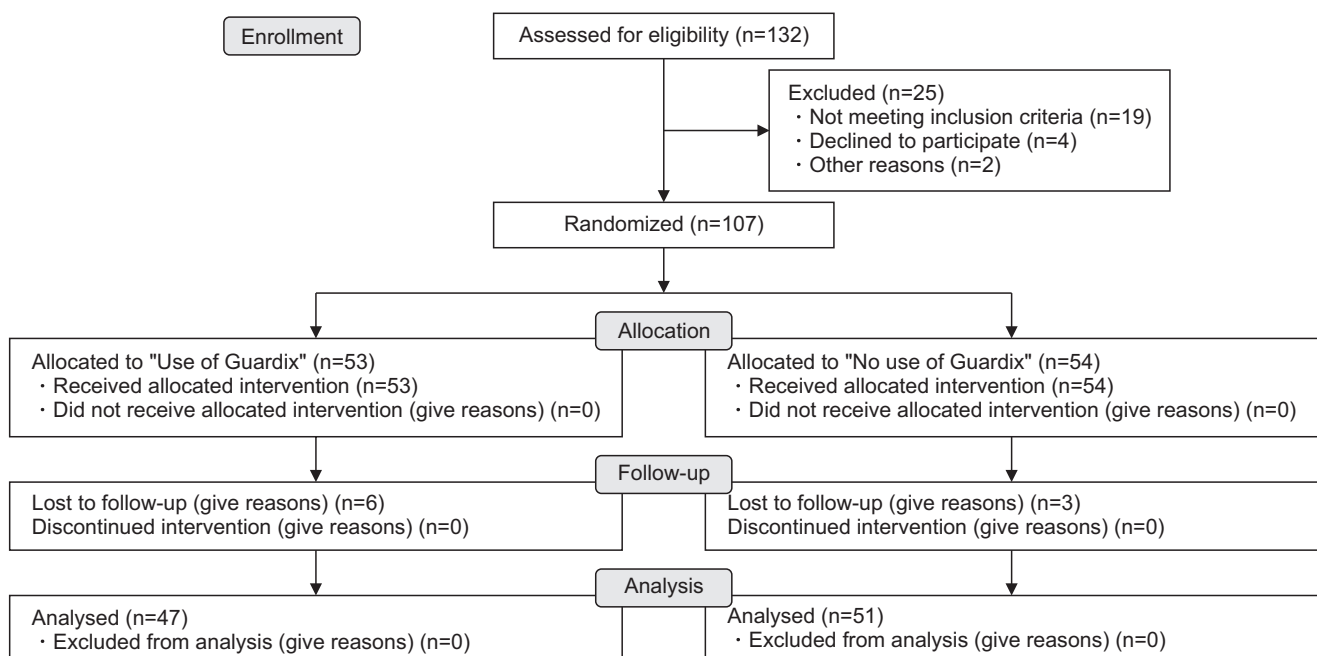


Fig. 1. Flow diagram for our randomized controlled study.

CTS at the authors' institution. We excluded patients with the following characteristics: (1) bilateral CTS, (2) clinical and/or electrodiagnostic findings concurrent with another compressive neuropathy in the ipsilateral upper extremity, (3) the presence of painful osteoarthritic lesions in the elbow, wrist, or finger joints, (4) those undergoing revision surgery, (5) patients with worker's compensation issues, (6) any rheumatic disease diagnosed before surgery, (7) systemic morbidity with abnormalities electrodiagnosis (EDX) such as diabetes mellitus or chronic renal disease, (8) history of trauma to the tendons, ligaments, bones, or neurovascular structures distal to the elbow on the same side, or (9) a history of any surgery in this anatomical area or any congenital or acquired deformity of the elbow, wrist, or hand. Trauma was defined as any condition that resulted in restriction of daily activities of daily life, including employment or sports, even if the trauma required no treatment. A total of 25 patients were excluded and 53 patients and 54 patients were designated into Groups 1 and 2, respectively; 9 patients were lost during follow-up, which left 47 patients (Group 1) and 51 patients (Group 2) for evaluation.

## 2. Randomization and blinding

After enrollment and just prior to the carpal tunnel release, the patients were randomized Group 1 (use of

Guardix-SG<sup>®</sup>) and Group 2 (no use of Guardix-SG<sup>®</sup>) by research coordinators using a random number generator. The patients were allocated in a 1:1 ratio. A senior surgeon were blinded by having him leave the operating room after release the TCL and checking the properly decompressed median nerve. Then, a well trained, qualified orthopedic surgeon without any interaction with these patients, infused Guardix-SG<sup>®</sup> in only the patients allocated with Group 1, then performed skin closure. This orthopedic surgeon was not author of this study and not engaged at the evaluation of outcomes. All personnel with the exception of the coordinators and the surgeon who infused the material were blinded from the surgery to the clinical and radiologic evaluations.

## 3. Demographic variables

We evaluated all of the patients' basic demographic factors including age, sex, onset time, time from diagnosis to surgery, dominant/nondominant wrist, and occupational classification, which was based on The Standard Occupational Classification 2010<sup>10</sup>. This classification is based on two main concepts: the type of work performed (job) and the skill required to perform the duties (Table 1).

**Table 1.** Major Standard Occupational Classification 2010 groups and example occupations

Category	Major occupational group	Example
1	Managers, directors, and senior officials	Chief executives, senior officials, managers in finance, transport, health, social services
2	Professional occupations	Doctors, lawyers, teachers, nurses, social workers, journalists
3	Associate professional and technical occupations	Science, engineering, production technicians, IT technicians
4	Administrative and secretarial occupations	Book keepers, national government administrators, clerks, secretaries
5	Skilled trades occupations	Agriculture, fabrication, machining, transport technicians, electricians, plumbers, construction workers
6	Caring, leisure, and other service occupations	Childcare, nursing auxiliaries, dental nurses, travel agents, hairdressers, beauticians, caretakers
7	Sales and customer service occupations	Cashiers, telephone sales, call centre technicians
8	Process, plant, and machine operatives	Machine operatives, train drivers, fork-lift truck operators, taxi drivers, bus drivers
9	Elementary occupations	Farm workers, cleaners, refuse and salvage occupations, security guards, parking attendants, porters

#### 4. Electrodiagnostic study

Electrodiagnostic examination was performed before surgery in all of the patients, after which disease severity was graded using the Bland scale<sup>9</sup>. Patients with the most common grades of 2, 3, and 4 were included in the current study (Appendix 1).

#### 5. Surgical procedure

All of the patients in both groups underwent mini-open carpal release. After general anesthesia or brachial plexus block, an incision was made about 5 mm ulnar to the thenar crease under an inflated tourniquet. A curvilinear incision of 2 cm was made parallel to the thenar crease, ending just proximal to it. A Senn retractor was used to retract the subcutaneous fatty tissue to expose the proximal portion of the flexor retinaculum and the distal portion of the antebrachial fascia. Then, a number 15 blade was used to carefully open the proximal portion of the flexor retinaculum and the distal portion of the antebrachial fascia. After full inspection of the median nerve and flexor tendons in the tunnel, in Group 1, Guardix-SG<sup>®</sup> was infused into the released carpal tunnel area prior to placing subcutaneous absorbable sutures, while in Group 2, only subcutaneous sutures were placed without infusion of Guardix-SG<sup>®</sup>.

#### 6. Clinical evaluation and comparison

All of the clinical data were evaluated and compared for both groups, immediately before surgery and at the final 6-month follow-up. Six clinical items by Graham et al.<sup>8</sup> were used to evaluate all of the patients for the following symptoms: (1) numbness or tingling in the median nerve distribution; (2) nocturnal numbness; (3) thenar atrophy; (4) Tinel sign; (5) Phalen test; and (6) loss of two-point discrimination (TPD). TPD was assessed using the Mackinnon-Dellon Discriminator (US Neurologicals, Poulsbo, WA, USA) and was recorded as the smallest reliably detectable distance at which two points could be distinguished. Each patient was trained with visual input

to demonstrate the TPD test.

Next, each assessment of each distance was termed a trial, which involved pressing the discriminator into the skin in line with the path of a single digital nerve approximately 5 mm distal to the distal flexion crease. Then Boston carpal tunnel questionnaire (BCTQ) scores were checked immediately before surgery and at the final evaluation after surgery.

#### 7. Evaluation of adhesion around median nerve

Sonographic inspections were performed at 18 months postoperatively. We used the degree of displacement of the median nerve during grip to evaluate postoperative adhesion, as detailed in a recent study<sup>11</sup>. To measure transverse movement of the median nerve, cross-sectional images of the carpal tunnel were obtained by placing the transducer at the proximal carpal tunnel. We defined the proximal carpal tunnel as the transverse line connecting the centre of the scaphoid tubercle and the pisiform on sonography. In addition, we measured the carpal width between the line of the base of the carpal tunnel made by the carpal bones and the perpendicular line of the centre of the scaphoid tubercle to the centre of the pisiform on cross-sectional images. The transducer was maintained as perpendicularly as possible to the nerve, while minimising the compressive force against the wrist. Also, we determined the proper images to measure the distances with full contours of both the scaphoid/pisiform and carpal floor concurrently. Cross-sectional ultrasound images were obtained during the following maximal voluntary motions of the finger and wrist joint, as suggested by Park<sup>12</sup>: (1) Thumb, index finger, and long finger flexion: the wrist was held in a neutral position while the thumb and each finger were moved to maximal flexion, respectively (three motions); (2) Grasp: the wrist was held in a neutral position while all four fingers and the thumb were moved to maximal flexion, forming a fist (one motion); and (3) Wrist ulnar/radial deviation with finger extension: the wrist was moved from a neutral position to maximal ulnar deviation while the fingers were held in full exten-

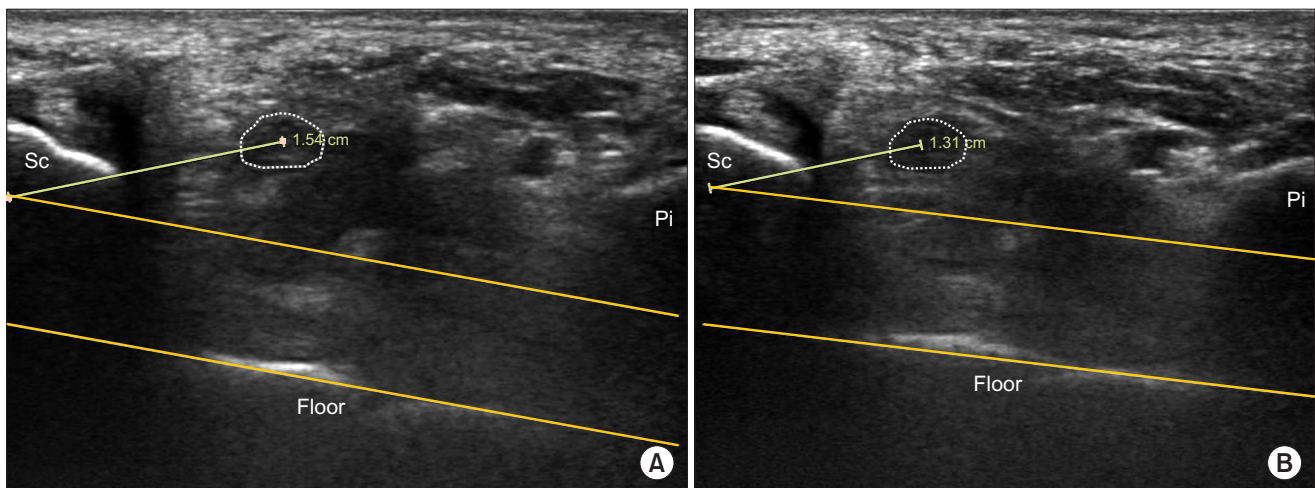
sion, respectively (two motions).

All recorded images were saved in a digital format and evaluated using a PACS program (m-view 5.4; Marosis Technologies Inc., Seoul, Korea). First, we saved the ultrasound image of the median nerve at rest, with the finger extended and wrist in a neutral position. Patients were then asked to produce maximal finger motion in each finger and wrist joint to minimise the bias due to variation in force. Given that it was the end of the median nerve movement, if the median nerve did not move for more than 5 seconds a second image was captured by the PACS system; the median nerve was manually outlined using a digital tool to create a region of interest (ROI) continuous boundary trace along the echogenic boundary of the nerve, and all of the following measurements were made. Then, the maximal movement of the median nerve among the six finger/wrist motions was measured (Fig. 2) as a slight modification of the method used by Wang<sup>11</sup>. All measurements were evaluated by two orthopaedic surgeons, neither of whom was the senior surgeon, and all sonographs were re-evaluated 1 day later by both surgeons. Intra-class correlations coefficient (ICCs) among continuous variables were calculated as measures of inter and intraobserver repeatability<sup>13</sup>. Kappa values were eval-

uated as measures for the categorical variables<sup>13</sup>. Shrout and Fleiss<sup>13</sup> considered a kappa-value  $>0.75$  as excellent,  $0.40-0.75$  as good, and  $<0.40$  as poor.

## 8. Statistical analysis

We prospectively evaluated the patients using a two-sided significance level of 0.05 and a power of 80%. The sample size was calculated using the BCTQ score difference. We used the BCTQ score as the principal outcome and attempted to determine a 5-point mean difference between the two groups (for an effective size of 0.3)<sup>10</sup>. Therefore, a minimum of 41 patients in each group was required for proper statistical comparison between the two groups (power of 80% and 20% maximum follow-up, due to the loss of patients). Continuous variables were compared between the two groups using the independent samples t-test. Sex, hand dominance, and Graham's clinical six-item score<sup>8</sup> (except TPD) were evaluated and compared using Fisher's exact test. The BCTQ scores were also analyzed using the Welch-Aspin test. Data were analyzed using SPSS for Windows (SPSS Inc, Chicago, IL, USA). A p-value  $<0.05$  was considered statistically significant.



**Fig. 2.** Measurement of the distance between the median nerve and the centre of the scaphoid tubercle. First, we identified the floor of the carpal tunnel made by the carpal bones on the images and found the view with the maximal contour of the tubercle of the scaphoid and pisiform. This view was defined as the adequate image for evaluation of the median nerve mobility. (A) The maximal distance between the median nerve and the scaphoid tubercle was measured with the wrist deviated radially and all fingers extended, in this patient. (B) The minimal distance between the median nerve and the scaphoid tubercle was checked with the wrist held in a neutral position while all four fingers and the thumb were maximally flexed. The differences between the measurements were taken as median nerve movement.



## RESULTS

**Table 2.** Basic demographic data between two groups

Variable	Group 1	Group 2	p-value
Age at diagnosis (yr)	58.21±10.84	56.75±7.89	0.44
Sex (Male:Female)	16:31	9:42	0.07
Onset period of symptoms or signs (mo)	15.30±3.49	15.90±2.48	0.32
The time from the diagnosis to the surgery (mo)	6.72±0.80	6.73±0.72	0.99
Site of the lesion (Dominant: Non-dominant)	26:21:00	22:29	0.31

Values are presented as mean±standard deviation or number.

**Table 3.** Differences in the occupational distributions between the two groups

	Category									p-value
	1	2	3	4	5	6	7	8	9	
Group 1	1	3	3	9	11	13	4	3	0	0.14
Group 2	0	7	11	9	8	8	2	3	3	

Values are presented as only number.

Basic demographic characteristics such as age, sex, onset time, time to surgery after diagnosis, dominance, and occupational classification did not differ statistically (Table 2, 3). In addition, the Bland scale results based on EDX were similarly distributed between the two groups ( $p=0.77$ ; Table 4). The clinical status after CTR regarding numbness or tingling, nocturnal numbness, thenar atrophy, Tinel sign and Phalen test was not significantly different between the two groups. Sensory recovery (TPD) evaluated at the thumb, index, long finger, and ring finger was of similar degrees (Table 5). The Boston Carpal

**Table 4.** Comparisons of the preoperative electrodiagnosis graded by the Bland scale

	Scale			p-value
	2	3	4	
Group 1	7	26	14	0.77
Group 2	9	30	12	

Values are presented as only number.

**Table 5.** Comparisons of clinical items using the Graham criteria

Item	Preoperative state/ final follow-up	Group 1	Group 2	p-value
Numbness or tingling	(+)/(+)	6	1	0.08
	(+)/(-)	41	49	
	(-)/(-)	0	1	
Nocturnal numbness	(+)/(+)	0	0	0.23
	(+)/(-)	45	51	
	(-)/(-)	2	0	
Thenar atrophy	(+)/(+)	14	9	0.37
	(+)/(-)	4	5	
	(-)/(-)	29	37	
Tinel	(+)/(+)	18	14	0.06
	(+)/(-)	21	34	
	(-)/(-)	8	3	
Phalen	(+)/(+)	20	17	0.49
	(+)/(-)	19	21	
	(-)/(-)	8	13	
Improvement of two-point discrimination (Preoperative TPD-final TPD)				
Thumb (mm)		0.94±0.82	1.25±1.28	0.14
Index (mm)		1.11±0.91	1.43±0.85	0.07
Long finger (mm)		1.04±1.04	1.37±1.17	0.14
Ring finger (mm)		0.86±0.12	1.00±0.75	0.33

Values are presented as number or mean±standard deviation.

**Table 6.** Comparisons of clinical and radiologic outcomes

Clinical and radiologic outcome	Group 1	Group 2	p-value
Improvement of Clinical outcomes (Preoperative scores-final scores)			
Boston Symptom Scores	17.16±6.41	18.58±3.64	0.19
Boston Function Scores	9.16±4.08	8.93±2.77	0.11
Sonographic measurement at final follow-up (mm)			
Maximal distance of median nerve	16.2±8.4	16.4±7.1	0.25
Minimal distance of median nerve	12.9±11.6	15.2±8.5	<0.001
Movements of median nerve	3.3±1.1	1.2±7.7	<0.001

Values are presented as mean±standard deviation.

Tunnel symptom severity scales and functional status scales also showed no statistical differences (Table 6). However, the movement of the median nerve toward the scaphoid was statistically significantly different in sonographic evaluations. In group 1, the degree of movement was significantly greater during each motion ( $p<0.001$ ). The changes in wrist width during each motion were not significant in either group (Table 6). The ICCs of the continuous variable measurements were all excellent. The kappa-values for the maximum and minimum distances of the median were 0.86 and 0.89, respectively.

## DISCUSSION

Adhesions occur when tissue damaged during surgery secretes factors that activate blood vessels, when inflammatory cells accumulate, and when extracellular matrix formation is accelerated, leading to the formation of fibrotic clots. Then cells such as fibroblasts, macrophages, and giant cells infiltrate to form vascular granulation tissue. Collagen is secreted and connective tissues are formed, all of which eventually result in tissue adhesions<sup>5</sup>. Based on this mechanism, researchers have applied hyaluronic acid carboxymethylcellulose (HACMC) mixtures, both as physical barriers or liquid applications, at the surgical site where adhesions are likely<sup>15</sup>.

As a recent anti-adhesive agent, a temperature-sensitive poloxamer/alginate mixture, Guardix-SG<sup>®</sup>, self-assembles at a specific sol-gel transition temperature and flows into the desired site. This overcomes the disadvantages of traditional HACMC mixtures, which only functions as a barrier. Before injection into the intra-tunnel space,

the material is liquid (viscosity: approximately 3,000 cP at 21°C), allowing easy injection and application into the incision. However, in the carpal tunnel, these materials assume a viscosity of 90,000 to 95,000 cP at 37°C, functioning as a barrier and preventing adhesion at the dissected TCL, similar to their film-type counterparts<sup>16,17</sup>. Through sonographic follow-up, we confirmed significant differences between the two groups with respect to the radiological evidence for adhesions by the mobility of the median nerve within the tunnel during finger/wrist motion. After neural decompression surgery, nerves are more susceptible to recurrent compressive conditions (disc herniation, stenosis) due to adhesions around the nerve that can restrict mobility<sup>19</sup> leading to a poorer clinical outcome than in patients without these adhesions. However, in the current study, despite the significant radiological evidence of postoperative adhesions in the control group, the clinical outcomes evaluated at the postoperative 18 months were not significantly different between the two groups. These findings could have resulted due to several reasons. First, we selected a somewhat homogeneous group of patients for CTR based on EDX, ruling out patients with terminal stage disease based on EDX results because they were less likely to recover. Second, the anatomical features in the carpal tunnel were definitively different from those of the cervical/lumbar region under the process of degeneration, and this was the case even for those structures that had undergone decompressive surgery for the nerve root. Narrow spaces formed by complex structures such as the lamina, pedicle, disc, and degenerative spur are often predisposed to adhesions, decreasing motion of neural tissues and of-

ten leading to a more adverse clinical outcome. Finally, several reports regarding the correlation between clinical recovery and radiological findings, especially with respect to the cross-sectional area (CSA), after carpal tunnel release have been published. Recently, Manni et al.<sup>18</sup> reported that the reduction in CSA was well correlated with the improvement in symptoms and function. However, Kim et al.<sup>20</sup> showed that there was an improvement in symptoms after surgery, but reported no correlation between the values of BCTQ and the median nerve CSA. These were usually, evaluated early on (at 6 months after surgery), and differ from our hypothesis regarding anti-adhesive material preventing postoperative adhesion at least 1 year after surgery.

Appropriate methods for evaluating the degree of soft tissue adhesion in the carpal tunnel have rarely been studied; however, Wang et al.<sup>11</sup> recently showed that sonography was an easy and reliable method to this end. Furthermore, the decrease in maximal movement of the median nerve was strongly associated with the degree of severity on EDX (Bland scale) in the study by Park.<sup>12</sup> In our study, we used a simpler method in which the distance between the centre of the scaphoid and median nerve was directly measured in PACS rather than using the original method by Wang et al.<sup>11</sup> calculated with the Pythagorean Theorem. To minimize errors in distance measurements, several studies have used mechanical devices for wrist fixation. However, sonographic images can be acquired only after meticulous manipulation. Of the six different available postures, we used the largest images of the scaphoid and pisiform as references. We considered that current images would yield reliable measurements, as suggested by Park.<sup>12</sup>

We compared sonographic findings at the postoperative 18 months. Other experimental rabbit studies<sup>4,6,19,21</sup> about the degree of peridural adhesion after using Guardix-SG<sup>®</sup> have lasted usually 4 to 6 weeks to allow time for dense fibrosis to form at the laminectomy site. In addition, previous studies have reported that significant bone regeneration can be seen about 9 weeks postoperatively in rabbit models<sup>22</sup>. However, our study assessed soft tissue adhesions, which take longer to develop, so we evaluated

the clinical outcome at over 1 year as suggested by Park et al.<sup>23</sup> Their experimental study evaluated the effects of a temperature-sensitive poloxamer/alginate mixture used to prevent capsular contracture after silicone implant insertion. The authors defined the proper follow-up time as longer than 6 months postoperatively according to Moufarrege et al.<sup>24</sup>

One important strength of our study was that we compared two groups through a randomized prospective study with critical inclusion/exclusion criteria. In addition, the patients were followed up and evaluated radiologically by a single orthopedic surgeon who was blind to study protocol. The second main strength of the current study was that it was a clinical human study that investigated the results of temperature-sensitive poloxamer/alginate mixture antiadhesives used during surgery, the efficacy of which was revealed radiologically. The anatomical simplicity of the carpal tunnel facilitated postoperative evaluation of radiological adhesions or any decreased of mobility of median nerve during wrist/hand motions.

This study had several limitations. The anti-adhesive effect was determined based on sonographic findings, and not on in situ scoring, as suggested by several authors as related to intraabdominal surgery<sup>25-27</sup>. The area of adhesion dense enough to require sharp dissection could not be evaluated in the carpal tunnel as in the abdomen. Second, our own authors evaluated postoperative adhesions radiologically. Each categorical analysis of the sonographic findings was performed in two planes as accurate 3-dimensional evaluations were impossible.<sup>28</sup> Third, radiological and clinical results were assessed at the first postoperative 18 months; the longer term effects of Guardix-SG<sup>®</sup> were not investigated. Finally, other anthropometric factors, such as individual hand length or width, or postoperative management (hand movements or rehabilitation), may also be relevant. However, we did not evaluate these factors because it was difficult to grade or categorize them among the patients.

## CONCLUSION

In this study, infusion of a temperature-sensitive po-



loxamer/alginate mixture (Guardix-SG®) during carpal tunnel release effectively prevented postoperative neural adhesions as assessed sonographically at 1 year. However, the follow-up period was relatively short and there was not a significant clinical difference with the use of Guardix-SG® to correspond with these findings. Further studies with longer follow-up periods are required to more fully evaluate the clinical benefits of this treatment.

## CONFLICTS OF INTEREST

The authors have nothing to disclose.

## ACKNOWLEDGEMENTS

This research was supported by Hanmi Research Fund, 2015.

## REFERENCES

1. Atroshi I, Gummesson C, Johnsson R, Ornstein E, Ransam J, Rosén I. Prevalence of carpal tunnel syndrome in a general population. *JAMA*. 1999;282:153-8.
2. Mintalucci DJ, Leinberry CF Jr. Open versus endoscopic carpal tunnel release. *Orthop Clin North Am*. 2012;43:431-7.
3. Zavala-Rodriguez JM, Correa Rovelo JM, Martinez-Morales N, et al. Oxylchlorine species suppress postsurgical adhesions in rats. *J Surg Res*. 2014;186:164-9.
4. DiFazio FA, Nichols JB, Pope MH, Frymoyer JW. The use of expanded polytetrafluoroethylene as an interpositional membrane after lumbar laminectomy. *Spine (Phila Pa 1976)*. 1995;20:986-91.
5. Hellebrekers BW, Trimbos-Kemper TC, Trimbos JB, Emeis JJ, Kooistra T. Use of fibrinolytic agents in the prevention of postoperative adhesion formation. *Fertil Steril*. 2000;74:203-12.
6. Liu S, Boutrand JP, Bittoun J, Tadie M. A collagen-based sealant to prevent in vivo reformation of epidural scar adhesions in an adult rat laminectomy model. *J Neurosurg*. 2002;97(1 Suppl):69-74.
7. Doig GS, Simpson F. Randomization and allocation concealment: a practical guide for researchers. *J Crit Care*. 2005;20:187-91; discussion 191-3.
8. Graham B, Regehr G, Naglie G, Wright JG. Development and validation of diagnostic criteria for carpal tunnel syndrome. *J Hand Surg Am*. 2006;31:919-24.
9. Bland JD. Treatment of carpal tunnel syndrome. *Muscle Nerve*. 2007;36:167-71.
10. Cha SM, Shin HD, Ahn JS, Beom JW, Kim DY. Differences in the postoperative outcomes according to the primary treatment options chosen by patients with carpal tunnel syndrome: conservative versus operative treatment. *Ann Plast Surg*. 2016;77:80-4.
11. Wang Y, Zhao C, Passe SM, et al. Transverse ultrasound assessment of median nerve deformation and displacement in the human carpal tunnel during wrist movements. *Ultrasound Med Biol*. 2014;40:53-61.
12. Park D. Ultrasonography of the transverse movement and deformation of the median nerve and its relationships with electrophysiological severity in the early stages of carpal tunnel syndrome. *PM R*. 2017;9:1085-94.
13. Shrout PE, Fleiss JL. Intraclass correlations: uses in assessing rater reliability. *Psychol Bull*. 1979;86:420-8.
14. Fleiss JL, Cohen J. The equivalence of weighted kappa and the intraclass correlation coefficient as measures of reliability. *Educ Psychol Meas*. 1973;33:613-9.
15. Yaacobi Y, Hamed LM, Kaul KS, Fanous MM. Reduction of postoperative adhesions secondary to strabismus surgery in rabbits. *Ophthalmic Surg*. 1992;23:123-8.
16. Naito Y, Shin'oka T, Hibino N, Matsumura G, Kurosawa H. A novel method to reduce pericardial adhesion: a combination technique with hyaluronic acid biocompatible membrane. *J Thorac Cardiovasc Surg*. 2008;135:850-6.
17. Hong JH, Choe JW, Kwon GY, et al. The effects of barrier materials on reduction of pericardial adhesion formation in rabbits: a comparative study of a hyaluronan-based solution and a temperature sensitive poloxamer solution/gel material. *J Surg Res*. 2011;166:206-13.
18. Manni M, Bisaccia M, Rinonapoli G, et al. Reliability, feasibility and value of ecography in clinical-functional results in patients affected by carpal tunnel syndrome: is there a correlation? *Acta Inform Med*. 2017;25:44-8.
19. Shih HN, Fang JF, Chen JH, et al. Reduction in experimental peridural adhesion with the use of a crosslinked hyaluronate/collagen membrane. *J Biomed Mater Res B*

- Appl Biomater. 2004;71:421-8.
20. Kim JK, Koh YD, Kim JO, Choi SW. Changes in clinical symptoms, functions, and the median nerve cross-sectional area at the carpal tunnel inlet after open carpal tunnel release. *Clin Orthop Surg.* 2016;8:298-302.
  21. Park JW, Bak KH, Cho TK, Chun HJ, Ryu JI. Effects of a temperature-sensitive, anti-adhesive agent on the reduction of adhesion in a rabbit laminectomy model. *J Korean Neurosurg Soc.* 2016;59:250-8.
  22. Temel SG, Ozturk C, Temiz A, Ersozlu S, Aydinli U. A new material for prevention of epidural fibrosis after laminectomy: oxidized regenerated cellulose (interceed), an absorbable barrier. *J Spinal Disord Tech.* 2006;19:270-5.
  23. Park SO, Han J, Minn KW, Jin US. Prevention of capsular contracture with Guardix-SG(®) after silicone implant insertion. *Aesthetic Plast Surg.* 2013;37:543-8.
  24. Moufarrege R, Beauregard G, Bosse JP, Papillon J, Perras C. Outcome of mammary capsulotomies. *Ann Plast Surg.* 1987;19:62-4.
  25. Leach RE, Burns JW, Dawe EJ, SmithBarbour MD, Diamond MP. Reduction of postsurgical adhesion formation in the rabbit uterine horn model with use of hyaluronate/carboxymethylcellulose gel. *Fertil Steril.* 1998;69:415-8.
  26. Knightly JJ, Agostino D, Clifton EE. The effect of fibrinolysin and heparin on the formation of peritoneal adhesions. *Surgery.* 1962;52:250-8.
  27. Oncel M, Remzi FH, Senagore AJ, Connor JT, Fazio VW. Liquid antiadhesive product (Adcon-p) prevents post-operative adhesions within the intra-abdominal organs in a rat model. *Int J Colorectal Dis.* 2003;18:514-7.
  28. Presazzi A, Bortolotto C, Zacchino M, Madonia L, Draghi F. Carpal tunnel: Normal anatomy, anatomical variants and ultrasound technique. *J Ultrasound.* 2011;14:40-6.

## 온도 감응형 유착 방지제의 수근관 유리술 후 임상 결과에 미치는 효과

차수민 · 신현대

충남대학교 의과대학, 충남대학교병원 권역 류마티스 및 퇴행성 관절염센터 정형외과

**목적:** 수근관 증후군 수술에서 온도 감응형 poloxamer/alginate (Guardix-SG®; 한미메디케어, 한국) 혼합체의 유착방지 효과에 대하여 전향적 무작위 연구를 시행하였다.

**방법:** 유착 방지제를 사용한 47예를 1군, 사용하지 않은 2예를 2군으로 지정하였다. 두 군 간, 인구학적 인자 및 술 전 임상 상태를 파악하였고 술 후 18개월에 임상 상태의 호전 정도 및 정중 신경 주변의 유착 정도에 대하여 초음파를 이용하여 비교하였다.

**결과:** 6가지 항목으로 비교한 술 후 임상 상태는 두 군 간 차이가 없었으나 초음파로 분석한 정중 신경 주변의 유착 정도는 1군(주입군)에서 의미 있게 적었다.

**결론:** 수근관 증후군 수술 후 주입한 온도 감응형 유착 방지제인 Guardix-SG®는 단기 추시상 영상 의학적으로 판단한 유착 예방 효과는 명확하나 임상 증상과의 호전과는 연관이 없는 것으로 생각한다.

**색인단어:** 수근관 증후군, 횡 수근 인대, 유착 방지제

접수일 2018년 4월 12일 수정일 2018년 4월 18일

게재확정일 2018년 4월 22일

교신저자 신현대

35015, 대전시 중구 문화로 266, 충남대학교 의과대학 정형외과학교실

TEL 042-280-7349 FAX 042-252-7098 E-mail hyunsd@cnu.ac.kr

## Appendix 1.

We used the Bland method to grade the disease status with electrodiagnostic findings<sup>9</sup>. The scale is as follows: normal (grade 0), very mild (grade 1; CTS demonstrable only by the most sensitive tests), mild (grade 2; sensory nerve conduction velocity slow on finger/wrist measurement, normal terminal motor latency), moderate (grade 3; sensory potential preserved with motor slowing, distal motor latency to the abductor pollicis brevis (APB) <6.5 ms), severe (grade 4; sensory potentials absent but motor response preserved, distal motor latency to APB <6.5 ms), very severe (grade 5; terminal latency to APB >6.5 ms), extremely severe (grade 6; sensory and motor potentials effectively unrecordable (surface motor potential from APB <0.2 mV amplitude)).