



pISSN 2586-3290 · eISSN 2586-3533
Arch Hand Microsurg 2022;27(2):161-165
<https://doi.org/10.12790/ahm.22.0008>

Received: March 7, 2022

Revised: April 22, 2022

Accepted: April 22, 2022

Corresponding author:

Eun Soo Park

Department of Plastic and
Reconstructive Surgery, Soonchunhyang
University Bucheon Hospital, 170
Jomaru-ro, Wonmi-gu, Bucheon 14584,
Korea

Tel: +82-32-621-5319

Fax: +82-32-621-5016

E-mail: peunsoo@schmc.ac.kr

ORCID:

<https://orcid.org/0000-0003-2966-9122>

Treatment of a rattlesnake bite on the finger using alternative antivenom management and reconstructive surgery: a case report

Kyong Chan Park, Chang Yong Choi, Seung Min Nam, Eun Soo Park

Department of Plastic and Reconstructive Surgery, Soonchunhyang University College of Medicine, Bucheon, Korea

Snake bite may be observed from localized symptoms to systemic complications. In most cases, the symptoms as well as the lab course improved by conservative treatment. Therefore, it is recommended that enough of the antivenom be administered initially, and the hospital should be aware of the most common envenomations to obtain the most needed antivenoms. A case of 22-year-old woman bitten on her finger by a eastern diamondback rattlesnake. In Korea, there is no antivenom for rattlesnake, so freeze-dried *Agkistrodon halys* antivenom was used alternatively. After 10 days of the injury, laboratory finding was almost normalized. At that time, the digit had undergone massive skin necrosis. The wound achieved total healing at postoperative 2 months after flap coverage. This case of rattlesnake bite, which was first described in Korea, present a management with antivenom to other family of snake, and successful surgical treatment.

Keywords: Fingers, Snake bites, Surgical flaps

Introduction

Snakebite is not common, however, may be observed from localized symptoms such as pain, swelling, infection, delayed wound healing, and skin necrosis at the injury site, to systemic complications including hypotension, neurotoxicity, acute kidney injury, acute respiratory failure, myocardial infarction, disseminated intravascular coagulation, and death. In most cases, the symptoms, as well as the lab processes, were improved by the use of antivenom and conservative treatment. Multiple studies support the use of early and sufficient doses of antivenom administration to reduce the need for surgical intervention. So, a hospital should be aware of the most common envenomations to obtain the most needed antivenoms.

Snakebite is a worldwide specialized form of injury but an underreported issue in Korea because there are few venomous snake species existing. In Korea, only four species are known as poisonous snakes, and hands are the most common sites of snakebite [1].

In the United States, the majority of snakebites (56.3%) occur from rattlesnakes, existing in almost every state [2]. Because rattlesnakes don't exist naturally in Korea, no case of rattlesnake bites has been reported in Korea. Unfortunately, snakebites often result from improper handling by professional snake handlers [3].

Here we describe a rare case of 22-year-old woman bitten by a rattlesnake working in the aquarium. The study was performed in accordance with the principles of the Declaration of Helsinki. The patient provided written informed consent for the publication and the use of his images.

© 2022 by Korean Society for Surgery of the Hand, Korean Society for Microsurgery, and Korean Society for Surgery of the Peripheral Nerve.

© This is an open-access article distributed under the terms of the Creative Commons Attribution Non-Commercial License (<http://creativecommons.org/licenses/by-nc/4.0/>), which permits unrestricted non-commercial use, distribution, and reproduction in any medium, provided the original work is properly cited.

Case report

A 22-year-old woman without underlying medical conditions was bitten on the distal phalanx of her right index finger by an eastern diamondback rattlesnake (*Crotalus adamanteus*) while working in an aquarium (Fig. 1A). After the injury, she went emergency center in our hospital. At the time of initial examination, the injured finger showed moderate tenderness, swelling and bullae formation, progressive skin necrosis 12 hours after the injury (Fig. 1B). In laboratory finding, shortening of prothrombin time and decreased fibrinogen and platelet was shown. She was treated with empirical antibiotics, immobilization, pain control, and simple wound dressing using povidone-iodine. In Korea, there is no antivenom for rattlesnake, so Kovax (freeze-dried *Agkistrodon halys* antivenom injection 6,000 IU/vial; Korea Vaccine, Ansan, Korea) was used alternatively within 24 hours after the injury. Ten days after the injury, laboratory finding was almost normalized without any systemic complication, so she was referred to our department for further surgical debridement. At that time, the digit was desiccated and mummified (Fig. 2). On 3 weeks of hospitalization, the complete debridement for removal of nonviable tissue was performed under general anesthesia. Removal of dry eschar tissue was performed, and exploration of the deep tissue structure was done using mosquito forceps and Metzenbaum scissors. The focal distal parts of flexor tendon and bony structure including distal phalanx and partial head of middle phalanx were nonviable. After removal of the devitalized tissue including the bony tissue of middle phalanx head, the defect was reconstructed using homodigital artery-based island flap and the donor

site was covered with a full-thickness skin graft (Fig. 3). The flap showed good healing, and no further operation was needed. One week after the surgery, she was transferred to outpatient treatment. The wound achieved total healing at postoperative 2 months (Fig. 4).

Discussion

Snakebite envenomation is of concern as a worldwide health threat. In a 2019 World Health Organization report, 5.4 million snakebites occur annually, resulting in 2.7 million cases of envenomings (poisoning from snakebites) [4]. However, snakebites rarely occur in South Korea. In South Korea, 192 to 621 cases of snakebite occur annually with five cases of fatality [5]. And distal parts of the upper extremities are the most common sites in South Korea.

There are four species of venomous snakes that exist in Korea: three species in *Gloydius* genus (*Gloydius blomhoffii*, *Gloydius saxatilis*, *Gloydius ussuriensis*), and one species in *Rhabdophis* genus (*Rhabdophis tigrinus*) [1]. The venom from these snakes is usually not toxic and systemic derangement from the response to the injected toxin is rare. In contrast to reports from Southeast Asian countries, where 70% of injuries are to the lower extremity, the percentage of upper extremity injuries is 69.6% in Korea. However, rattlesnakes are the most common cause of snakebite in the United States, and the mortality rate is higher compared to other snakebites [2]. The rattlesnake's venom, consisting of a mixture of over 50 different proteins, cause local, hematologic, neurologic, and systemic effects. Because each component affects multiple organ systems, it is hard to

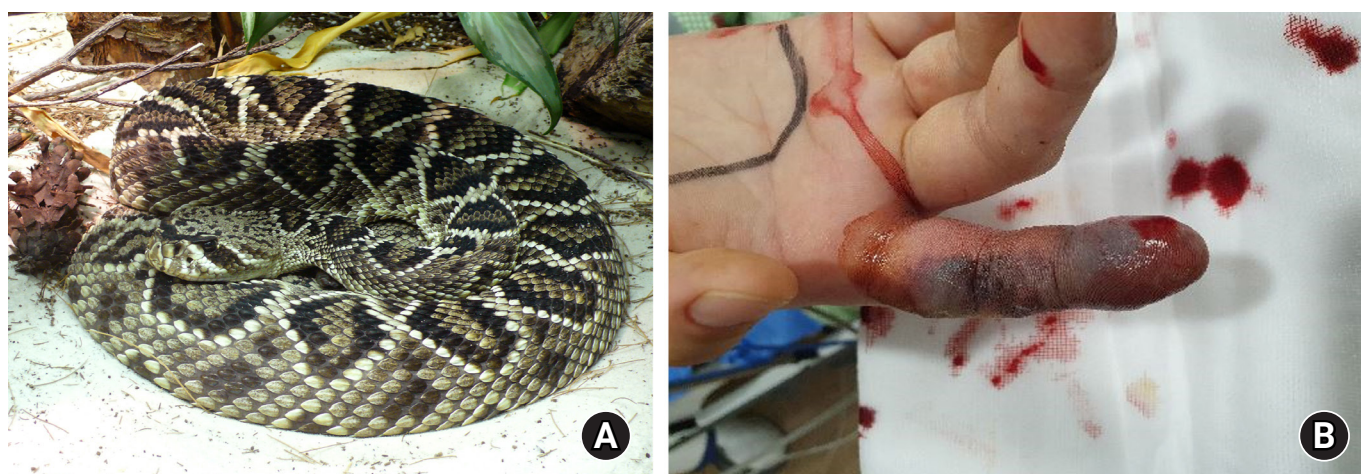

Fig. 1. (A) Rattlesnake (*Crotalus adamanteus*). (B) Initial presentation of the patient. The digit had a dusky appearance in 12 hours after injury. Reused from the public domain of TimVickers via Wikimedia Commons.

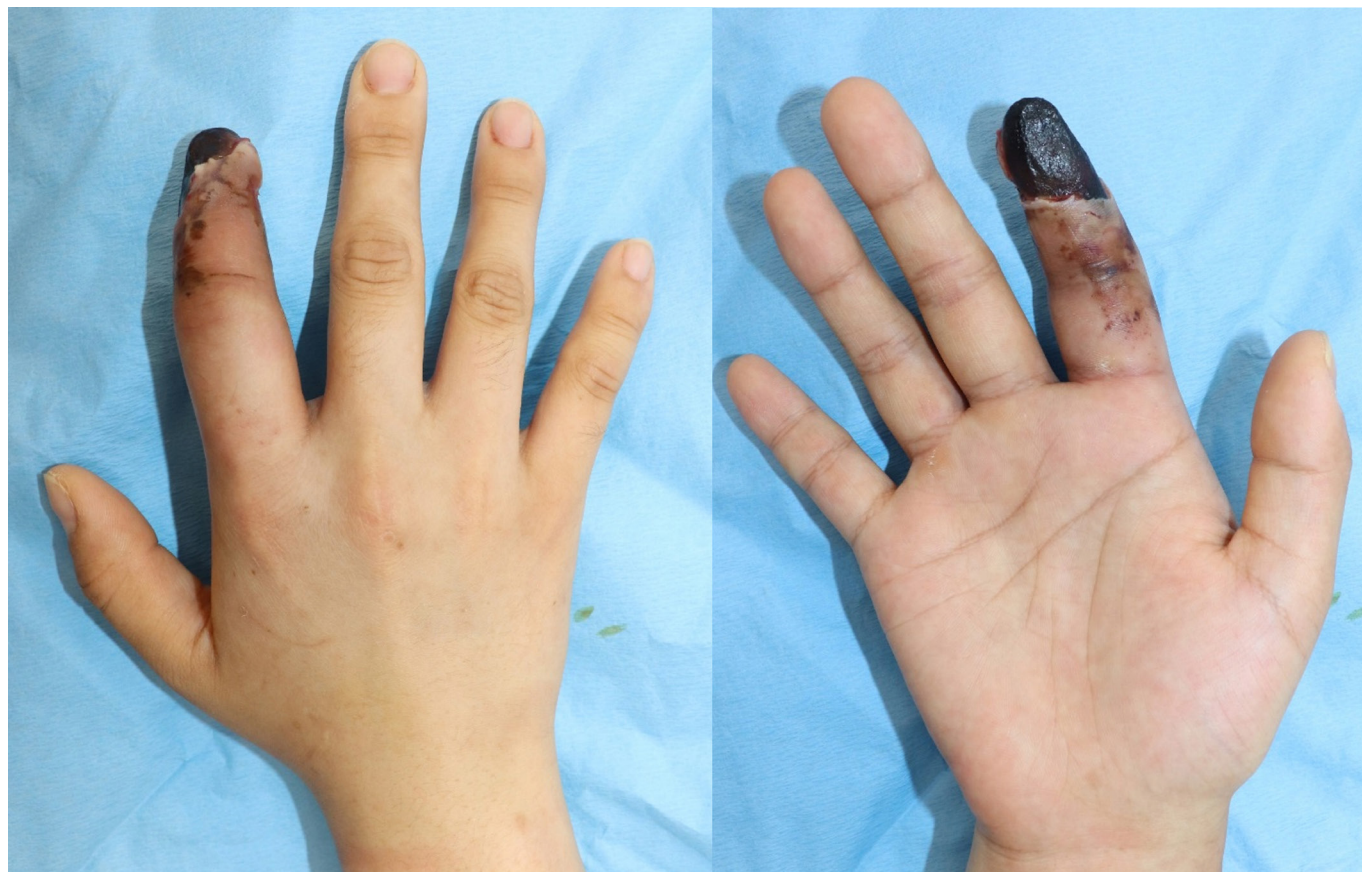


Fig. 2. The appearance of skin necrosis 10 days after injury.

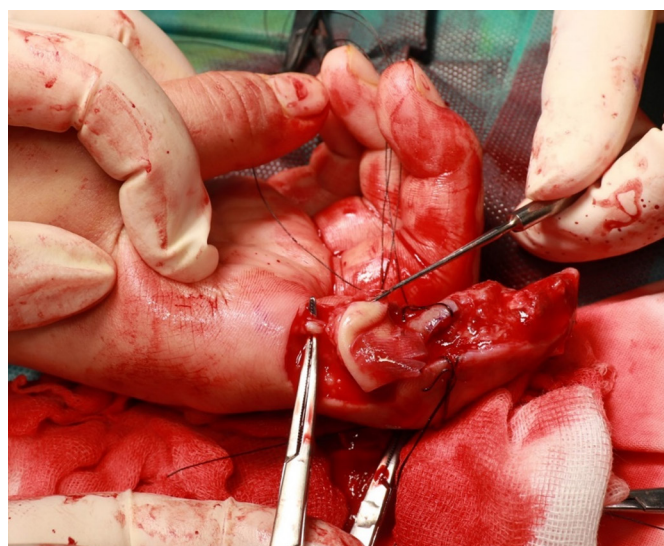

Fig. 3. Intraoperative finding. After the amputation of the middle phalanx head, the reverse homodigital artery-based island flap was performed for resurfacing with the identification of the pedicle.

rigidly classify them as tissue-toxic or neurotoxic. Two of the major components include phospholipase A2 toxin and metalloproteinases. Phospholipase A2 toxins are thought to have myotoxic, anticoagulant, and neurotoxic effects, by inhibiting neuromuscular transmission by blocking presynaptic calcium channels. They are also thought to damage platelet membranes, resulting in thrombocytopenia [6]. Metalloproteinases are supposed to be contributors to local tissue destruction and hemorrhage. They alter the morphology of endothelial cells of capillary vessel by cleaving peptide bonds of basement membrane, resulting in hemorrhage. Snakebites show common symptomatology including local tissue damage and systemic manifestations.

However, each species has a variable level of gene expression, controlling the level of proteins and enzymes. Despite previous many studies, many aspects of snake venom toxicity are not still clearly defined.

After field management, the mainstay of medical management of a rattlesnake bite is antivenom administration, which is made up of purified immunoglobulin (Ig) G antibodies. Two antivenoms are available for rattlesnake envenomations. Cro-

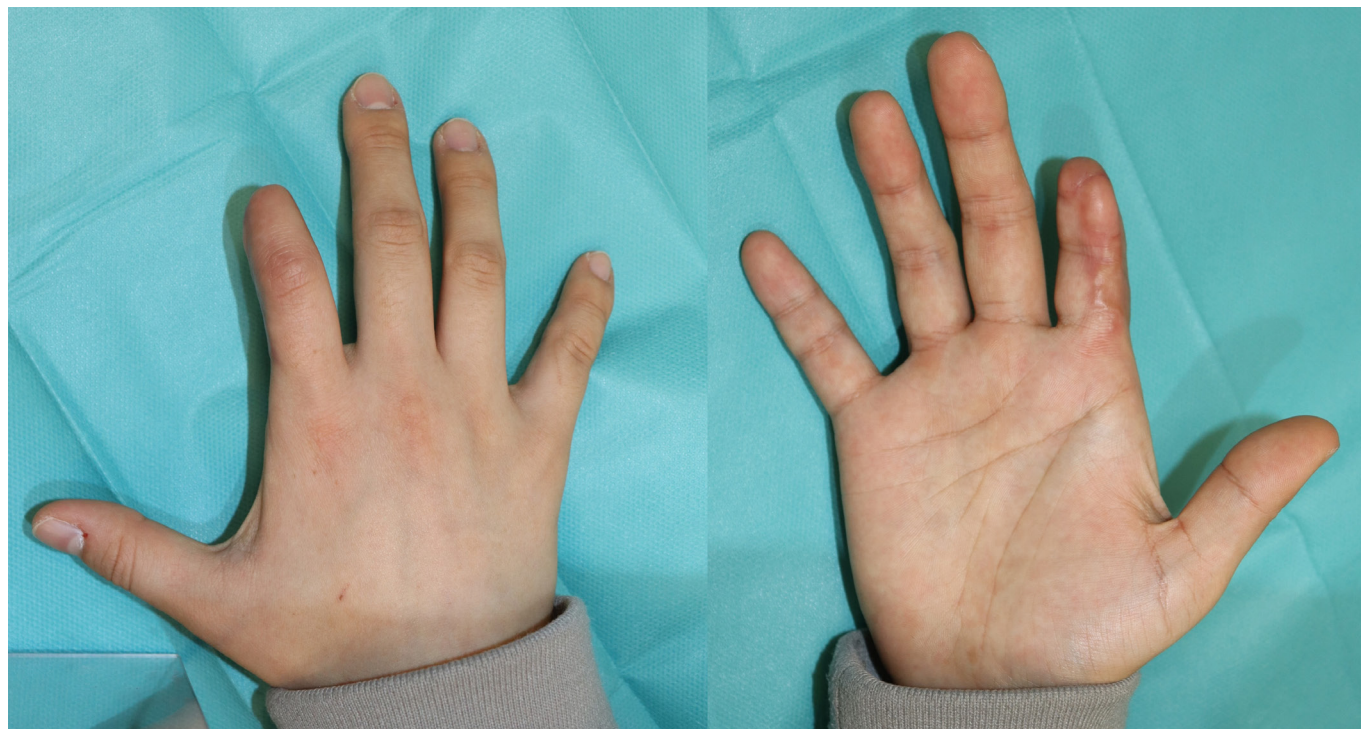

Fig. 4. Postoperative 2 months finding. The wound was totally healed.

talidae polyvalent immune fab (CroFab; BTG, London, UK) is purified ovine-derived immunoglobulin for four snakes (western diamondback, eastern diamondback, Mojave rattlesnake, and cottonmouth). Crotalidae Immune F(ab)2 (Anavip; Bioclon, Mexico City, Mexico) is equine-derived IG for two snakes (*Bothrops asper* and *Crotalus durissus*), usually not requiring repeat maintenance dosing due to the longer duration of activity [7]. Proper antivenom administration within 4 hours of envenomation offers a decreased risk of requiring surgical intervention. In many cases, however, patients could not identify the snake species that bit them. So, knowing the common snakes in the locality may help find the real culprits.

In our case, the patient with a rattlesnake bite was given the *Agkistrodon halys* antivenom, because it is the only commercial antivenom in Korea. As a result, the patient had no systemic complication including respiratory distress, coagulation impairment, or neurologic symptoms. The local tissue damage was not further aggravated and stabilized within 1 week. It is widely known that a monovalent or polyvalent antivenom is effective in the family of snakes causing the bite. Because there are common antigens between the venoms of snakes in the same genus, there may be cross-reaction against another genus [1]. The Kovax is a whole IgG antibody derived from *Agkistrodon halys*, which exists in China. And it is proved that this antivenom is effective in *Gloydius blomhoffii*, *Gloydius saxatilis*,

Gloydius ussuriensis, because of cross-reaction; but not in *Rhabdophis tigrinus* [8]. For rattlesnakes, the commercial antivenom for rattlesnake in the United States is not recommended for snakes outside the United States. In contrast, the effect of Kovax on rattlesnake is not studied [9]. We guessed that the antivenom used for the patient affect the toxin envenomated by other families of snakes. The further study on immunoreactivity is needed.

So far, there have been no reports of rattlesnake bite in Korea. Here, we present a case of a rattlesnake bite managed with antivenom to other families of snakes and successful surgical treatment. This case may be helpful to physicians fronting a patient bitten by an uncommon viper, or plastic surgeons agonizing the surgical options.

ORCID

Kyong Chan Park, <https://orcid.org/0000-0002-0742-1233>
 Chang Yong Choi, <https://orcid.org/0000-0002-6385-0817>
 Seung Min Nam, <https://orcid.org/0000-0001-7865-5013>
 Eun Soo Park, <https://orcid.org/0000-0003-2966-9122>

Conflicts of interest

The authors have nothing to disclose.

Funding

This work was supported by the Soonchunhyang University Research Fund (No. 10220018).

References

1. Lim H, Kang HG, Kim KH. Antivenom for snake bite in Korea. *J Korean Med Assoc.* 2013;56:1091-103.
2. Ruha AM, Kleinschmidt KC, Greene S, et al. The epidemiology, clinical course, and management of snakebites in the North American Snakebite Registry. *J Med Toxicol.* 2017;13:309-20.
3. Walter FG, Stolz U, Shirazi F, McNally J. Epidemiology of severe and fatal rattlesnake bites published in the American Association of Poison Control Centers' Annual Reports. *Clin Toxicol (Phila).* 2009;47:663-9.
4. World Health Organization (WHO). Snakebite envenoming [Internet]. Geneva: WHO; 2021 [cited 2022 Mar 7]. Available from: <https://www.who.int/news-room/fact-sheets/detail/snakebite-envenoming>.
5. Choi HJ, Lee DW, Ryu HR, Kim JH, Lee JH. Case of treatment of snakebite on finger with topical oxygen therapy. *Arch Hand Microsurg.* 2020;25:292-6.
6. Corbett B, Clark RF. North American snake envenomation. *Emerg Med Clin North Am.* 2017;35:339-54.
7. Mascarenas DN, Fullerton L, Smolinske SC, Warrick BJ, Seifert SA. Comparison of F(ab')₂ and Fab antivenoms in rattlesnake envenomation: first year's post-marketing experience with F(ab')₂ in New Mexico. *Toxicon.* 2020;186:42-5.
8. Gao JF, Wang J, Qu YF, Ma XM, Ji X. Immunoreactivity between venoms and commercial antiserums in four Chinese snakes and venom identification by species-specific antibody. *J Immunol Methods.* 2013;387:211-8.
9. Lavonas EJ, Ruha AM, Banner W, et al. Unified treatment algorithm for the management of crotaline snakebite in the United States: results of an evidence-informed consensus workshop. *BMC Emerg Med.* 2011;11:2.