



Case Report

pISSN 2586-3290 · eISSN 2586-3533
Arch Hand Microsurg 2020;25(4):287-291
<https://doi.org/10.12790/ahm.20.0052>

Received: September 14, 2020

Revised: October 6, 2020

Accepted: October 8, 2020

Corresponding author:

Byung Jun Kim

Department of Plastic and
Reconstructive Surgery, Seoul National
University Hospital, Seoul National
University College of Medicine, 101
Daehak-ro, Jongno-gu, Seoul 03080,
Korea

Tel: +82-2-2072-1978

Fax: +82-2-2072-0274

E-mail: bjkim79@gmail.com

ORCID:

<https://orcid.org/0000-0002-6891-3768>

키르쉬너 강선을 이용한 협조되지 않는 소아 환자의 무지구피판 고정법에 대한 증례 보고

유효경, 김영훈, 권성택, 김병준

서울대학교 의과대학 서울대학교병원 성형외과학교실

Kirschner Wire Fixation for Immobilization of the Thenar Flap in an Uncooperative Pediatric Patient: A Case Report

Hyokyung Yoo, Yunghoon Kim, Sung Tack Kwon, Byung Jun Kim

Department of Plastic and Reconstructive Surgery, Seoul National University Hospital, Seoul National University College of Medicine, Seoul, Korea

Thenar flap is a commonly used operational method in fingertip reconstruction. It should be maintained for 2 to 3 weeks before flap division until the neovascularization is established from the fingertip to the flap. However, immobilization between two stages of operation is challenging especially in uncooperative pediatric patients. A 47-month-old female with a ring fingertip amputation underwent soft tissue reconstruction with thenar flap. Two days postoperatively, the flap's proximal margin was found disrupted. Flap revision was performed, followed by applying a transphalangeal Kirschner wire (K-wire) between the thumb proximal phalanx and ring finger middle phalanx. The flap was successfully divided two weeks after the original operation. The result was aesthetically pleasing, and no complication was observed, including dehiscence, necrosis, limitation of range of motion, and visible scar of the pinning sites. In conclusion, K-wire fixation is a safe and effective method to immobilize thenar flap in uncooperative pediatric patients.

Keywords: Surgical flaps, Bone wires, Fingers, Immobilization, Pediatrics

INTRODUCTION

Fingertip injuries are one of the most common types of hand trauma in pediatric patients [1]. Severe injuries involving substantial pulp loss often require soft tissue reconstruction to restore shape and preserve long-term functionality. The thenar flap, which was first described by Gatewood in 1926 [2], has been widely accepted as the workhorse flap for fingertip reconstruction. However, it requires two-staged operations including 2 to 3 weeks of interval period of immobilization. It is not easy to achieve and maintain immobilization especially in uncooperative pediatric patients. Some previous studies have suggested specific positions, taping or splinting techniques, but those methods are sometimes not sufficient enough to maintain the flap in an appropriate position in children [3-6]. Therefore, we introduce a new immobilization method by inserting a Kirschner wire (K-wire) between the injured finger and the thumb considering the opposite vec-

tors of the two digits.

CASE REPORT

A 47-month-old female presented to the emergency department with a fingertip injury at her right ring finger after crushing it in the hinges of a chair. Written informed consent was obtained from the patient. The soft tissue defect included approximately one-fourth of the distal phalanx in length (Ishikawa zone 1), involving both the volar and dorsal side, with exposure of the distal tip of distal phalangeal bone (Fig. 1A). There was no disruption of tendon or neurovascular structures. A minor fracture line was observed in the distal phalangeal bone in the preoperative X-rays (Fig. 1B).

Because of the loss of the amputated part, the defect was covered by reconstruction with a 5 × 10 mm-sized, distally-based, fasciocutaneous thenar flap, elevated from the palmar thenar eminence (Fig. 2A). In the flap elevation, special care was taken to avoid injury to the palmar digital nerve of thumb. A long-arm,

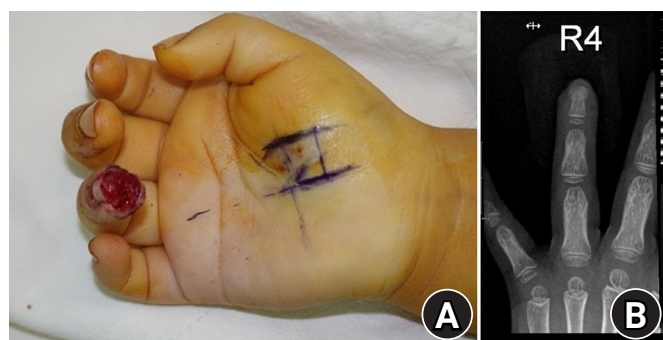


Fig. 1. (A) Preoperative photograph of a 47-month-old female with a soft tissue defect (Ishikawa zone 1) and exposure of the distal tip of distal phalangeal bone at right ring finger. (B) Preoperative X-ray shows a minor fracture line in the distal phalangeal bone.

dorsal-blocking splint was applied postoperatively to prevent extension of the affected digit. The elbow was maintained in 90° flexion, and the metacarpophalangeal joint, proximal interphalangeal joint, and distal interphalangeal joint were all also flexed.

However, thenar flap's proximal margin was found partially disrupted during ward dressing 2 days after the operation, and reoperation was planned (Fig. 2B). After repairing the dehiscent flap inset margin, the ring finger middle phalanx was placed in close approximation to the thumb proximal phalanx opposite vectors. To avoid any injuries of the epiphyseal plates and neurovascular structures, midaxial lines were drawn first at the affected digit and thumb in a flexion state. Then, an 18-gauge catheter was carefully applied dorsal to the marked lines from the skin to the periosteum, and a 0.7 mm-sized K-wire was inserted through the catheter. The wire was inserted vertically towards the diaphysis' longitudinal axes of the ring finger middle phalangeal bone and thumb proximal phalangeal bone to immobilize the flap (Fig. 3).

The position was sustained well for 2 weeks, and the flap was maintained in a healthy condition without any congestion or disruption. The K-wire was removed, and the flap's distal margin was successfully divided 2 weeks after the first operation (Fig. 4). The donor site was closed by primary closure. The patient was satisfied with the aesthetic and functional outcome. There was no complication associated with the reconstruction with thenar flap, such as dehiscence, necrosis, and nail deformity. Further, no complication was observed regarding the insertion of a K-wire, including dermatitis, infection, visible scar, and contracture of the proximal interphalangeal joint of the affected finger.

DISCUSSION

Fingertip injuries are one of the most common types of hand

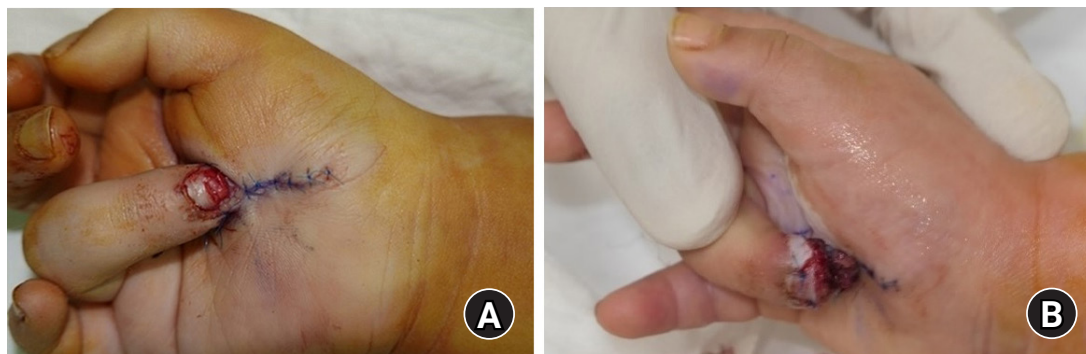

Fig. 2. (A) Immediate postoperative photograph of reconstruction with thenar flap. (B) The proximal margin of the flap was found disrupted 2 days after the first operation.

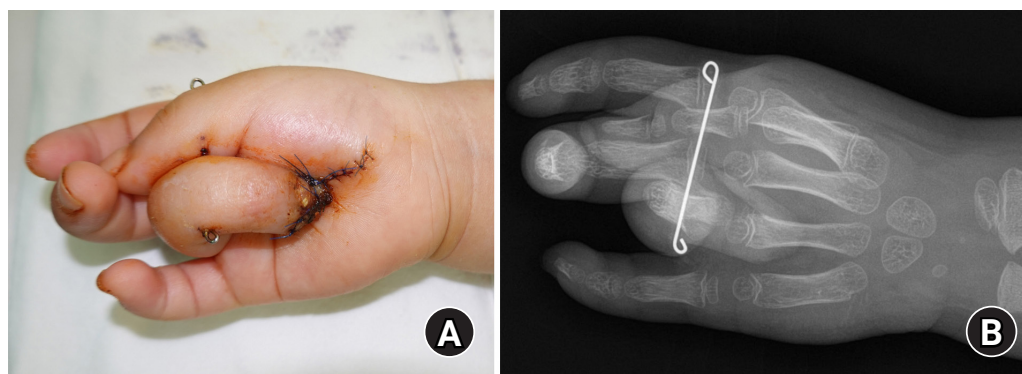


Fig. 3. (A) Immediate postoperative photograph after applying a Kirschner wire between the shafts of the ring finger middle phalangeal bone and the thumb proximal phalangeal bone to prevent movement of the flap. (B) Postoperative X-ray.

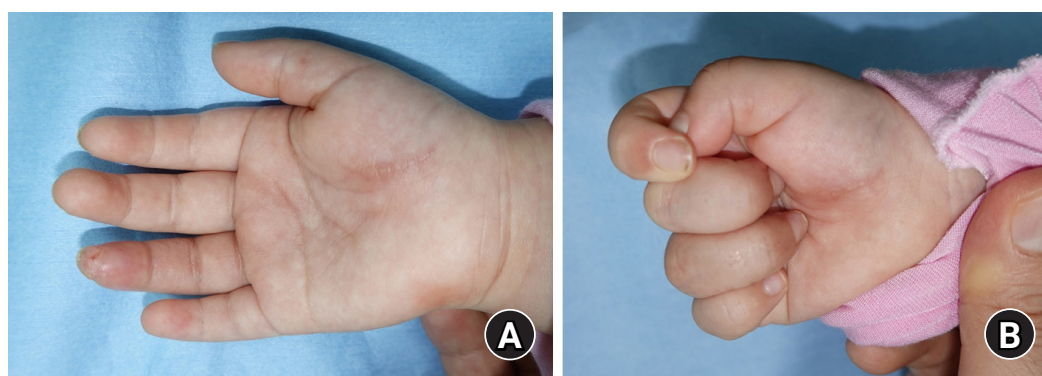


Fig. 4. Photograph at 7 weeks after the original operation showing reconstructed fingertip and preservation of full range of motion.

trauma in pediatric patients [1]. Depending on the extent of injury, there are numerous surgical methods available, and each treatment option must be customized to the individual in order to restore the contour of fingertip and to preserve the sensation and range of motion with minimal donor site morbidity.

While small defects, that are less than 1 cm² in area, are best treated by conservative secondary healing, moderate-sized defects require full-thickness skin grafts [7]. However, skin grafts can cause insufficient sensitivity, tenderness, and cold intolerance as long-term complications [8]. Local flaps are sometimes not sufficient to provide adequate coverage in young children with small hands. Atasoy volar V-Y advancement flaps are not suitable in cases with volar side oblique amputations [9], and Kutler bilateral advancement flaps produce inevitable scars in the midline which could cause scar pain [10]. Microvascular free tissue transfers are also not the practical treatment option for pediatric patients because of the prolonged operation time, risk of flap failure, donor site scar, and possible numbness [11].

Thenar flap has been accepted as the workhorse flap for fingertip reconstruction in injuries involving substantial pulp loss by many surgeons [12-14]. Thenar flap restores the bulk and

contour of the fingertip with excellent tissue match by utilizing local autogenous tissue with minimal donor site morbidity. Even though the risk of proximal interphalangeal joint contracture has been mentioned in early studies, more recent studies have contradicted these concerns [4,13,14]. However, this method requires two-staged surgery and careful postoperative care for the thenar skin bridge between the two stages of operation, especially in undisciplined pediatric patients.

Some previous studies have described methods for stabilization of the thenar flap during the interval period. Flatt [3] suggested a specific postoperative position, in which all three joints of the affected finger lie in medium flexion posture to achieve maximum stabilization and circulation of the flap [3]. Melone et al. [4] advised to use a precisely fitted bulky dressing with application of tape strips to immobilize the carefully selected positioning of the affected digit [4]. Sano et al. [5] proposed immobilizing the operated finger with a dorsal splint in flexion status together with the other ulnar two digits. In this position, patients can relax the three ulnar digits equally and can feel less discomfort with immobilization. Gundes et al. [6] applied a butterfly-shaped splint over a bulky dressing to obtain immobi-

lization and prevent flap detachment.

However, from our previous experience, these methods are not sufficient enough to prevent the slightest movement of pediatric patients that could result in tension, avulsion, and disruption of the flap. Therefore, we introduce a new method of immobilization of thenar flap by inserting a K-wire between the injured finger and the thumb considering the opposite vectors of the two digits. By confining the thumb and the affected finger in an absolutely immobilized posture, not only the affected digit but also the thumb cannot move at all, which supports the stabilization of the flap in the right location. Even though this posture might cause discomfort for the patient for not being able to grip with the thumb, we found no limitation of range of motion of the affected digit or the thumb after removing the K-wire in our case. The other possible complications regarding the insertion of a K-wire include infection, dermatitis, visible scar, and neurovascular injury, all of which did not occur.

To the best of our knowledge, this is the first report on the use of a K-wire in immobilization of the thenar flap. It is a simple, effective, and safe method, and it can be applied not only to the ring finger but also to the index finger or middle finger especially in uncooperative pediatric patients.

In conclusion, Kirshner wire fixation is a safe and effective method to immobilize thenar flap in uncooperative pediatric patients.

CONFLICTS OF INTEREST

The authors have nothing to disclose.

REFERENCES

1. Ljungberg E, Rosberg HE, Dahlin LB. Hand injuries in young children. *J Hand Surg Br.* 2003;28:376-80.
2. Gatewood. A plastic repair of finger defects without hospitalization. *JAMA.* 1926;87:1479.
3. Flatt AE. The thenar flap. *J Bone Joint Surg Br.* 1957;39-B:80-5.
4. Melone CP Jr, Beasley RW, Carstens JH Jr. The thenar flap: an analysis of its use in 150 cases. *J Hand Surg Am.* 1982;7:291-7.
5. Sano K, Aoki S, Koike S, Hyakusoku H. Delayed extended "midthenar" flap for reconstruction of total fingertip avulsion injury and a proposal of ideal postoperative immobilization for a palmar flap. *Ann Plast Surg.* 2007;58:116-9.
6. Gundes H, Tosun B, Buluc L, Alici T. Butterfly-type splint immobilization to prevent thenar flap detachment in children. *Orthopedics.* 2006;29:495-6.
7. Hashem AM. Full-thickness grafting from the ulnar border of the palm: outcome and donor-site morbidity. *Ann Plast Surg.* 2011;67:123-8.
8. Foucher G, Dallaserra M, Tilquin B, Lenoble E, Sammut D. The Hueston flap in reconstruction of fingertip skin loss: results in a series of 41 patients. *J Hand Surg Am.* 1994;19:508-15.
9. Atasoy E, Ioakimidis E, Kasdan ML, Kutz JE, Kleinert HE. Reconstruction of the amputated finger tip with a triangular volar flap: a new surgical procedure. *J Bone Joint Surg Am.* 1970;52:921-6.
10. Kutler W. A new method for finger tip amputation. *J Am Med Assoc.* 1947;133:29-30.
11. Lee DC, Kim JS, Ki SH, Roh SY, Yang JW, Chung KC. Partial second toe pulp free flap for fingertip reconstruction. *Plast Reconstr Surg.* 2008;121:899-907.
12. Fitoussi F, Ghorbani A, Jehanno P, Frajman JM, Penneçot GE. Thenar flap for severe finger tip injuries in children. *J Hand Surg Br.* 2004;29:108-12.
13. Barr JS, Chu MW, Thanik V, Sharma S. Pediatric thenar flaps: a modified design, case series and review of the literature. *J Pediatr Surg.* 2014;49:1433-8.
14. Weber DM, Kellenberger CJ, Meuli M. Conservative treatment of stable volar plate injuries of the proximal interphalangeal joint in children and adolescents: a prospective study. *Pediatr Emerg Care.* 2009;25:547-9.

키르쉬너 강선을 이용한 협조되지 않는 소아 환자의 무지구피판 고정법에 대한 증례 보고

유효경, 김영훈, 권성택, 김병준

서울대학교 의과대학 서울대학교병원 성형외과학교실

무지구피판술은 수지 말단의 연부조직 결손 재건 방법 중 가장 흔하게 쓰이는 수술법 중 하나이다. 수지 말단부터 피판까지 신생 혈관이 형성되기까지 2-3주 간의 기간을 기다린 뒤에 피판을 분할하게 된다. 그러나 소아와 같이 협조가 어려운 환자에서는 두 단계의 수술 사이 기간 동안 피판을 움직이지 않도록 고정한 채 유지하는 것이 어렵다. 본 연구에서는 약지 말단 지골의 절단을 주소로 내원한 47개월 여자 환아에 대해 무지구피판술을 이용한 연부조직 재건술을 시행하였다. 수술 후 이틀째에 피판 근위부 경계가 파열된 것을 발견하여 즉시 피판 고정술을 시행하였고, 피판을 적절한 위치에 고정하기 위해서 엄지의 근위지골 및 약지의 중위지골 사이에 키르쉬너 강선을 삽입하였다. 피판은 첫 번째 수술로부터 2주째에 성공적으로 분할되었고, 수술의 결과는 미용상으로 훌륭했으며, 열개, 괴사, 수지 운동의 제한, 강선 삽입부의 눈에 띄는 흉터 등의 부작용은 관찰되지 않았다. 결론적으로, 키르쉬너 강선 고정술은 비협조적인 소아 환자에서 무지구피판술을 고정하기에 안전하고 효과적인 방법이다.

색인단어: 피판술, 강선, 수지, 고정, 소아

접수일 2020년 9월 14일 **수정일** 2020년 10월 6일 **게재확정일** 2020년 10월 8일

교신저자 김병준

03080, 서울시 종로구 대학로 101, 서울대학교병원 성형외과

TEL 02-2072-1978 **FAX** 02-2072-0274 **E-mail** bjkim79@gmail.com

ORCID <https://orcid.org/0000-0002-6891-3768>