



Case Report

pISSN 2586-3290 · eISSN 2586-3533
Arch Hand Microsurg 2020;25(4):304-308
<https://doi.org/10.12790/ahm.20.0032>

Received: May 28, 2020
Revised: August 3, 2020
Accepted: August 19, 2020

Corresponding author:

Kyeong Tae Lee
Department of Plastic Surgery, Samsung Medical Center, 81 Irwon-ro, Gangnam-gu, Seoul 06351, Korea
Tel: +82-2-3410-2235
Fax: +82-2-3410-0036
E-mail: skymaker26.lee@samsung.com
ORCID:
<https://orcid.org/0000-0002-9070-9296>

© 2020 Korean Society for Surgery of the Hand, Korean Society for Microsurgery, and Korean Society for Surgery of the Peripheral Nerve. All Rights reserved.

© This is an open-access article distributed under the terms of the Creative Commons Attribution Non-Commercial license (<http://creativecommons.org/licenses/by-nc/4.0/>), which permits unrestricted non-commercial use, distribution, and reproduction in any medium, provided the original work is properly cited.

형태를 다듬은 상둔동맥 천공지피판을 이용한 항문 주위 조직 결손의 재건

문지현, 이경태

삼성서울병원 성형외과

Perianal Circumferential Reconstruction with Tailored Superior Gluteal Artery Perforator Flap

Jeehyun Moon, Kyeong Tae Lee

Department of Plastic Surgery, Samsung Medical Center, Seoul, Korea

Reconstruction following wide excision of perianal lesion is challenging as it requires resistance to high risks of wound contamination and preservation of anal function. Here, we present a case of a unilateral superior gluteal artery perforator (SGAP) flap with an opening in the flap. A 77-year old woman was referred due to an extramammary Paget's disease encircling the anus. Wide excision was performed by the general surgeon team, which generated a circumferential perianal defect. A unilateral SGAP flap was elevated. Primary defatting was done and an opening was made at the proper location of the anus. The anal mucosa was pulled out through the hole and sutured to the flap. She was discharged without any complications. At the follow-up visit, preservation of postoperative anal functions, as well as satisfactory contour, were observed. A well-tailored unilateral SGAP flap may be a good option for reconstruction of a perianal defect encircling the anus.

Keywords: Anus diseases, Extramammary Paget disease, Perforator flap

INTRODUCTION

Extramammary Paget disease (EMPD) is a rare malignant neoplasm of the skin mainly involving the genital region, including the vulva, penis, perianal and periurethral areas [1]. Perianal Paget disease (PPD) accounts for 20% of EMPD [2].

Currently, wide local excision is the standard treatment modality for PPD. To reduce the risks of recurrence, excision with a sufficient safety margin is necessary, which results in wide defects of the skin and soft tissue surrounding the anus. Reconstruction of these defects is challenging because the perianal area can be easily contaminated and is difficult to be kept clean and bacteria-free. Creating an ileostomy in order to protect the wound from fecal contamination has often been suggested [3]; however, this could induce additional morbidity and reduce the patient's postoperative quality of life.

The superior gluteal artery perforator (SGAP) flap has been utilized as a versatile option for reconstruction of the gluteal area, including sacral pressure sore reconstruction [4]. Owing to the vicinity of the donor site to the defect, this flap

could be used for reconstruction of the perianal region. However, there have been few reports regarding the use of SGAP flaps for reconstruction of perianal defects [5]. We present a case in which reconstruction of a perianal defect was performed using a well-tailored SGAP flap following wide excision of tissue affected by PPD.

CASE REPORT

A 77-year old woman was referred from the department of colorectal cancer with a mass encircling the anus, which was

diagnosed as EMPD on a punch biopsy. Surgery was planned to be performed by a combined general surgery (GS) plastic surgery team.

The patient was placed in a jack knife position under general anesthesia. Wide excision was performed by the GS team with cancer-free resection margin, leading to an 8 × 5 cm circumferential perianal defect (Fig. 1). Two perforators were identified in the adjacent tissue using an audible pencil doppler and a 10 × 5 cm SGAP flap was designed on her left buttock (Fig. 2). The flap was elevated along the suprafascial, dissecting two perforators with sufficient length for implantation. Primary de-fatting of the flap was done using Metzenbaum scissors to match the contour of the anal cleft and to avoid bulkiness. An opening was made within the flap at the proper location of the

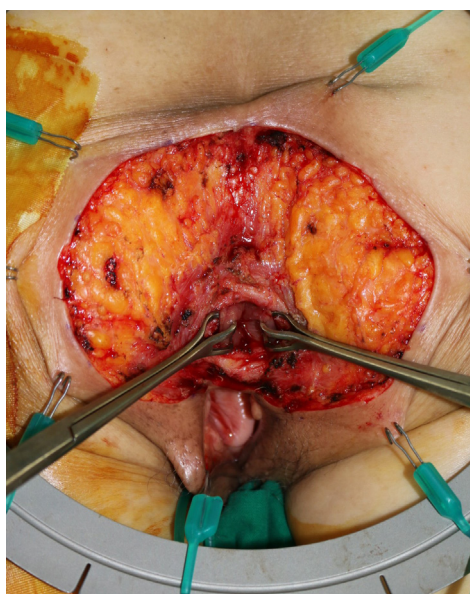


Fig. 1. Tissue defect encircling the anus, sized 10 × 5 cm. Written informed consent for publication of their clinical images was obtained from the patient.

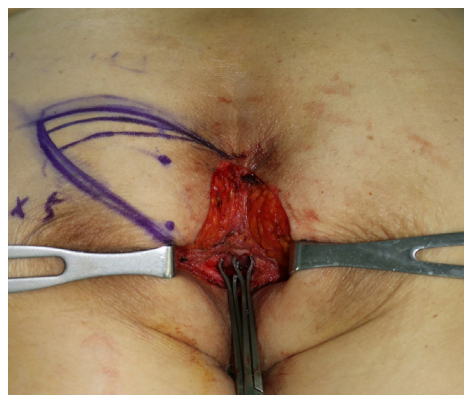

Fig. 2. Intraoperative design of the superior gluteal artery perforator flap from the left buttock based on three perforators. Written informed consent for publication of their clinical images was obtained from the patient.

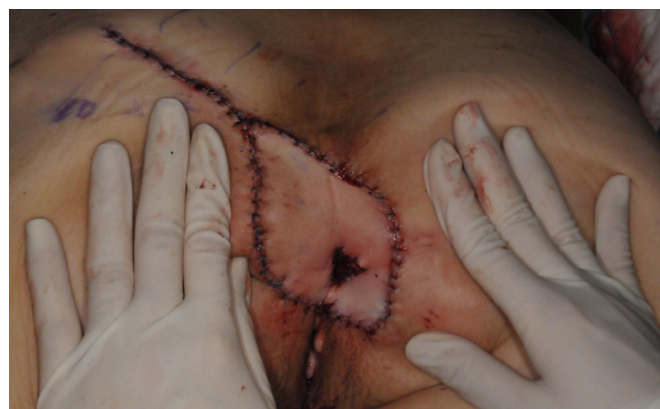

Fig. 3. Immediate postoperative photograph showing the anal mucosa sutured to the hole of the flap. Written informed consent for publication of their clinical images was obtained from the patient.

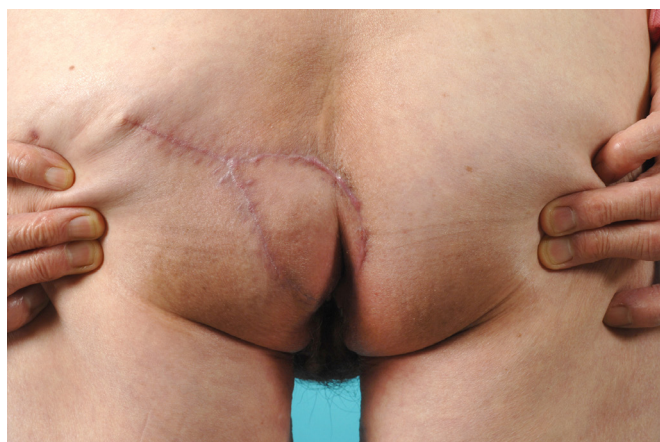

Fig. 4. Appearance at postoperative 3 months. Preservation of anal function and satisfactory tissue contouring is observed. Written informed consent for publication of their clinical images was obtained from the patient.

anus, with the skin and soft tissue trimmed to prevent tissue crowding. The anal mucosa tagged beforehand by a GS surgeon was pulled through the hole and sutured to the flap (Fig. 3). A temporary diverting colostomy was not needed. A drain was inserted into the left buttock donor site.

The patient was kept nil per os for 14 days postoperatively to prevent wound contamination by stool. The wound successfully healed without any complications. Laxatives were prescribed to protect the perianal wound from pressure imparted when passing stool for postoperative one month. In the follow up visit, preservation of postoperative anal functions including soft defecation and sensation as well as satisfactory tissue contouring were observed (Fig. 4).

This study was approved by the Institutional Review Board of the Samsung Medical Center (IRB No: 2020-10-041). All authors declare that written informed consent was obtained from the patient for publication of this case report and accompanying images.

DISCUSSION

The perianal skin is a common site for EMPD, Bowen disease, and squamous cell cancer, with wide local excision as the treatment of choice [6]. In the literature, reports on reconstruction of perianal soft tissue have mainly described surgeons' experiences with skin grafts and, in some cases, multiple V-Y advancement flaps.

Skin grafts are susceptible to bacterial infection, which leads to prolonged wound healing or graft failure. Postoperative care is challenging as the patient is required to remain in the prone position during the recovery period. Furthermore, even when the wound is fully healed there is a risk of compromised anal function due to contraction of the grafted skin. The V-Y advancement flap is a popular method that provides reliable outcomes in PPD patients. It enables the anatomical reconstruction of the natal cleft and anus if the flap is appropriately designed [6]. To provide adequate tissue coverage and preserve anatomical function, bilateral or multidirectional flaps are often required. This results in prolonged operation time and increased donor site morbidity. Tension from the bilateral flaps can result in widening of the anus. In case of a local recurrence of PPD after reconstruction with a bilateral flap, further excision and reconstruction can be challenging. Flap bulkiness is another shortcoming of the V-Y advancement flap. Defatting or thorough tailoring of the V-Y flap can be difficult. Furthermore, tripoint formation is inevitable in V-Y advancement flaps, which can result in scar contracture that can hinder anal

function.

Our approach using the SGAP flap has three strengths. First, the flap has reliable perfusion, which enables not only fast wound healing but also the stability to withstand formation of a hole within the flap. Subsequently, there was no scar contracture due to poor blood supply. Second, the flap could be tailored in accordance with the adjacent tissue, and the flap thickness was adjusted using primary defatting. Defatting could be performed safely because the perforators were directly visualized and could be easily avoided. Suprafacial plexus is formed in multiple directions; therefore, defatting and hole fabrication wouldn't compromise flap perfusion. Third, SGAP flap reduces donor site morbidity compared to the bilateral V-Y advancement flap. However, there are limitations to the SGAP flap; particularly, meticulous dissection is required to avoid any tension on perforators on the flap. Adequate defatting is necessary to obtain ideal clinical outcomes.

Reconstructive procedures to repair perianal defects following the wide excision of PPD should provide tissue coverage that is resistant to infection and pressure from postural changes, without impairing anal function. We used an SGAP flap and produced an opening in the flap for the anus. Primary defatting was done to achieve an optimal contour with the adjacent tissue. Satisfactory tissue contouring and defecation were observed. Therefore, well-tailored SGAP flaps may be a good option for the reconstruction of perianal defects encircling the anus.

CONFLICTS OF INTEREST

The authors have nothing to disclose.

REFERENCES

1. Ahmadzadeh R, Bergeron L, Tang M, Morris SF. The superior and inferior gluteal artery perforator flaps. *Plast Reconstr Surg*. 2007;120:1551-6.
2. Borsuk DJ, Melich G, Sugrue J, et al. Wide local excision of perianal Paget's disease with gluteal flap reconstruction: an interdisciplinary approach. *J Vis Surg*. 2016;2:159.
3. Goto H, Yoshida Y, Kiyohara Y, Suyama Y, Nakayama B, Yamamoto O. Stoma creation for treatment of primary perianal Paget's disease. *Eur J Dermatol*. 2015;25:73-4.
4. Unal C, Yirmibesoglu OA, Ozdemir J, Hasdemir M. Superior and inferior gluteal artery perforator flaps in reconstruction of gluteal and perianal/perineal hidradenitis suppurativa lesions. *Microsurgery*. 2011;31:539-44.

5. Sasaki K, Nozaki M, Kikutchi Y, Yamaki T, Soejima K. Reconstruction of perianal skin defect using a V-Y advancement of bilateral gluteus maximus musculocutaneous flaps: reconstruction considering anal cleft and anal function. *Br J Plast Surg*. 1999;52:471-5.
6. Perez DR, Trakarnsanga A, Shia J, et al. Management and outcome of perianal Paget's disease: a 6-decade institutional experience. *Dis Colon Rectum*. 2014;57:747-51.

형태를 다듬은 상둔동맥 천공지피판을 이용한 항문 주위 조직 결손의 재건

문지현, 이경태

삼성서울병원 성형외과

창상 오염의 위험성과 항문의 기능 보존의 필요성으로 인해 항문 주위 병변의 광범위 절제술 이후의 재건은 까다롭다. 본 논문에서 일측성 상둔동맥 천공지피판에 구멍을 만들어 재건한 증례를 소개한다. 77세 여자 환자가 항문을 둘러싸는 유방외폐질환으로 의뢰되었다. 외과에서 광범위 절제술을 시행하여 항문 주변에 조직 결손이 생겼다. 조직 재건을 위해 일측 상둔동맥 천공지피판을 거상하였다. 피판의 지방을 일부 제거하고 항문을 위치시킬 곳에 구멍을 만들었다. 항문 점막을 구멍으로 빼내어 피판에 고정하였다. 환자는 합병증 없이 퇴원하였다. 외래 방문에서 항문 기능의 보존과 만족할 만한 외형을 확인하였다. 적절하게 형태를 다듬은 일측성 상둔동맥 천공지피판은 항문을 둘러싸는 형태의 조직 결손에 적절한 재건 방법이라 할 수 있다.

색인단어: 항문 주위 재건, 유방외폐질환, 천공지피판

접수일 2020년 5월 28일 **수정일** 2020년 8월 3일 **게재확정일** 2020년 8월 19일

교신저자 이경태

06351, 서울시 강남구 일원로 81, 삼성서울병원 성형외과

TEL 02-3410-2235 **FAX** 02-3410-0036 **E-mail** skymaker26.lee@samsung.com

ORCID <https://orcid.org/0000-0002-9070-9296>