



개선된 Chow 내시경적 수근관 감압술의 합병증

김희준^{1,2} · 이현주^{1,2} · 김풍택³ · 전인호⁴ · 경희수^{1,2} · 이석중⁵ · 정영수¹

¹경북대학교병원 정형외과, ²경북대학교 의과대학 정형외과학교실, ³대구박병원, ⁴울산대학교 의과대학 서울아산병원 정형외과학교실, ⁵계명대학교 의과대학 동산의료원 정형외과학교실

Complications of Modified Chow's Two-Portal Technique in Endoscopic Carpal Tunnel Release

Hee-June Kim^{1,2}, Hyun-Joo Lee^{1,2}, Poong-Taek Kim³, In-Ho Jeon⁴, Hee-Soo Kyung^{1,2}, Suk-Joong Lee⁵, Young-Soo Jung¹

¹Department of Orthopaedic Surgery, Kyungpook National University Hospital, Daegu, Korea

²Department of Orthopaedic Surgery, School of Medicine, Kyungpook National University, Daegu, Korea

³Daegu Park's Hospital, Daegu, Korea

⁴Department of Orthopedic Surgery, Asan Medical Center, University of Ulsan College of Medicine, Seoul, Korea

⁵Department of Orthopaedic Surgery, Dongsan Medical Center, Keimyung University School of Medicine, Daegu, Korea

Purpose: Endoscopic carpal tunnel release has gained popularity as a primary surgical option for carpal tunnel release. The purpose of this study was to evaluate the complication of endoscopic carpal tunnel release using modified Chow's extrabursal dual-portal technique in a large cohort in a single center.

Methods: Data of 2,248 wrists in 1,438 patients who underwent endoscopic carpal tunnel release by the extrabursal dual-portal technique were collected retrospectively from 2000 to 2016. Clinically, postoperative symptom was assessed, and complications were reported.

Results: At the final follow-up, the complication rate was 2.8% including digital nerve injury and tendon injury. Except for 16 hands, the patients showed recovery from the initial symptoms.

Conclusion: Extrabursal modified Chow's dual-portal technique is a reliable and safe method to treat carpal tunnel syndrome with minimal complications.

Key Words: Carpal tunnel syndrome, Endoscopic carpal tunnel release, Complications

INTRODUCTION

Carpal tunnel syndrome (CTS) is one of the most common compression neuropathy in the upper limb caused by the constriction of the median nerve, which passes under

the transverse carpal ligament (TCL). Surgical treatment should be considered when the symptom persists even after conservative treatment or for a relapsing case. The surgical carpal tunnel release method can be divided into open or endoscopic surgery. The safety and effectiveness

Received January 21, 2019, Revised [1] May 22, 2019, [2] July 15, 2019, Accepted July 15, 2019

Corresponding author: Hyun-Joo Lee

Department of Orthopaedic Surgery, Kyungpook National University Hospital, 130 Dongduk-ro, Jung-gu, Daegu 41944, Korea
TEL: +82-53-200-5628, FAX: +82-53-422-6605, E-mail: hjleeleehj@gmail.com, ORCID: <https://orcid.org/0000-0003-2837-3434>

Copyright © 2019 by Korean Society for Surgery of the Hand, Korean Society for Microsurgery, and Korean Society for Surgery of the Peripheral Nerve. All Rights reserved.
This is an Open Access article distributed under the terms of the Creative Commons Attribution Non-Commercial License (<http://creativecommons.org/licenses/by-nc/4.0/>) which permits unrestricted non-commercial use, distribution, and reproduction in any medium, provided the original work is properly cited.

of open carpal tunnel release (OCTR) treatment were reported by Phalen et al.¹. In 1989, Okutsu et al.² reported a portal technique of endoscopic carpal tunnel release (ECTR) that could reduce the incision on the palm. After that, Chow reported a two-portal technique with rapid recovery with decreased scarring and postoperative pain³. The advantage of ECTR includes reduced postoperative pain by minimizing the surgical incision and early return to work like in other minimally invasive operative technique⁴. About its complication, surgeons have reported neurovascular or tendon injury with an incidence of 4%-6.2%⁴⁻¹². The trocar with scopy can be inserted into the carpal tunnel intrabursal or extrabursally. In extrabursal technique, the trocar is out of the bursa, thus the risk of tendon injury can be reduced. The complications reduced by changing the surgical technique from transbursal to extrabursal, Nagle et al.¹² reported a lower incidence of complications, in which extrabursal insertion of trocar was performed. By improving the surgical technique and surgeon's skill, the complication rate of ECTR might decrease and its success rate might increase¹³. The purposes of this study was to show the safety of ECTR and eliminate the fear of hand surgeons for ECTR by determining the complication rate of ECTR in a large cohort from a single center using modified Chow's extrabursal dual-portal technique.

MATERIALS AND METHODS

Following Institutional Review Board approval, we retrospectively reviewed data of 2,487 wrists in 1,603 patients were collected retrospectively from 2000 to 2016. For the surgical indication, we tried ECTR for every cases excepting CTS with space-occupying lesion in ultrasonogram or stiff wrist after trauma. This study was approved by the Institutional Review Board of the Kyungpook National University Hospital (IRB No. 2016-11-014). Study inclusion criteria was cases of ECTR. Exclusion criteria was 1) cases due to hemodialysis because of the high rate of recurrence and symptom persistence¹⁴, 2) cases with less than 1-year follow-up. Fifty six cases were excluded by this exclusion criteria. After exclud-

ing 179 cases (129 patients) which original transbursal Chow's two-portal technique was performed for CTS from January 1996 to May 2000 and 2,248 cases (1,438 patients) which modified Chow's two-portal technique was performed from June 2000 to December 2016 were included.

Among 1,438 patients, 18 underwent ECTR before June 2000 by transbursal technique. The most common cause was idiopathic in most cases, except one case of gout and 28 cases of trauma related. Both operations were performed simultaneously in 665 cases, on the right wrist in 530 cases and the left wrist in 388 cases. The mean age of the patients was 60.5 years (range, 20-84 years).

CTS was diagnosed on the basis of the results of clinical examinations, including positive Tinel sign, positive Phalen test result, and the typical sensory change in the median nerve territory and was confirmed by nerve conduction studies in all cases except 340 cases. Two hand surgeons assessed the patients and performed the physical examination.

Surgical indications included symptoms resistant to conservative treatment, including splinting, local injection of corticosteroids into the carpal tunnel, and oral corticosteroid treatment.

All the patients underwent modified Chow's extrabursal dual-portal technique described by Nagle et al.¹² using the ECTRA II system (Smith & Nephew Dyonics Inc., Andover, MA, USA). Briefly, extrabursal technique is different from the original transbursal technique by the placement of the trocar under local anesthesia.

1. Postoperative rehabilitation and follow-up

Wet dressing for 1 day was applied with an elastic bandage. Hand elevation, and grip and release exercise were encouraged. One day after the operation, the dressing was changed to a simple dressing. The patients were followed up until they did not complain of any tingling sensation. Patients with thenar atrophy were followed up until the symptom relapsed.

2. Evaluations

The clinical results of physical examination, including positive Tinel sign and Phalen test, and tingling sensation in typical territory of median nerve postoperatively, were reviewed by retrospective chart review. However, for patients without adequate description, we had revisited patients or performed telephone survey. Two hand surgeons and one more orthopaedic fellow assessed the patients and performed the physical examination at the final follow-up.

The patients who were not followed up after operation were evaluated through a telephone survey.

Treatment failure was defined as a recurrence or persistent sensory symptom. Recurrence was defined as the development of previous symptoms after complete resolution. Persistent symptom was defined as a continuing previous symptom even after the surgery. Except for recurrence and persistent symptoms, we considered other cases as successfully treated when the Tinel sign was negative and the subjective symptom was reduced to less than 10% subjectively of the preoperative symptom. However, if the patients showed remaining atrophy but resolved tingling sensation, we counted them as successful results. Remaining muscle atrophy was considered a sequela, not a treatment failure.

Major complications were defined as nerve, vessel, and tendon injuries. Complications were recorded, including nerve, artery, and tendon injuries, and infection. Others were considered minor complications. Neuropraxia was defined as a persistent new tingling symptom after surgery, lasting 3 months, counted separately from nerve injury. Cases of recurrence and persistent symptom were also collected. Conversion to OCTR during ECTR was also checked.

RESULTS

All hands except 16 hands showed resolution of clinical symptoms. The number of cases with abductor pollicis brevis atrophy was 229 cases. All cases recovered atrophy except 14 cases.

Conversion to OCTR during operation occurred in 5 cases, the causes for conversion were as follows: post-injection adhesion around the inlet portal, anomalous large muscle in the tunnel, flexor tendon rupture, accidental insertion of the trocar into the Guyon canal (i.e., poor surgical skill in the early period of practice of LHJ), and inability of hyperextension of the wrist joint. Persistent symptoms were reported in 5 cases. One case was treated with ECTR and another was treated with OCTR. One partial median nerve injury in a 49-year-old female patient happened just distal to the proximal margin of the TCL. Direct perineural repair was performed. One year after the surgery, the patient underwent sural nerve cable graft for causalgia by a neuroma in continuity. Twenty-eight cases of superficial palmar branch injury. All the cases were skillfully neglected.

Seven cases of tendon injury happened including three 5th flexor digitorum superficialis (FDS) rupture, one 4th FDS rupture, one 4, 5th FDS rupture, and one 5th FDS (Fig. 1), flexor digitorum profundus (FDP) partial rupture, and one palmaris longus rupture. The cases with 5th complete FDS and 5th partial FDP rupture was treated with primary repair. Others were skillfully neglected. Among 21 neuropraxia cases, 18 showed complete recovery after a mean of 5.5 months (range, 1-17 months), and

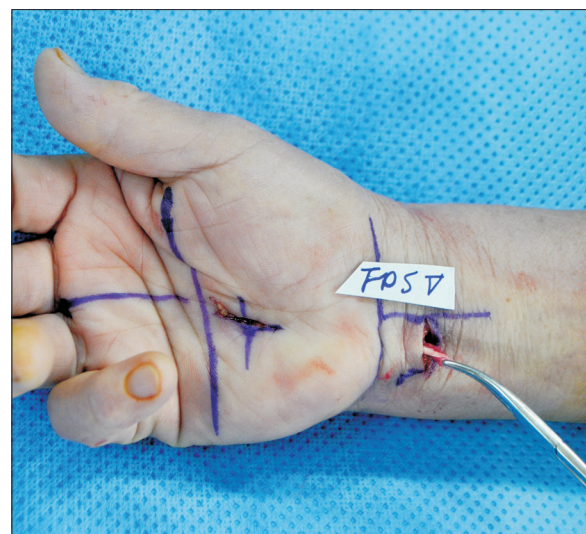


Fig. 1. A 73-year-old female with a transected fifth flexor digitorum superficialis tendon during endoscopic carpal tunnel release. The tendon injury was skillfully neglected.

Table 1. Complications

Complication	No. of case
Superficial palmar arch injury	28
Neuropraxia	21
Nerve injury	1
Incomplete TCL dissection	1
Tendon injury	7
Infection	5
Total	63 (2.8)

Values are presented as number only or number (%).

TCL: transverse carpal ligament.

3 cases showed persistent tingling sensation on the fourth finger at final follow-up. Wrong diagnosis with an undetermined cause was treated with release of the lacertus. Of 5 infection cases, 4 were treated with oral antibiotics in an outpatient clinic basis and one was treated with IV antibiotics. However, none of the patients needed admission. We have experienced 9 recurrent cases (Table 1).

DISCUSSION

In our study, total complication rate was 2.8% with eight major complication cases. Since Okutsu et al.² described the first successful experience in his one portal technique, many surgeons would like to perform carpal tunnel release with minimally invasive technique. However, under-visualization also brought the possible complication rate like in other minimally invasive surgery. Complications after ECTR, including injury to nerve, vessel, or tendon; incomplete incision to the TCL; reflex sympathetic dystrophy; hematoma; and infection could occur. The incidence of complication was reported by Resnick and Miller to be 6% in the single portal technique and 5% in the dual portal technique¹⁵. Malek et al.¹⁶ reported 4.8% for the transbursal method and 1.2% for the extrabursal technique in 10,624 cases; the transbursal technique had a higher incidence of severe complications, including major nerve and vessel injuries, and cutting of the flexor tendon. In our study, by showing low complication rate, we can prove that ECTR especially via extrabursal technique is safe procedure.

After Palmer et al.¹⁷ have reported higher rate of com-

plications in ECTR than in OCTR, there have been many studies on comparison between OCTR and ECTR^{8,11,17,18}. Recently, Vasiliadis et al.¹⁸ reported similar rate of complications between OCTR and ECTR. Vasiliadis et al.¹⁸ also assumed that reduced recurrences and reoperations with ECTR in studies that are more recent is due to the effect of a learning curve⁸. In our study, we also experienced that most complications had happened in the early period. In addition to the low overall complication rate, the complication rate can be reduced by a learning curve. In spite of its inherent weakness that carpal tunnel pressure is elevated by the insertion of a trocar, many studies have shown advantages of ECTR⁸. However, since surgeon cannot visualize the anatomy structures directly, not many surgeons utilize this method. Only 12% of hand surgeons are using ECTR in the United States⁹.

When summarizing our and previous results, the modified extrabursal technique showed a lower incidence of complications than the original transbursal technique (4.1%)¹⁹, with the cannula passing through the flexor tendon bursa, as reported by Nagle et al.¹². Nagle et al.¹² reported a complication rate of 1.7% in 278 cases and Benson et al.¹¹ reported 1.05% in 15,787 cases with the extrabursal technique using dual portals. By developing new technique, the ECTR can be performed more safely.

Even though extrabursal modified Chow's dual-portal technique decreases the complication rate, inherent disadvantage still remains. Because the cannula increases the pressure inside the carpal tunnel, there is a risk of direct nerve compression. Recent studies have shown that recoverable nerve injury is higher in ECTR group^{4,20}. In our study, neuropraxia took large portion of complications even though permanent injury was only one case. Thus, surgeon should effort to reduce the time with the cannula inside the carpal tunnel. Releasing the proximal and distal margin of the TCL also can help to reduce the pressure. And local anesthesia can help surgeons monitor neuropraxia symptoms during surgery. However, superficial palmar branch injury can be avoided by positioning the distal portal more proximal, which means this injury might be from technical error and avoidable. For 7 cases of tendon injury, we assumed that the cause was inadver-

tent introduction of the blade into the bursa.

Our study has limitations. Nonetheless our study dealt big cohort, this study was performed in retrospective manner. Second, we could not obtain objective assessment tool. Electromyography was performed in many patients, the invasiveness of the study and the cost hinder us to do it as a postoperative evaluation. Electromyography was not performed in all cases before and after operation. However, the goal of this study was to report the complications with modified Chow's two portal technique in large cohort. For more precise description about the electromyographic study should be included in the future study.

CONCLUSION

Consequently, ECTR using extrabursal modified Chow's dual-portal technique could be the good surgical technique with minimal complications rate.

CONFLICTS OF INTEREST

The authors have nothing to disclose.

ACKNOWLEDGEMENTS

This work was supported by the National Research Foundation of Korea (NRF) grant funded by the Korea government (MSIT) (No. NRF-2017R1C1B5017140).

REFERENCES

- Phalen GS, Gardner WJ, La londe AA. Neuropathy of the median nerve due to compression beneath the transverse carpal ligament. *J Bone Joint Surg Am.* 1950;32A:109-12.
- Okutsu I, Ninomiya S, Takatori Y, Ugawa Y. Endoscopic management of carpal tunnel syndrome. *Arthroscopy.* 1989;5:11-8.
- Chow JC. Endoscopic release of the carpal ligament: a new technique for carpal tunnel syndrome. *Arthroscopy.* 1989;5:19-24.
- Zuo D, Zhou Z, Wang H, et al. Endoscopic versus open carpal tunnel release for idiopathic carpal tunnel syndrome: a meta-analysis of randomized controlled trials. *J Orthop Surg Res.* 2015;10:12.
- Agee JM, McCarroll HR Jr, Tortosa RD, Berry DA, Szabo RM, Peimer CA. Endoscopic release of the carpal tunnel: a randomized prospective multicenter study. *J Hand Surg Am.* 1992;17:987-95.
- Brown RA, Gelberman RH, Seiler Jr, et al. Carpal tunnel release. A prospective, randomized assessment of open and endoscopic methods. *J Bone Joint Surg Am.* 1993;75:1265-75.
- Sennwald GR, Benedetti R. The value of one-portal endoscopic carpal tunnel release: a prospective randomized study. *Knee Surg Sports Traumatol Arthrosc.* 1995;3:113-6.
- Vasiliadis HS, Georgoulas P, Shrier I, Salanti G, Scholten RJ. Endoscopic release for carpal tunnel syndrome. *Cochrane Database Syst Rev.* 2014;(1):CD008265.
- Smetana BS, Zhou X, Hurwitz S, Kamath GV, Patterson JM. Effects of hand fellowship training on rates of endoscopic and open carpal tunnel release. *J Hand Surg Am.* 2016;41:e53-8.
- Palmer AK, Toivonen DA. Complications of endoscopic and open carpal tunnel release. *J Hand Surg Am.* 1999;24:561-5.
- Benson LS, Bare AA, Nagle DJ, Harder VS, Williams CS, Visotsky JL. Complications of endoscopic and open carpal tunnel release. *Arthroscopy.* 2006;22:919-24, 924.e1-2.
- Nagle D, Harris G, Foley M. Prospective review of 278 endoscopic carpal tunnel releases using the modified chow technique. *Arthroscopy.* 1994;10:259-65.
- Sabesan VJ, Pedrotty D, Urbaniak JR, Aldridge JM 3rd. An evidence-based review of a single surgeon's experience with endoscopic carpal tunnel release. *J Surg Orthop Adv.* 2012;21:117-21.
- Park H, Lee DS, Yun TK, Ahn DS. Carpal tunnel syndrome in patients undergoing long-term hemodialysis therapy: clinical characteristics and results of surgical treatment. *J Korean Soc Surg Hand.* 2015;20:89-95.
- Resnick CT, Miller BW. Endoscopic carpal tunnel release using the subligamentous two-portal technique. *Contemp Orthop.* 1991;22:269-77.
- Malek M, Chow J, Veech D. Complications of Endoscopic

- carpal tunnel release: analysis of 10624 cases. Paper presented at: Annual meeting of the American Association of Orthopaedic Surgeons; 1994; New Orleans, USA.
17. Palmer DH, Paulson JC, Lane-Larsen CL, Peulen VK, Olson JD. Endoscopic carpal tunnel release: a comparison of two techniques with open release. *Arthroscopy*. 1993; 9:498-508.
18. Vasiliadis HS, Nikolakopoulou A, Shrier I, et al. Endoscopic and open release similarly safe for the treatment of carpal tunnel syndrome. A systematic review and meta-analysis. *PLoS One*. 2015;10:e0143683.
19. Kim PT, Kim ID, Ahn HS, Park HJ. The experience of endoscopic carpal tunnel release by Chow's method. *J Korean Soc Surg Hand*. 2000;5:223-6.
20. Sayegh ET, Strauch RJ. Open versus endoscopic carpal tunnel release: a meta-analysis of randomized controlled trials. *Clin Orthop Relat Res*. 2015;473:1120-32.

개선된 Chow 내시경적 수근관 감압술의 합병증

김희준^{1,2} · 이현주^{1,2} · 김풍택³ · 전인호⁴ · 경희수^{1,2} · 이석중⁵ · 정영수¹

¹경북대학교병원 정형외과, ²경북대학교 의과대학 정형외과학교실, ³대구박병원,
⁴울산대학교 의과대학 서울아산병원 정형외과학교실, ⁵계명대학교 의과대학 동산의료원 정형외과학교실

목적: 본 연구의 목적은 개선된 Chow의 활액낭의 양측 입구 방법을 이용하여 수근관 감압술을 시행한 환자들의 임상결과와 합병증을 기술하고자 한다.

방법: 2000년 6월부터 2016년 12월까지 활액낭의 양측 입구 방법을 이용하여 수근관 감압술을 시행한 1,438명 2,248예를 대상으로 하였다. 임상적 결과로 수술 후 증상과 합병증을 조사하였다.

결과: 최종 추시 시 합병증은 정중신경, 굴곡건 손상 등으로 2.8%에서 발생하였으며, 16예를 제외한 모든 환자들은 수술 전 증상에서 모두 회복되었다.

결론: 개선된 Chow의 활액낭의 양측 입구 방법을 이용한 수근관 감압술은 수근관 증후군 치료에 합병증이 적은 안전한 방법이다.

색인단어: 수근관 증후군, 내시경적 수근관 감압술, 합병증

접수일 2019년 1월 21일 수정일 1차: 2019년 5월 22일, 2차: 2019년 7월 15일 게재확정일 2019년 7월 15일

교신저자 이현주

41944, 대구시 중구 동덕로 130, 경북대학교병원 정형외과

TEL 053-200-5628 FAX 053-422-6605 E-mail hjleeleehj@gmail.com

ORCID <https://orcid.org/0000-0003-2837-3434>