



형광물질을 이용한 사무직 근로자의 손가락 감각 우수부위 실험

김홍일

고신대학교 의과대학 성형외과학교실

Experiment of Radial and Ulnar Sides Sensory Dominance of the Digits in Office Workers by Fluorescent Material Painting

Hong Il Kim

Department of Plastic Surgery, Kosin University College of Medicine, Busan, Korea

Purpose: The radial side of fingers are thought to be the dominant sensory side. With the development of electronic devices and lifestyle changes, we think this should be re-evaluated.

Methods: We painted fluorescent material on both hands of 26 office workers. Each finger was divided into the ulnar and radial compartment. We analysed how much fluorescent material remained by comparing two pictures, before and after work.

Results: On the dominant hand, significantly more fluorescent material remained on the radial side of the ring and little finger compared with the other compartment. On the non-dominant hand, there was no statistical difference between compartments.

Conclusion: In this study, the radial sides of the ring and little finger on the dominant hand seem to be less useful in modern life and these compartments can be sensibly less important. This observation can be used as a basic data for re-evaluation of the sensory dominant sides of fingers and it may be helpful in various hand surgery.

Key Words: Fingers, Sensation, Tissue donors

INTRODUCTION

Fingers have dominant sensory sides and non-dominant sensory sides that should be considered during hand surgery, particularly when selecting a donor for heterodigital island flaps. One text proposes that the radial side of the index and middle finger and the ulnar side of the ring and little fingers are dominant sensory sides¹. Other literature

suggests that each finger has its own unique sensibility value. Specifically, the thumb, the radial sides of the index and middle fingers, and the ulnar side of the little finger are highly valuable due to their sensibility. Alternatively, the ulnar sides of the middle and ring finger are less valuable and constitute donor areas². Traditionally, the radial sides of fingers, opposite the thumb, are considered dominant sensory sides³⁻⁵. This concept, however,

Received February 16, 2019, Revised [1] March 18, 2019, [2] May 13, 2019, Accepted May 29, 2019

Corresponding author: Hong Il Kim

Department of Plastic Surgery, Kosin University College of Medicine, 262 Gamcheon-ro, Seo-gu, Busan 49267, Korea

TEL: +82-51-990-6131, FAX: +82-51-990-3005, E-mail: immtkg4u@daum.net, ORCID: https://orcid.org/0000-0002-5505-9945

Copyright © 2019 by Korean Society for Surgery of the Hand, Korean Society for Microsurgery, and Korean Society for Surgery of the Peripheral Nerve. All Rights reserved.

This is an Open Access article distributed under the terms of the Creative Commons Attribution Non-Commercial License (<http://creativecommons.org/licenses/by-nc/4.0/>) which permits unrestricted non-commercial use, distribution, and reproduction in any medium, provided the original work is properly cited.

is outdated and based on activities commonly performed prior to the advent of modern devices. These activities include writing, opening doors, and grasping things when working.

The modern day increase in the use of electronic devices has made our lives convenient, while, at the same time, changing our patterns of finger use. These conveniences, however, have had unexpected consequences. One such consequence was that specific areas of the fingers became more important for electronic device use. Areas previously thought to be non-dominant are now important for electronic device utilization. Therefore, the traditional concept of dominant sensory sides of the fingers, based on writing and use of other tools, may be outdated. To address this, we investigated finger areas that are more commonly used in office workers that utilize electronic devices.

MATERIALS AND METHODS

We selected 26 office workers mainly in computer work (11 male, 15 female; aged 26-54 years old; average age: 33) for this study. The participants' hand dominance was surveyed prior to the experiment. We painted fluorescent ink (highlighter ink; Pelikan Co., Hanover, Germany) on the volar sides of the participants' fingers and palms. The fluorescent material was mixed with distilled water prior to application. This material is colorless and harmless to the human body and therefore did not

interfere with daily life or work. To validate the staining technique, we used the same concentration and amount of fluorescent dye. A baseline photograph was taken under special lighting (SIGMAB20; Sunsea Industrial Co., Ltd., Incheon, Korea), and the participants underwent 6-8 hours of work and daily life as usual. All volunteers were told not to wash or wipe their hands until the end of the experiment to prevent the elimination of the fluorescent material. Photographs of the participants' hands were taken after the work period ended and analysed to determine the amount of fluorescent material remaining. To take photos under the same conditions, the camera (EOS 450D; Canon Co., Tokyo, Japan) was fixed in position with an ISO 400, the shutter speed was set at 1/30 second, and participants' hands were positioned in the same location and manner as the first photograph and fixed with special lighting.

We used 'ImageJ' software, developed and provided for free by the National Institute of Health (Bethesda, MD, USA; <http://rsbweb.nih.gov/ij/>), to analyse the photographs. Each finger was divided into an ulnar and radial side (Fig. 1), and the brightness of each side of the finger was compared with the baseline photograph (Fig. 2).

Data were analysed using the Kruskal–Wallis test and post-hoc according to Conover for comparing ten compartments simultaneously in each hand. Mann–Whitney test was used to compare the ulnar and radial side dominance in each finger. MedCalc software (ver. 19.03, Ostend, Belgium) was used. All statistical significance was

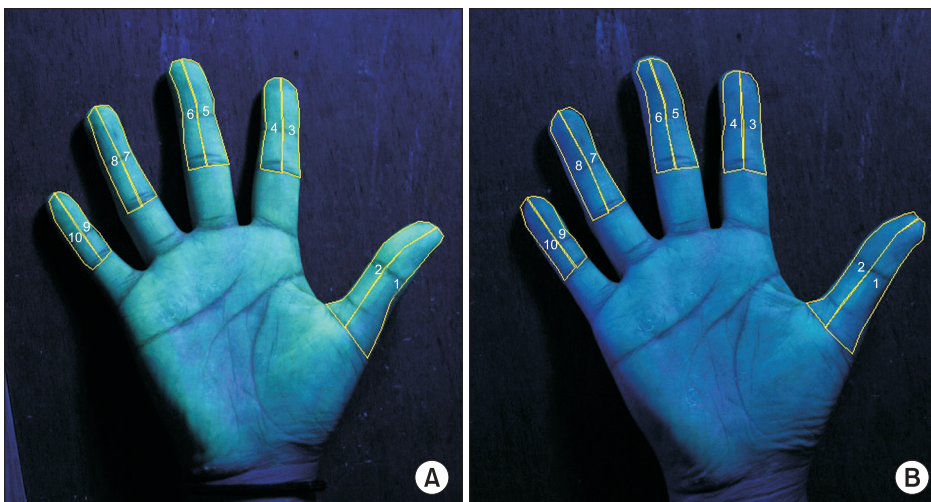


Fig. 1. (A) The baseline photograph shows each finger divided into the radial and ulnar side. (B) We analysed how much fluorescent material remained after a workday using ImageJ. ① Radial side of the thumb, ② ulnar side of the thumb, ③ radial side of the index finger, ④ ulnar side of the index finger, ⑤ radial side of the middle finger, ⑥ ulnar side of the middle finger, ⑦ radial side of the ring finger, ⑧ ulnar side of the ring finger, ⑨ radial side of the little finger, and ⑩ ulnar side of the little finger.

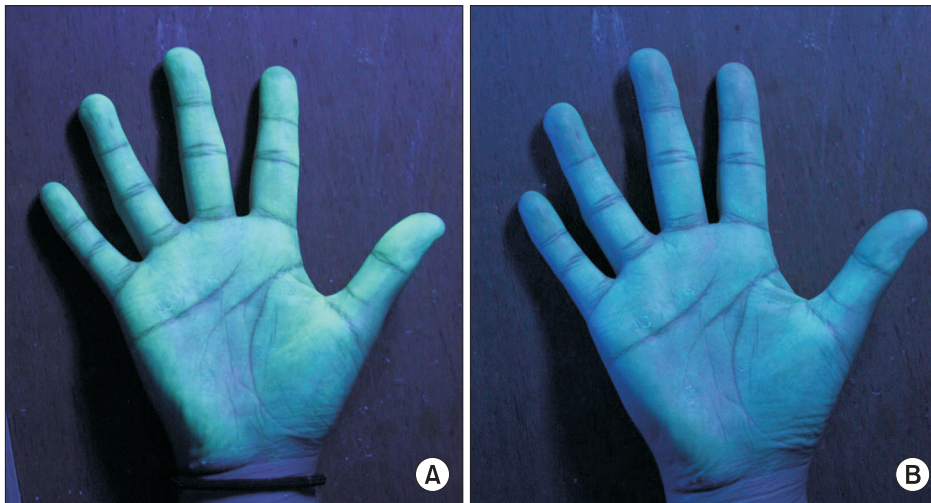


Fig. 2. (A) A baseline photograph is shown. (B) A photograph after 8 hours of work is shown.

Table 1. Results of the finger sensibility dominance of study subjects

	Dominant hand			Non-dominant hand		
	Remaining fluorescent material (%)	Statistical value of sensibility dominance	p-value*	Remaining fluorescent material (%)	Statistical value of sensibility dominance	p-value*
Thumb			0.985			0.522
Radial	72.67±10.10	Dominant		74.17±11.28	None	
Ulnar	72.61±9.31	Dominant		75.84±10.13	None	
Index			0.756			0.264
Radial	72.40±8.70	Dominant		72.03±10.92	None	
Ulnar	71.45±9.45	Dominant		75.81±10.24	None	
Middle			0.400			0.360
Radial	72.95±9.87	Dominant		73.88±9.79	None	
Ulnar	70.59±10.63	Dominant		75.71±9.02	None	
Ring			0.002			0.431
Radial	77.97±9.30	Non-dominant		76.24±8.83	None	
Ulnar	71.23±10.52	Dominant		75.04±9.69	None	
Little			<0.001			0.100
Radial	78.71±9.61	Non-dominant		77.46±8.54	None	
Ulnar	70.45±9.71	Dominant		74.84±9.62	None	
p-value [†]		<0.001			0.434	

Values are presented as mean±standard deviation.

*Mann–Whitney test. [†]Kruskal–Wallis test.

determined based on a significance level of 0.05.

RESULTS

Participants were all office workers. All of them were in charge of dealing with computers, receiving calls or working with documents. Smartphones and tablet PCs have also been used frequently. But most of the work was dealing with computers. The participants worked 6 to 8

hours (average 6.5 hours). Only one person was left hand dominant. On average, 74% of the fluorescence material remained after the work period, 73% remained on the dominant hand and 75% remained on the non-dominant hand. In the dominant hand, the residual fluorescence material was 73% on the thumb radial side, 73% on the thumb ulnar side, 72% on the index finger radial side, 71% on the index finger ulnar side, 73% on the middle finger radial side, 71% on the middle finger ulnar side,

78% on the ring finger radial side, 71% on the ring finger ulnar side, 79% on the little finger radial side, and 70% on the little finger ulnar side. In the non-dominant hand, the residual fluorescence material was 74% on the thumb radial side, 76% on the thumb ulnar side, 72% on the index finger radial side, 76% on the index finger ulnar side, 74% on the middle finger radial side, 76% on the middle finger ulnar side, 76% on the ring finger radial side, 75% on the ring finger ulnar side, 77% on the little finger radial side, and 75% on the little finger ulnar side (Table 1).

In the dominant hand, the radial sides of ring and little finger retained significant more fluorescent material than other compartments ($p < 0.001$). However, in the non-dominant hand, no compartments displayed a statistically significant difference (Table 1).

When ulnar and radial side of each finger were analysed, there was a significant difference between ulnar side and radial side of ring and little finger of dominant hand. The other fingers were statistically not significant (Table 1).

DISCUSSION

The sensation is equally important to hand function. Many neurovascular surgeries have been developed to restore finger sensation. To perform these surgeries, hand surgeons must be aware of dominant and non-dominant sensory sides of fingers. The dominant sensory sides of fingers in our concept are thought to be more used for touching, rubbing, pressing, holding and feeling. These sides should be used as a reference for selecting the portion to be reconstructed and the portion to be sacrificed through surgery. However, views differ regarding dominant versus non-dominant sensory areas of the fingers. In 1961, Tubiana and Duparc² suggest that the value of sensibility is high on the entire thumb, the radial sides of the index and middle fingers, and the ulnar side of the little finger. However, the values of the ulnar sides of the middle and ring fingers are lower than others². It has also been suggested that the radial sides of the index and middle fingers, and the ulnar sides of the ring and little fingers are dominant sides, particularly to provide

protective sensation from trauma^{1,6}. In 1996, Puckett et al.⁴ introduced a quartering technique to reduce donor morbidity of the neurovascular island flap and they used the ulnar side of the ring finger as the donor site. In 2006, Hashem³ introduced the idea that the opposite part of the thumb is dominant and that the ulnar sides of fingers are non-dominant. Finally, in 2013, Silva et al.⁵ suggested that the ulnar pulp of the thumb and the radial pulp of all other fingers are dominant while introducing the pulp switch flap. As shown, opinions regarding dominant sensory sides of fingers vary, likely due to a lack of accurate research into finger side sensory dominance. So, the author designed a new experiment that can identify finger use area in modern life.

Daily activities related to finger use are numerous and include writing, turning a key, and opening a heavy door⁷. However, the development of machinery and electronic devices has altered and added to this list of the most common activities. In the past, we commonly created documents with pens. Now we use a keyboard and a mouse. Turning a key is replaced by a button type lock. Starting an engine can be done by pressing a single button. Instead of push open a heavy door, we open doors with a button. Development of electronic devices and machines such as the automated teller machine or elevator changed our lifestyle. We also use many haptic devices and smartphones. All of these new activities require the use of the ulnar sides of fingers (Fig. 3).

This pattern of use is different from the traditional pattern for the dominant sensory zone. The results of this study show that the radial sides of the ring and little finger on dominant hand are used significantly less. But, the other compartments of the thumb and fingers showed similar use. According to these results, there are some differences from traditional sensory dominant sides of fingers. The ulnar sides of index and middle finger were not considered important in the past, but they are used with no significant difference from other compartments. On the other hand, the radial sides of ring and little finger which were considered important in some of past studies were not much used in this study. Further studies are needed but these findings may be used as basic data for



Fig. 3. Activities require the use of the ulnar compartment more so than before. (A) Typing keyboard needs sensation of ulnar compartment. (B) Also using a mouse needs sensation of ulnar compartment. (C) Button type lock, or (D) opening a door with a button also require ulnar compartment more than radial compartment. Many electronic devices and machines such as (E) automated teller machine or (F) elevator are controlled with fingers especially ulnar side of fingers. Recently, we use many (G) haptic devices and (H) smartphones which are mostly run by ulnar sides of fingers.

re-establishing the sensory dominant sides of fingers. Furthermore, these findings may be helpful in better donor site selection for the neurovascular island flap and also be helpful to select the nerves to be reconstructed preferentially when reattaching the fingers.

But, in non-dominant hand, there was no statistically different compartment. We think it is because the tasks in office work are mostly single hand needed, except the keyboard job.

The standard deviation is large in our results because the data is non-parametric. The reason why our data is non-parametric is first, the business characteristics and the frequency of hand use of each person is different. Second, it was not easy to do one's work without washing hands for a long time, and it made experimental time variation which is responsible for the large standard deviation. However, our results were statistically analysed using the nonparametric Kruskal–Wallis tests and Mann–Whitney test. And highly significant results were obtained on dominant hand.

There are several limitations of this study. One is that it was only performed in office workers. Different results

may be observed in manual workers or in other groups of individuals. To address this issue, further study is needed. However, many manual workers, due to injury, cannot perform their tasks and are apt to relocate to a simple office job. The results presented for office workers are important, particularly because office jobs are common and often a second career choice for manual workers. Second is that the experiment was not performed in the way that giving a task and then measure the elimination of fluorescent materials. It may have been lost by a simple touch, strong grasp or simply putting a hand on a desk. However, the author tried to estimate the approximate use of finger compartments through the daily life of modern office workers and it seems to have achieved those goals. In further clinical studies, task-based measurement research will be needed. Another limitation of this study is the lack of evidence in the experimental method. Many articles on finger sensory dominance have been reviewed, but there were no studies based on experiment for finger sensory dominance. Therefore, this study is the first study to evaluate the finger sensory dominance and non-dominance by experiment.

CONCLUSION

As a result of this experiment, many fluorescent materials remained on the radial side of ring and little finger of dominant hand. This was statistically significant in the Kruskal–Wallis test, in which 10 compartments of the finger were simultaneously analyzed, and in the Mann–Whitney test, which compared the radial side and ulnar side of each finger. Therefore, this experiment shows that the two compartments tend to be less used in contemporary office workers, and the author believes that these compartments are less sensibly important. Alternatively, other compartments are found to be used with similar significance. Further evaluation and clinical trials are needed for the re-evaluation of sensory dominance of fingers. However, these results can be used as basic data for further study.

CONFLICTS OF INTEREST

The author has nothing to disclose.

ACKNOWLEDGEMENTS

This study was supported by a grant from Kosin University College of Medicine.

REFERENCES

1. Khouri RK, Badia A. Reconstructive surgery of individual digits (excluding thumb). In: Mathes SJ, Hentz VR, editors. Plastic surgery. Volume VII. 2nd ed. Philadelphia: Saunders; 2006. 207-52.
2. Tubiana R, Duparc J. Restoration of sensibility in the hand by neurovascular skin island transfer. *J Bone Joint Surg Br.* 1961;43:474-80.
3. Hashem MA. The heterodigital neurovascular island flap: a sensible solution for difficult digital defects. *Kasr El Aini J Surg.* 2006;7:55-62.
4. Puckett CL, Howard B, Concannon MJ. Primary closure of the donor site for the Littler neurovascular island flap transfer. *Plast Reconstr Surg.* 1996;97:1062-4.
5. Silva JB, Pires FK, Teixeira LF. The pulp switch flap: an option for the treatment of loss of the dominant half of the digital pulp. *J Hand Surg Eur Vol.* 2013;38:948-51.
6. Ranney DA, Lennox WM. The protective value of a neurovascular island pedicle transfer in hands partially anesthetic due to ulnar denervation in leprosy. *J Bone Joint Surg Am.* 1978;60:328-34.
7. Hayashi H, Shimizu H. Essential motion of metacarpophalangeal joints during activities of daily living. *J Hand Ther.* 2013;26:69-73; quiz 74.

형광물질을 이용한 사무직 근로자의 손가락 감각 우수부위 실험

김홍일

고신대학교 의과대학 성형외과학교실

목적: 전통적으로 손가락의 요측면이 감각 우수 부위로 여겨진다. 그러나 전자 장치 및 생활 방식의 변화에 따라 손가락의 감각 우수 부위가 재평가되어야 한다고 생각한다.

방법: 26명의 사무직 근로자의 양손에 형광물질을 도포하여 각 손가락을 척측과 요측 구획으로 나누었다. 근무 전후의 두 사진을 비교하여 얼마나 많은 형광물질이 남아 있는지 분석하였다.

결과: 우세수의 약지 요측 구획과 소지 요측 구획에서 다른 구획과 비교하여 현저하게 많은 형광물질이 남아 있었다. 비우세수에서는 구획 간의 통계적으로 차이가 없었다.

결론: 이 연구를 통해 약지와 소지의 요측 구획이 다른 구획에 비하여 현대생활에서 덜 사용되며 감각적으로 덜 중요한 구획일 수 있다는 것을 알 수 있었다. 이 결과는 현대사회에서 손가락의 감각 우수 부위에 대한 재평가의 기초 자료로 활용될 수 있으며 나아가 여러 가지 수부 수술에 있어서 도움이 될 것으로 생각된다.

색인단어: 손가락, 감각, 공여부 조직

접수일 2019년 2월 16일 **수정일** 1차: 2019년 3월 18일, 2차: 2019년 5월 13일 **게재확정일** 2019년 5월 29일

교신저자 김홍일

49267, 부산시 서구 감천로 262, 고신대학교 의과대학 성형외과학교실

TEL 051-990-6131 **FAX** 051-990-3005 **E-mail** immmtkg4u@daum.net

ORCID <https://orcid.org/0000-0002-5505-9945>