

Acropigmentation Symmetrica of Dohi Treated with the Q-switched Alexandrite Laser

— A Case Report —

Ho Jung Lee, M.D., Gwang Seong Choi, M.D., Eun-So Lee, M.D.

*Department of Dermatology, Ajou University School of Medicine,
Suwon, Korea*

A few cases of reticulate acropigmentary disorders have been reported in Korea. Most of them were reticulate acropigmentation of Kitamura, but not acropigmentation symmetrica of Dohi. A 21 year-old male patient diagnosed as acropigmentation symmetrica of Dohi had been previously treated with various treatment methods unsuccessfully. Re-treatment with the Q-switched alexandrite laser (755 nm, 100nsec) showed a temporary improvement but a relapse of the lesion was experienced again. We describe a case of acropigmentation symmetrica of Dohi treated with the Q-switched alexandrite laser. (*Ann Dermatol* 9:(1)26~30, 1997).

Key Words : Acropigmentation symmetrica of Dohi, Alexandrite laser

Reticulate acropigmentation is a rare pigmentary disorder characterized by reticulate, brown pigmented macules on the dorsum of hands, feet and flexural areas.¹ It has been described only in a few white patients, whereas in Japan more than fifty cases have been reported on reticulate acropigmentation of Kitamura (RAPK).^{2,3} There are only a few references on these pigmentary disorders, and an adequate classification has not been established, yet. Dowling-Degos disease (DDD), reticulate acropigmentation of Kitamura (RAPK) and acropigmentation symmetrica of Dohi (Dohi) are some of the entities of this heterogeneous group.^{4,7}

Acropigmentation symmetrica of Dohi clinically shows acral punctate and reticulate hyperpigmentation with interspersed hypopigmented macules. There is neither atrophy on the pigmentary lesions nor palmar pits and breaks in the epidermal ridge patterns on the palms.

A few cases of reticulate acropigmentary disorders have been reported in Korea, but most of them were RAPK and not Dohi.^{4,8,9} We present a case on acropigmentation symmetrica of Dohi treated with the Q-switched Alexandrite laser (755 nm, 100nsec) in Korea.

CASE REPORT

A 21 year-old man had complained of a progressively spreading reticulate hyper- and hypopigmentation of his hands and feet since the age of 4. His sister and his cousin also had similar clinical manifestations. (Fig. 1) On examination, he had freckle-like, brownish-pigmented, small, reticulate macules over the dorsa of both hands and wrists, feet and ankles. We observed that the pigmented macules were of variable size and color which varied from light to dark brown. In addition, there were multiple variable sized depigmented macules with the same distribution. There was no atrophy over the reticulated pigmentation. (Fig. 2,3) He also had ephelids on his face. We obtained two biopsy specimens from a hyperpigmented and the hypopigmented macule on his hand. Histological findings of the hyper pigmented macule showed hyperpigmentation of the basal cell layer with

Received August 30, 1996.

Accepted for publication October 10, 1996.

Reprint request to : Eun-So Lee, M.D., Department of Dermatology, Ajou University School of Medicine, 5 Wonchon-dong, Paldal-ku, Suwon 442-749, Korea (Tel. 82-331-219-5192, FAX. 82-331-219-5189)

Table 1. Clinical and histopathological features of reticulate pigmentation

	Sites	Atrophy	Palmar pits/break of epi. ridge	Comedones or acneiform scars	Hypo. macules	Histopathological findings	Genetic
RAPK	acral	+	+	-	-	epidermal atrophy melanocyte proliferation	AD
DDD	flexures	-	-	+	-	normal histology or rete ridge proliferation melanocyte proliferation	AD
Dohi	acral	-	-	-	+	melanocyte proliferation absence of melanocytes in hypo. dense dermal melanocytes in hyper.	AD

RAPK : Reticulate acropigmentation of Kitamura

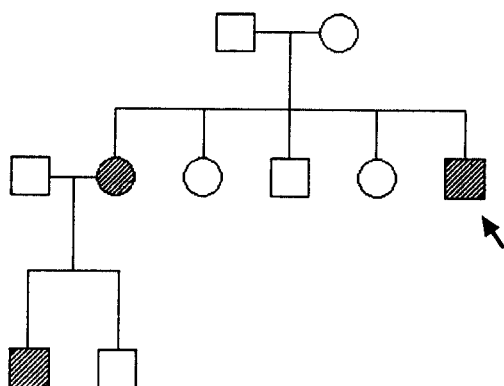
DDD : Dowling-Degos Disease(Reticulated pigmented anomaly of the flexures

Dohi : acropigmentation symmetrica of Dohi

Hypo : hypopigmentation

Hyper : hyperpigmentation

AD : Autosomal Dominant

**Fig. 1.** Pedgree of the patient.

densely aggregated dermal melanocytes in the upper dermis.(Fig. 4) On the hypopigmented macules, decreased pigmentation of the basal cell layer was observed in the epidermis by Fontana-Masson staining(Fig. 5). Epidermis of both lesions also showed hyperkeratosis.

The patient had formerly experienced many unsuccessful treatments at another clinic and insisted on treatment with the Q-switched Alexandrite laser at our clinic. The dorsa of his hands were treated with an intensity of 8 watts. The right hand was treated only once whereas the left hand was treated two to three times at intervals of two to three weeks. In addition, we obtained a biopsy

Fig. 2. Photograph showing multiple freckle-like, brownish-pigmented, small, reticulated macules over the dorsa of both hands and wrists. There was no atrophy over the reticulated pigmentation.

specimen from treated site two weeks later. Histological findings of the treated site showed markedly decreased pigmentation as compared with the untreated site(Fig. 6). There was a temporary improvement(Fig. 7) but at the end the treated le-

Fig. 3. The same lesions are shown on the dorsa of both feet and ankles

Fig. 4. A skin biopsy specimen of the hyperpigmented macule show hyperpigmentation of the basal cell layer with densely aggregated dermal melanocytes in the upper dermis (A : H & E stain, $\times 100$, B : Fontana-Masson stain, $\times 100$). Both S-100 stain and HMB-45 stain were positive on densely aggregated dermal cells in the upper dermis (C : S-100 stain, $\times 100$, D : HMB-45 stain, $\times 100$).

Fig. 5. On the hypopigmented macules, decreased pigmentation of the basal cell layer was observed in the epidermis (Fontana-Masson stain, $\times 100$).

Fig. 7. Photograph in 4 weeks after treatment showing the discolored hyperpigmented macules which also looked like hypopigmented areas.

sions returned to the original state again.

DISCUSSION

Fig. 6. On the treated sites of hyperpigmented macules, markedly decreased pigmentation of the basal cell layer and upper dermis was observed (A : H & E stain, $\times 100$, B : Fontana-Masson stain, $\times 100$).

Twelve cases of Acropigmentation symmetrica of Dohi were first studied by Dohi in 1920 and re-

ported by Komaya in 1924¹⁰. It occurs sporadically or is an inherited autosomal, dominant disorder. The onset is between 1 and 13 years and is primarily seen in Orientals. Clinically, one can find acral punctate and reticulate hyperpigmentation but with a tendency to coalesce and form stellate patches. There is interspersed leukoderma of the face, upper trunk, flexor extremities and palms. This disease is composed of 2 main findings : 1. Ephelids on the face and 2. Pigmentation of the hands and feet¹⁰. There is neither atrophy on the pigmentary lesions nor palmar pits and breaks in the epidermal ridge patterns on the palms. In most cases, the remaining portion of the extremities, upper chest, shoulder, scapular region and buttocks are not intact. There are : 1. changes in the dorsa of hands and feet; 2. multi-colored, dirty pigmentation; 3. diffuse pigmentation with black colored small pigmentation, and 4. only small sized areas of dirty pigmentation. These localized pigmentations also appear symmetrically. Pigmentation progresses until adulthood and thereafter remains stable. Severe cases may appear to be dyschromic, causing diagnostic difficulty^{5,8,11}.

There are several reticulate hyperpigmentary diseases that show similar clinical findings (Table 1). RAPK is characterized by distal, reticulated, hyperpigmented, slightly atrophic, polygonal macules, extending proximally. Palmar pits and breaks in the epidermal ridge patterns are characteristically present on the palms^{3,4,7}. In contrast, Dohi shows reticulate hyperpigmentation and interspersed-depigmented macules with no atrophic skin lesions^{8,10}. DDD is characterized by flexural involvement and the delayed onset with the presence of small comedo-like hyperkeratotic follicular lesions^{5,6}. Acromelanosis progressiva with the pictures of acral pigmentation has to be considered in differentiation. Unlike Dohi, the pigmentation is diffuse rather than reticulated and spreads rapidly to the proximal area¹². The family history of our patients revealed that his sister and cousin had similar types of pigmentation, whereas his parents, uncle and aunt did not. This could be explained as either due to spontaneous mutation or incomplete penetrance⁵. Gertler¹¹ showed that histological findings of leukodermic areas reveal a decreased number of melanocytes, whereas hyperpigmented areas reveal increased melanization. Our case showed similar epidermal findings as compared to previous re-

ports. However, there were densely aggregated dermal melanocytes or melanophages in the upper portion of the dermis. This finding has not been previously reported. Generally melanocytes have finer melanin granules and possess dendritic processes as compared to melanophages on H and E stains. However, these findings are subjective, thus we performed immunohistochemical stains to differentiate the melanocytes and melanophages. Both the S-100 stain and HMB-45 stain were positive. Thus we thought that melanocytes were present but further studies are required to confirm this.

In several cases, good responses to 20% azelaic acid ointment were reported to treat RAPK^{13,14}, but the main problem in our patient were hypomelanotic macules interspersed between the hyperpigmentation. The Q-switched Alexandrite laser was initially developed for treatment of black skin tattoos. I also shows good results on blue and green lesions¹⁵⁻¹⁷, so that we applied it on Ota's nevus with favorable results and on epidermal type of melasma with excellent results. In respect to these results in Ota's nevus and melasma and in order not to affect the hypopigmented areas, we tried the Q-switched Alexandrite laser therapy for selective discoloration of hyperpigmented macules on Dohi which shows histological findings of epidermal and dermal pigmentation.

In order to determine the most appropriate intensity for treatment, sequential use of intensities of 4, 6 and 8 watts were applied to several lesions. As treatment with 8 watts showed the best results, the intensity of 8 watts was applied for treatment. Little difference was observed between lesions treated once or more which does not reflect the results of the Q-switched Alexandrite laser therapy, formerly reported¹⁷⁻¹⁹. Immediately after treatment, the hyperpigmented macules discolored and seemed to look like hypopigmented areas, but new pigmentary islands from perifollicular areas developed after 3 to 4 months and turned to the original state again. Repigmentation mostly started around the hair follicles. This can be explained by the fact that melanocytes of hair follicles are positioned deep in the dermis which are relatively unaffected by the Q-switched Alexandrite laser. Because repigmentation occurred on both hands, we can infer that the Q-switched Alexandrite laser acted selectively on melanin without influencing melanocytes.

We can conclude that the Q-switched Alexandrite laser treatment was not satisfactory for treating acropigmentation *symmetrica* of Dohi.

REFERENCES

1. Fulk CS : Primary disorders of hyperpigmentation. *J Am Acad Dermatol* 10:1-16,1984.
2. Kitamura K, Akamatsu S : Pigmentary disorder. *Rinsho Hifu-Hitsunyo* 8:201-204, 1943(cited from ref.3)
3. Mizoguchi M, Kukita A : Behavior of melanocytes in reticulate acropigmentation of Kitamura. *Arch Dermatol* 121:659-661,1983.
4. Lee KH, Chang KH, Chun SI, Koh CJ : A case of reticulate acropigmentation of Kitamura. *Kor J Dermatol* 21:321-323,1983.
5. Dhar S, Kanwar AJ, Jebraili R, Dawn G, Das A : Spectrum of reticulate flexural and acral pigmentary disorders in Northern India. *J Dermatol* 21:598-603,1994.
6. Wilson Jones E, Grice K : Reticulate pigmented anomaly of the flexures : Dowling Degos disease, a new genodermatosis. *Arch Dermatol* 114: 1150-1157, 1978
7. Griffiths WAD : Reticulate acropigmentation of Kitamura. *Br J Dermatol* 95: 437-443, 1976
8. Kim N, Park S, Youn J, Lim S : Dyschromatosis *symmetrica hereditaria* affecting in two families. *Kor J Dermatol* 18: 585-589, 1980
9. Kim Y : Three cases of dyschromatosis *symmetrica hereditaria* - Histological studies and review of literatures. *Kor J Dermatol* 6:517-523, 1969
10. Komaya G : Symetrische Pigmentanomalie der Extremitaeten. *Archiv fuer Dermatologie und Syphilis* 147:389-393,1924.
11. Gertler W : Akropigmentation *symmetrica* Dohi mit angeborenen Fundisveraenderungen bei Mutter und Tochter. *Dermatol Wochenschr.* 23:534-535, 1952,(cited from ref.1)
12. Lee C, Lee Y : A case of acromelanosis *progressiva*. *Kor J Dermatol* 13: 49-52, 1975
13. Kameyama K, Morita M, Sugaya K, Nishiyama S, Hearing VJ : Treatment of reticulate acropigmentation of Kitamura with azelaic acid. *J Am Acad Dermatol* 26:817-820,1992.
14. Gatti S, Nini G : Treatment of reticulate acropigmentation of Kitamura with azelaic acid. *J Am Acad Dermatol* 27:666-667,1993.
15. Fitzpatrick RE, Goldman MP, Ruiz-Esparza J : Use of the alexandrite laser (755nm, 100nsec) for tattoo pigment removal in an animal model. *J Am Acad Dermatol* 28: 745-750, 1993
16. Dozier SE, Diven DG, Jones D et al : The Q-switched alexandrite laser effects on tattoos in guinea pigs and harvested human skin. *Dermatol Surg* 21: 237-240. 1995
17. Fitzpatrick RE, Goldman MP : Tattoo removal using the alexandrite laser. *Arch Dermatol* 130: 1508-1514, 1994
18. Alater TS : Q-switched alexandrite laser treatment(755nm) of professional and amateur tattoos. *J Am Acad Dermatol* 33: 69-73, 1995
19. Stafford TJ, Lizek R, Boll J, Tan OT : Removal of colored tattoos with the Q-switched alexandrite laser. *Plast Recon Surg* 95: 313-320, 1995