

Pachydermoperiostosis Accompanied by Hypertrophic Gastritis

Seok Jong Lee, M.D., Sang Lip Chung, M.D., Jae Bok Jun, M.D.,
Do Won Kim, M.D., Bo Wan Kim, M.D.*

*Department of Dermatology and Internal Medicine**
Kyungpook National University School of Medicine, Taegu, Korea

We report a patient with pachydermoperiostosis accompanied by hypertrophic gastritis. A 26-year-old man showed deep folds and furrows of the face and scalp, and terminal spade-like expansion of fingers and toes. Physical examination revealed no abnormalities except a grotesque appearance. Results of routine laboratory tests were unremarkable. Mild periosteal reactoins of both femurs and humeri were noted on long bone series, and hypertrophic gastritis on fibroscopic examination drew our attention.

The relationship between pachydermoperiostosis and hypertrophic gastritis is uncertain. However it is probable that hypertrophic gastritis may be the endodermal counterpart of the ectodermal manifestations of pachydermoperiostosis. (*Ann Dermatol* 6:(2) 204-207, 1994)

Key Words: Hypertrophic gastritis, Pachydermoperiostosis

Pachydermoperiostosis (PDP), which was described by Touraine, Solente and Gole¹, is a rare clinical syndrome characterized by folds and furrows in the skin of the face and scalp, clubbing of terminal phalanges and cylindrical thickening of long bones²⁻⁴. Although PDP resembles pulmonary hypertrophic osteoarthropathy, clinically no causative factors such as pulmonary, cardiac or hepatic abnormalities causing osteoarthropathy are present⁵.

Various other abnormalities such as anemia⁶, excessive sweating, sebaceous hyperplasia and greasy skin are also found. Very rarely, gastric hypertrophy has been described as accompanying this condition^{6,8}. In Korean dermatologic literature, only one case on the PDP without gastric pathology has been reported⁹.

REPORT OF A CASE

A 26-year-old man visited our department because of deep folds and furrows of the face and scalp and terminal expansion of the fingers and toes. He had complained of thickening and deep folds of the scalp since middle-school age. Eight years ago deepening of folds began to involve the face, making him look like "a worried and angry person". Twenty days before his visit general weakness, fatigability and slight swelling of both hands developed.

Physical examination revealed thickening of the skin and accentuation of creases on the face and scalp (Fig. 1, 2) and clubbing of the fingers and toes (Fig. 3). The facial skin was oily and coarsened.

Routine laboratory findings such as complete blood count, urinalysis, stool examination, renal function tests and VDRL were within normal limits except hyperbilirubinemia on liver function tests and possible left ventricular hypertrophy on electrocardiogram. In pulmonary function tests, the result of arterial blood gas analysis was within the normal range whereas diffusing capacity was

Received August 12, 1993.

Accepted for publication February 25, 1994.

Reprint request to: Sang Lip Chung, M.D., Department of Dermatology Kyungpook National University School of Medicine, 52, Samduk 2-ka, Chung-Ku, Taegu, 700-412, Korea.

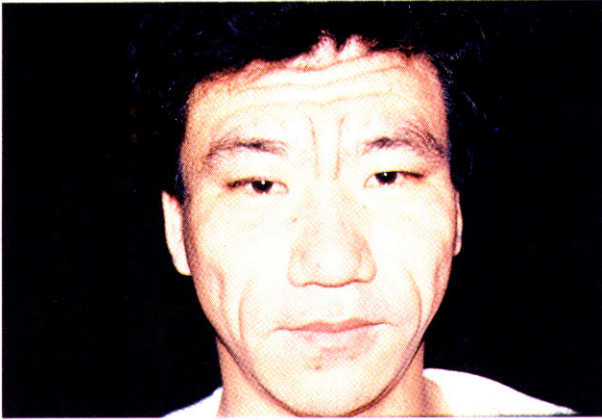

Fig. 1. Deep folds and furrows of the face.

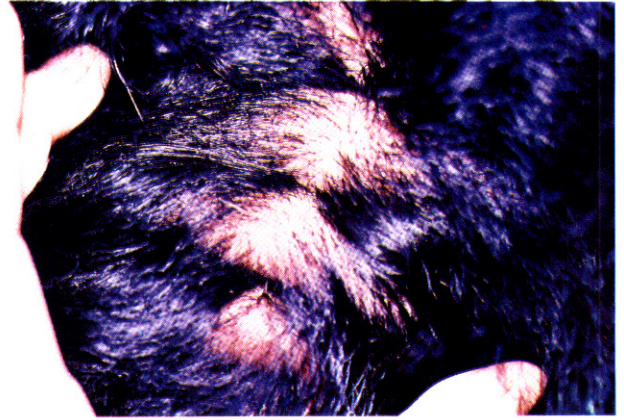


Fig. 2. Prominent folds of the scalp.

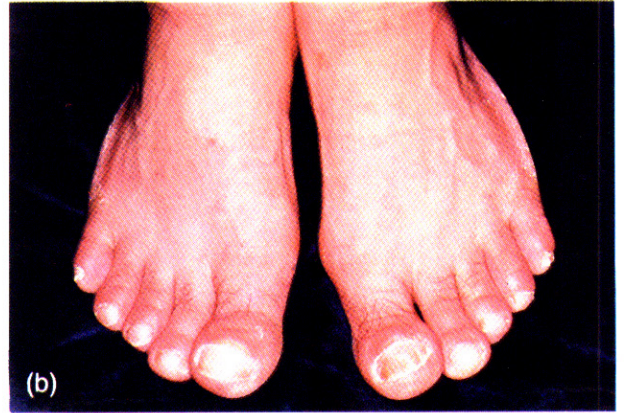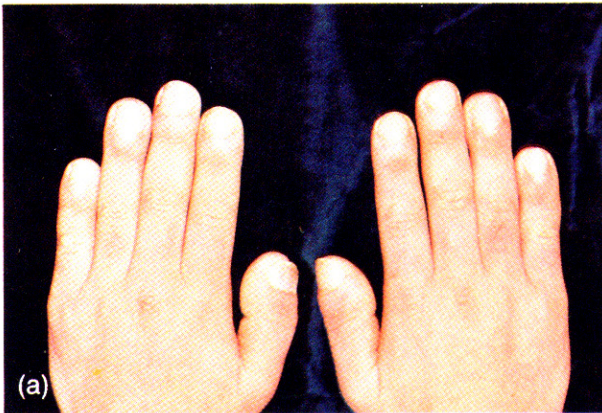


Fig. 3. Distal clubbing of the phalanges of the fingers(a) and toes(b).

decreased. On alkaline phosphatase isoenzyme study, the liver and bone compartments of alkaline phosphatase were increased markedly and trace, respectively.

The long bone series on roentgenographic examinations revealed mild periosteal reaction of both femurs and humeri which resulted in periosteal thickening and new bone formation along the shafts, especially at their distal ends (Fig. 4).

There were detected pleural thickening of the right lung and mild emphysematous change on a simple chest film and calcification on chest CT without definite mass or nodal enlargement. There were marked thickening of the gastric mucosal folds on UGI series (Fig. 5) and hypertrophic gastritis on fibroscopic examination. Other gastrointestinal disorders such as peptic ulcer, protein losing enteropathy or hypoproteinemia were not found. Unfortunately, gastric physiologic tests were not performed and other family mem-

bers of the patient refused to be studied. Histopathologic examination of his facial skin showed thickening and mild edema of the dermis which exhibited a positive reaction to alcian blue stain at pH 2.5, proliferation of the sebaceous glands, hypertrophied hair follicles and proliferation of the collagen fibers.

Differential diagnosis included pulmonary hypertrophic osteoarthropathy and acromegaly. Symptomatic management was done with commonly-used drugs such as aspirin, nonsteroidal antiinflammatory agent and other analgesics.

DISCUSSION

PDP has been known to affect the tissues of the ectodermal and mesodermal origin such as skin, soft tissue and bone. Though the etiology of PDP is unclear, genetic developmental defect or endocrinologic disorder¹⁰ has been implicated. Neuro-

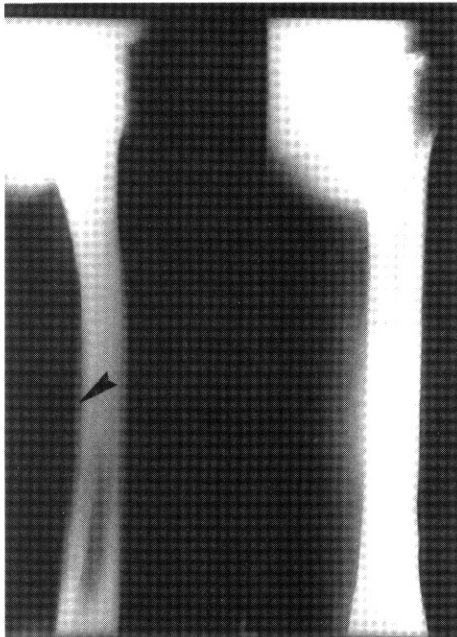


Fig. 4. Mild periosteal reaction (arrowhead) resulting in thickened cortical bone along the shaft of humerus.

circulatory abnormalities have also been involved, suggested by its hyperhidrosis⁵ and alteration in peripheral blood flow¹¹, disappearance of the skin changes after vagotomy or ligation of the pulmonary artery in a patient with hypertrophic pulmonary osteoarthropathy¹².

In our patient, in addition to the typical clinical appearance, incidentally taken UGI series and fibroscopic examination revealed gastric hypertrophy although he had no accompanying symptoms or history of gastrointestinal disturbances such as dyspepsia and hunger soreness. There was a report by Lam *et al*⁷ on two brothers with PDP suffering from hypertrophic gastritis (Menetrier's disease) and peptic ulcer. Their father and one paternal uncle had complained of ulcer dyspepsia in their personal history. So the authors supposed that hypertrophic gastritis might be suspected as an endodermal counterpart of ectodermal manifestations of PDP if the pathophysiology of the skin changes of PDP was the inside fact of those of hypertrophic gastric mucosa but the correlation between these two conditions has not been identified in the literature since then. This family study suggested that PDP and hypertrophic gastritis may be genetically related, but it was not confirmed. Unfortunately, we could not clarify the detailed aspects of hypertrophic gastritis in PDP because

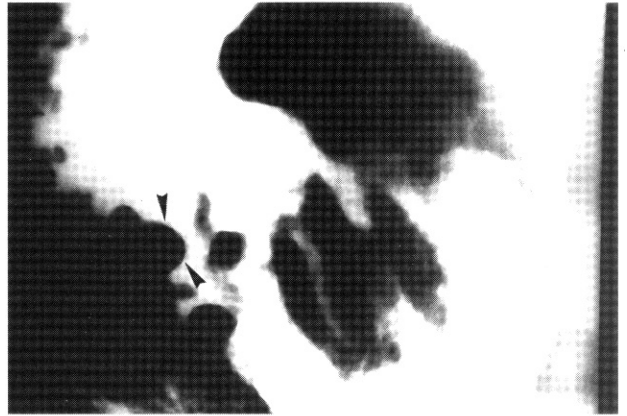

Fig. 5. Marked thickening of gastric mucosal folds (between arrowheads) on UGI series.

we were unable to study other family members.

REFERENCES

1. Touraine A, Solette G, Gole L: Un syndrome osteodermapathique: La Pachydermie plicaturee avec pachyperiostose, des extremités. *Press Med* 43:1820-1824, 1935. Cited from ref. 5.
2. Hambrick GW, Carter DM: Pachydermoperiostosis. *Arch Dermatol* 94:594-599, 1966.
3. Bhate DV, Pizarro AJ, Greenfield GB: Idiopathic hypertrophic osteoarthropathy without pachyderma. *Radiology* 129:379-383, 1978.
4. Vogl A, Goldfisher S: Pachydermoperiostosis: primary or idiopathic hypertrophic osteoarthropathy. *Am J Med* 33:166-170, 1962.
5. Moschella SL, Hurley HJ: *Dermatology*. 3rd ed, WB Saunders Co, Philadelphia, 1992, pp1362-1364.
6. Venencie PY, Boffa GA, Delmas PD, *et al*: Pachydermoperiostosis with gastric hypertrophy, anemia, and increased serum bone Gla-protein level. *Arch Dermatol* 124:1831-1834, 1988.
7. Lam SK, Hui WKK, Ho J, Wong KP, Rotter JJ, Samloff IM: Pachydermoperiostosis, Hypertrophic gastropathy, and peptic ulcer. *Gastroenterology* 84:834-839, 1983.
8. Neiman HL, Gompels BM, Martel W: Pachydermoperiostosis with bone marrow failure and gross extramedullary hematopoiesis. *Radiology* 110:553-554, 1974.
9. Cho SH, Kim SK, Yang, Kim JT: A case of pachydermoperiostosis. *Kor J Dermatol* 19:647-650, 1981.
10. Shawarby K, Ibrahim MS: Pachydermoperiostosis:

a review of literature and report on four cases. Br J Dermatol 17:763-766,1962.

11. Rimoin DL: Pachydermoperiostosis (idiopathic clubbing and periostosis) genetic and physiologic considerations. N Engl J Med 272:923-931,1965.
12. Flavell G: Reversal of pulmonary hypertrophic osteoarthropathy by vagotomy. Lancet 1:260, 1956. Cited from ref. 2.