

A Case of Widespread Skin Tuberculosis Following BCG Vaccination

Heung Ryeol Choi, M.D., Chang Kwun Hong, M.D.
and Byung In Ro, M.D.

*Department of Dermatology, College of Medicine,
Chung Ang University, Seoul, Korea*

Dermatologic complications attributed to BCG vaccination are rarely seen. We report a case of widespread skin tuberculosis following BCG vaccination.

A 28-year old female visited our outpatient clinic because of erythematous plaques and atrophic patches on the upper chest, both axillae, neck and frontal scalp. Her skin lesion had developed on the right shoulder after BCG vaccination 18 years ago, and gradually extended. She was treated under the impression of psoriasis at private clinic for recent 2 years, but her skin lesions were aggravated. Tuberculin skin test revealed positive reaction. Histopathologic examinations from scalp, posterior neck and axilla revealed granulomatous structures composed of giant cells, epithelioid cells and lymphoid cells in the dermis, but tubercle bacilli were not found in AFB stain. After 9 months of treatment with antituberculous medications such as streptomycin, isoniazid, rifampin and ethambutol, her skin lesions were almost healed.

(*Ann Dermatol* 4:(2) 124-127, 1992)

Key Words: Skin tuberculosis, BCG vaccination

The frequency of skin tuberculosis in Korea was 0.1-0.16% of outpatients of the department of dermatology according to some reports^{1,2}, and that in other countries is 0.4%³ or less than 0.5%⁴. The incidence of skin tuberculosis tends to be declined over the World⁵.

Bacillus Calmette Guérin (BCG), which is a living attenuated vaccine, has been used for vaccination of pulmonary tuberculosis. Complications after BCG vaccination represents about 1% in Korea⁶. Lupus vulgaris or lupus-like skin tuberculosis following BCG vaccination are rare. Since the first case of inoculation tuberculosis resembling lupus vulgaris was reported by Lomholt⁷ in 1946, less than 60 cases have been reported⁸. In Korea three cases of lupus vulgaris or lupus-like

skin tuberculosis following BCG vaccination similar to our case were reported by Suh et al⁹, Goo et al¹⁰ and Lew et al¹¹.

We report a case of widespread skin tuberculosis following BCG vaccination.

REPORT OF A CASE

A 28-year-old female visited our out-patient clinic in May 22, 1990 with erythematous plaques and atrophic patches on the upper chest, both axillae, neck and frontal scalp. An erythematous plaque developed on the right shoulder after BCG vaccination 18 years ago, and gradually extended. Her skin lesions were spread to upper chest, both axillae and neck 6 years ago. In spite of the treatment with ultraviolet radiation and topical application of corticosteroid under the impression of psoriasis at private clinic since 2 years ago, her skin lesions have been aggravated. Past and family history were not contributory.

Physical examination revealed striae distensae due to topical corticosteroid therapy and erythematous to slightly brownish patches with

Received March 4, 1991

Accepted for publication April 15, 1992

Reprint request to: Heung Ryeol Choi, M.D., Department of Dermatology, College of Medicine, Chung Ang University, Seoul, Korea.

This paper was presented at the 7th Korea-Japan Joint Meeting of Dermatology on October 19, 1991.

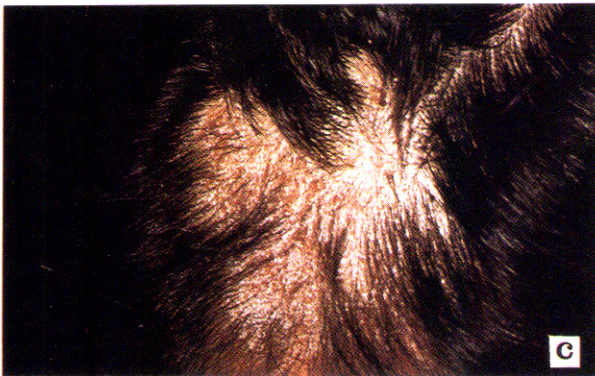
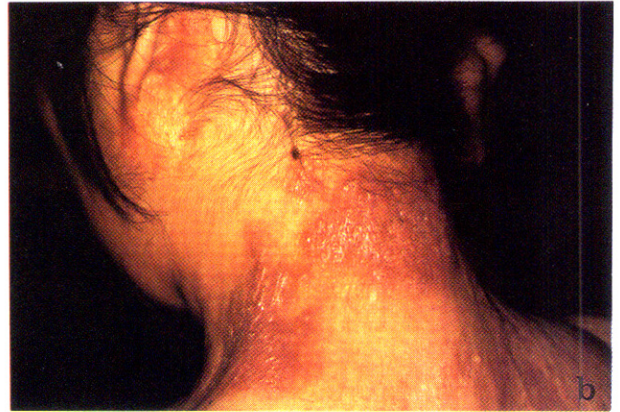
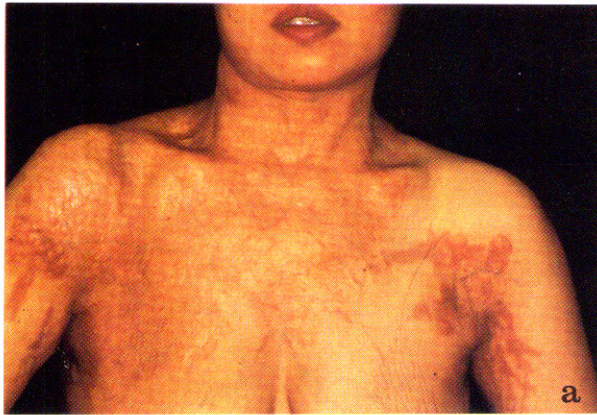Fig. 1. (a) Erythematous to slightly brownish patches with some atrophy on the upper chest, both axillae and neck.
(b) Erythematous scaly plaques on the posterior neck.
(c) Erythematous patches covered with whitish scales on the frontal scalp.

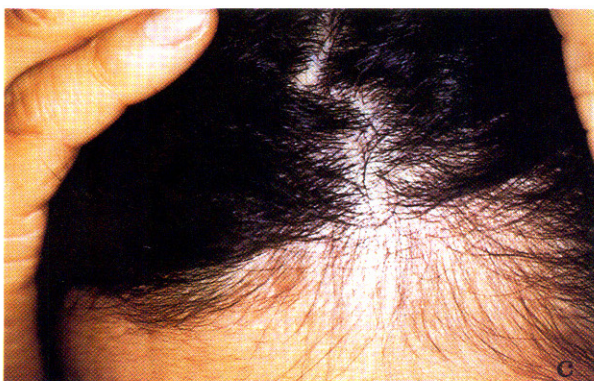
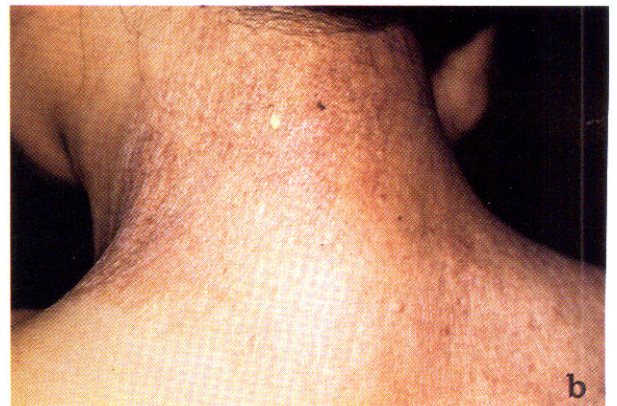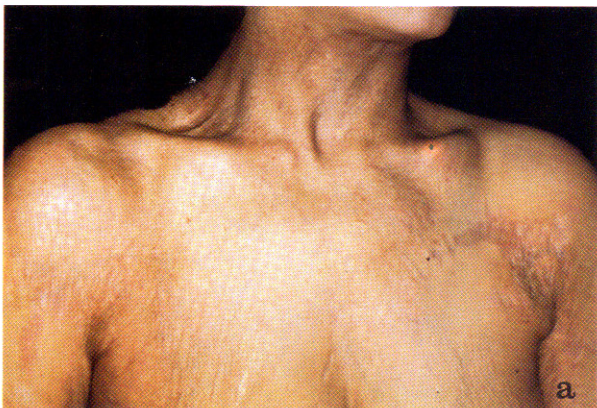


Fig. 3. Markedly improved skin lesions on the upper chest, both axillae (a), neck (b) and frontal scalp (c) after 9 months of treatment.

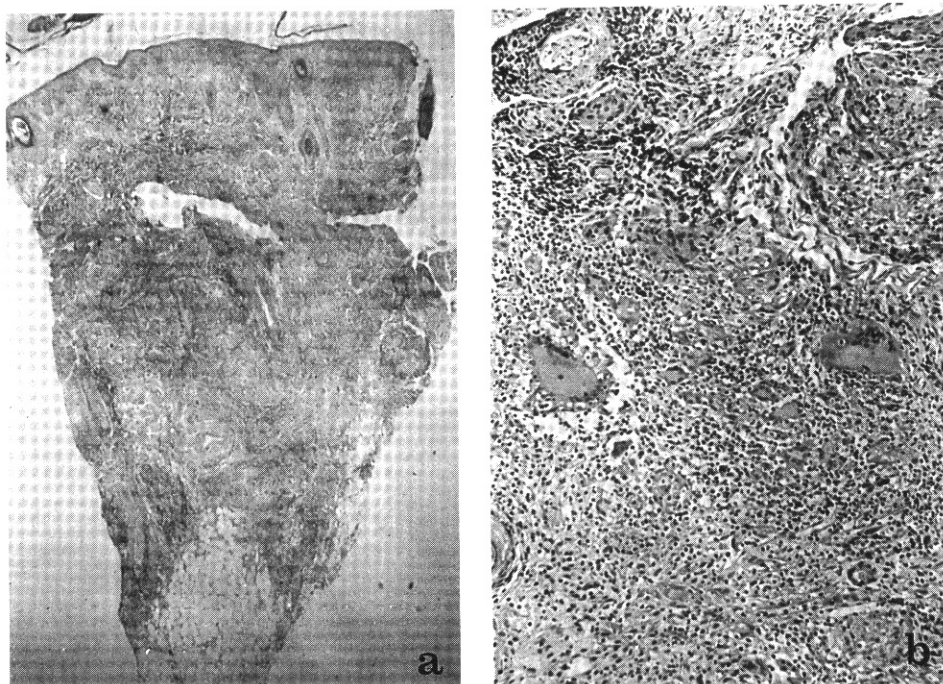


Fig. 2. (a) Biopsy specimen taken from a plaque of the posterior neck showing tuberculoid structures and moderate inflammatory cell infiltrates in the dermis (H&E stain, $\times 40$).
(b) Tuberculoid structure containing giant cells, epithelioid cells and lymphoid cells (H&E stain, $\times 100$).

some atrophy on the upper chest and both axillae. And erythematous scaly plaques were observed on the neck, and erythematous scaly patches similar to psoriasis on the frontal scalp (Fig. 1). They were characterized by apple jelly color when blanched by diascopic pressure.

On the laboratory examinations, complete blood count, urinalysis, liver function test, VDRL and chest roentgenogram were within normal limit or non-reactive, and tuberculin skin test with 5 units of purified protein derivatives revealed a positive reaction with vesicles and 2×2 cm sized induration.

Histopathologic findings of the biopsies from scalp, posterior neck and axilla revealed parakeratosis and acanthosis in the epidermis, and granulomatous structures composed of giant cells, epithelioid cells and lymphoid cells without caseation necrosis, and moderate inflammatory cell infiltrates in the dermis (Fig. 2). Tubercle bacilli were not found on the acid fast bacilli stain.

Under the diagnosis of skin tuberculosis, we treated her with streptomycin 5g per week for 1 month, and isoniazid 400mg, rifampin 450mg and ethambutol 800mg daily for 9 months. After 9

months of treatment, her skin lesions were markedly improved (Fig. 3). Until now we are following her up and can not find recurrence.

DISCUSSION

Skin tuberculosis is classified into true cutaneous tuberculosis and tuberculids. True cutaneous tuberculosis include primary tuberculosis such as tuberculous chancre and miliary tuberculosis, and secondary tuberculosis such as lupus vulgaris, tuberculosis verrucosa cutis, scrofuloderma, tuberculous gumma and tuberculosis cutis orificialis⁵. Lupus vulgaris has slowly progressed course, and may be disseminated rarely in the patient with decreased immunity⁵. Lupus vulgaris is most frequently occurred on the head and neck, and rarely on the trunk⁵. We think that the skin lesions in our case are compatible with lupus vulgaris-like skin tuberculosis by virtue of clinical and histopathologic findings; developing site, namely head and neck, strongly positive tuberculin test, and lack of acid fast bacilli on histologic examination.

Complications after BCG vaccination are rare-

ly seen. These include nonspecific lesions such as keloid, granuloma, eczema, urticaria, epithelial cyst, erythema nodosum, erythema multiforme and generalized papular or hemorrhagic rashes, and specific lesions such as lupus vulgaris, Koch's phenomenon, local subcutaneous abscess, regional adenitis, scrofuloderma, generalized tuberculid-like eruption, generalized adenitis, osteitis and tuberculous foci in distant organ^{4, 12}.

Less than 60 cases of lupus vulgaris or lupus-like skin tuberculosis following BCG vaccination have been reported up to present in the world⁸, and 3 cases in Korea⁹⁻¹¹.

The factors that might be responsible for a tuberculous lesion developed following BCG vaccination are inherent resistance of the individual, virulence of the BCG organism, amount of inoculum and technique of inoculation¹³. In our case there were indirect evidences that her cellular immune surveillance system was intact in consideration of no apparent extension to lymph nodes or distant sites, strongly positive reaction to purified protein derivatives, and tuberculoid structures and lack of organisms on histologic examination. Therefore we think that another factors were associated with the development of her lesions.

The mode of cutaneous infection or spread of skin tuberculosis may be exogenous (for example, autoinoculation) or endogenous (for example, extension of an underlying diseased organ) or by lymphatic or hematogenous spread⁵. We think that the route of spread in our case is maybe direct local extension or lymphatic spread from the primary inoculation site, and recent rapidly wide spread in her skin lesions is maybe due to longstanding topical corticosteroid therapy at private clinic in spite of relatively intact immunity.

Differential diagnosis of skin tuberculosis includes sarcoidosis, tertiary syphilis, discoid lupus erythematosus, leprosy, psoriasis and other deep fungal infection⁴.

Antituberculous chemotherapy should consist of at least two drugs and should be continued at least for 12 months⁴. But short course

chemotherapy composed of streptomycin plus isoniazid plus rifampin or pyrazinamide for 6 to 9 months has shown promising results¹⁴. The drugs currently employed in chemotherapy of tuberculosis are rifampin, pyrazinamide, isoniazid, streptomycin, ethambutol and thiacetazone¹⁵. We treated her with combined antituberculous medications composed of streptomycin, isoniazid, rifampin and ethambutol for 9 months, and thereafter her skin lesions were almost healed.

REFERENCES

1. Lee YB, Cho BK, Houh W et al: *Clinical and histopathological study on skin tuberculosis during 5 years (1970-1974)*. *Kor J Dermatol* 13:103-108, 1975.
2. Kwon KS, Chung TA: *A clinical study on skin tuberculosis*. *Kor J Dermatol* 15:181-187, 1977.
3. Wong KO, Lee KP, Chiu SF: *Tuberculosis of the skin in Hong Kong (A review of 160 cases)*. *Br J Dermatol* 80:424-429, 1968.
4. Wolff K, Tappeiner G: *Mycobacterial diseases*. In *Dermatology in General Medicine*. Fitzpatrick TB, Eisen AZ, Wolff K et al (eds), 3rd ed, McGraw-Hill Book Co, New York, 1987, pp2152-2170.
5. Moschella SL: *Diseases of the mononuclear phagocytic system*. In *Dermatology*. Moschella SL, Hurley HL (eds), 2nd ed, WB Saunder Co, Philadelphia, 1985, pp933-946.
6. Kim KH, Lee SJ, Lee K: *PPD conversion rate and complications according to the different time of BCG vaccination*. *J Kor Ped Assoc* 30:487-490, 1987.
7. Lomholt S: *Lupus vulgaris development in the reaction to a Calmette vaccination*. *Acta Tuberc Scand* 20:136, 1946. Cited from ref⁸.
8. Izumi AK, Matsunaga J: *BCG vaccine-induced lupus vulgaris*. *Arch Dermatol* 118:171-172, 1982.
9. Suh JH, Song JY: *A case of lupus vulgaris like reaction following BCG vaccination*. *Kor J Dermatol* 17:81-85, 1979.
10. Goo DW, Lee DS, Kim YH et al: *A case of lupus vulgaris following BCG vaccination*. *Kor J Dermatol* 27:217-221, 1989.
11. Lew W, Kim SM, Lee KH: *Unusual skin tuberculosis following BCG vaccination*. *Kor J Dermatol* 28:349-352, 1990.
12. Dostrovsky A, Sagher F: *Dermatological complications of BCG vaccination*. *Br J Dermatol* 75:181-192, 1963.
14. Fox W, Mitchinson DA: *Short course chemotherapy for pulmonary tuberculosis*. *Am Rev Respir Dis* 11:845-848, 1975.
15. Sbarbaro JA: *Tuberculosis*. *Med Clin North Am* 64:417-431, 1980.