

# Eruptive Neonatal Hemangiomatosis

## — Diffuse Type Treated with Oral Prednisolone —

Yong Seop Choi, M.D., Dong-Kun Kim, M.D., Hae Eul Lee, M.D.,\* Chul Lee, M.D.\*\*

*Departments of Dermatology and Pediatrics\*\*Yonsei University College of Medicine,  
Department of Dermatology, Cheil Hospital\*, Seoul, Korea*

Eruptive neonatal hemangiomatosis is an uncommon disorder, which is divided into two types according to the extent of involvement: Benign type with cutaneous hemangiomatosis only and diffuse type with widespread hemangiomas of skin and viscera. The organs commonly affected are the gastrointestinal tract, brain, liver and lung. The Diffuse type is often fatal.

We herein report a case of eruptive neonatal hemangiomatosis with cutaneous and hepatic involvement. The size of the hepatic arteriovenous malformation was markedly decreased after 2 months' therapy with oral prednisolone. (Ann Dermatol 4:(2) 108-112, 1992)

*Key Words:* Eruptive neonatal hemangiomatosis, Oral prednisolone therapy

Eruptive neonatal hemangiomatosis is an uncommon disorder characterized by multiple cutaneous hemangiomas of the 'strawberry' type accompanied by visceral hemangioma<sup>1</sup>. It is usually present at birth or appears shortly thereafter<sup>2</sup>. Eruptive neonatal hemangiomatosis may be divided into two types depending on the extent of involvement: Cutaneous only, or "benign neonatal hemangiomatosis", with a favorable prognosis; and multisystem involvement, or "diffuse neonatal hemangiomatosis", with a more guarded prognosis<sup>3</sup>. Holden and Alexander<sup>4</sup> defined the term, "diffuse neonatal hemangiomatosis" as follows: Onset in the neonatal period, three or more organs involved, and nonmalignancy of the hemangiomas. In diffuse neonatal hemangiomatosis, extensive visceral involvement is a poor prognostic sign with mortality reaching 95%<sup>5</sup>. Death is most often attributed to hemorrhage from hemangioma in upper respiratory or gastrointestinal tract, or to high-output congestive heart failure due to arteriovenous shunting in the liver and lungs. Therefore, early treatment such as systemic corticosteroid, digitali-

zation, and relief of arteriovenous shunt is necessary to improve the prognosis<sup>1, 6-9</sup>.

We report a patient with hemangiomas of skin and liver and with an arteriovenous malformation of the liver which responded to systemic corticosteroid. This child, now 6 months old, showed a decrease in number and size of cutaneous and mucosal hemangiomas along with marked decrease in size of arteriovenous malformation in the liver after 2 months of prednisolone therapy (1 mg/kg/day).

### REPORT OF A CASE

A 3-week-old boy visited our department for the evaluation of rice- to pea-sized red papules on trunk, extremities and oral cavity present since birth. He was born to a 30-year-old, gravida 4, para 2 mother. Delivery was vaginal at full-term and the birth weight was 4,950g. The immediate newborn condition was good, but the skin lesions were increasing in number and size during post-natal period. No other family members had significant disease.

Physical examination revealed a restless, well-nourished, 3-week-old boy. Cardiac auscultation disclosed a soft systolic murmur, grade 1-2, over the apex. Vital signs including body temperature, heart rate, and respiration were within normal limits. The skin lesions were variable in size: Di-

Received January 10, 1992

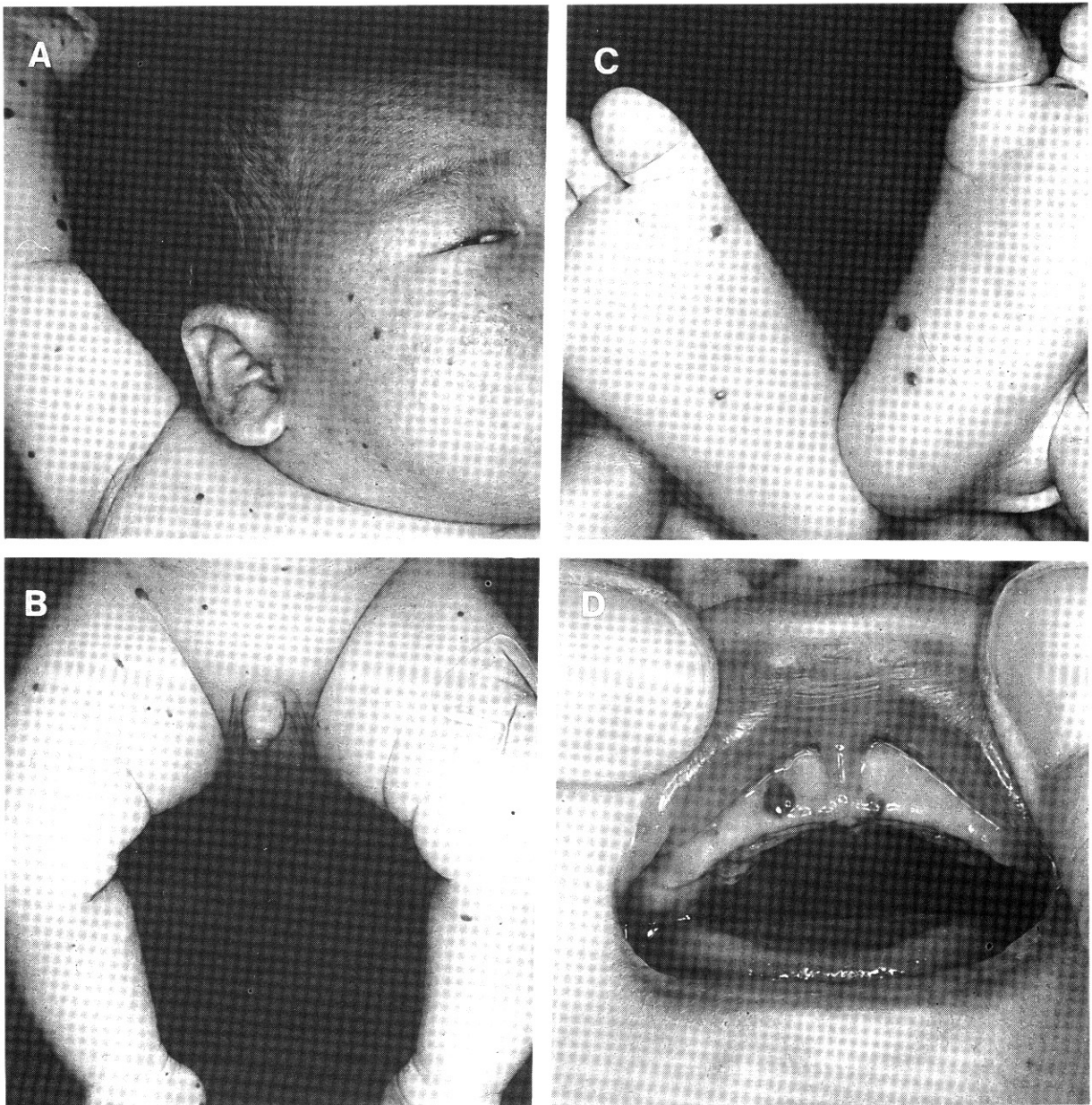
Accepted for publication January 29, 1992

**Reprint request to:** Dong-Kun Kim, M.D., Department of Dermatology, Yongdong Severance Hospital, Yonsei University College of Medicine C.P.O.Box 1217, Seoul, Korea.

imeters of most of the lesions were 2 to 5mm and some were about 2cm. The lesions were distributed widely over the extremities including palms, soles, trunk, gingiva, and hard palate (Fig. 1).

The following laboratory findings were normal or negative: Complete blood count, platelet count, urinalysis, VDRL, serum electrolytes, stool examination, and prothrombin time. An echocardiography showed no vascular lesions. Abdominal sonogram showed abnormally dilated vascular fill-

ing in the anterior portion of right lobe of liver with tiny feeding vessels suggestive of an arteriovenous malformation. Mixed echoic lesions were observed at the mid-and posterior portion of right lobe (Fig. 3). Magnetic resonance image of the abdomen revealed dilated venous vascular structures suggesting arteriovenous malformations in the right and left lobe of liver and cavernous hemangioma with central scar involving the mid-portion of the right lobe. Magnetic resonance image of the brain showed no parenchymal ab-



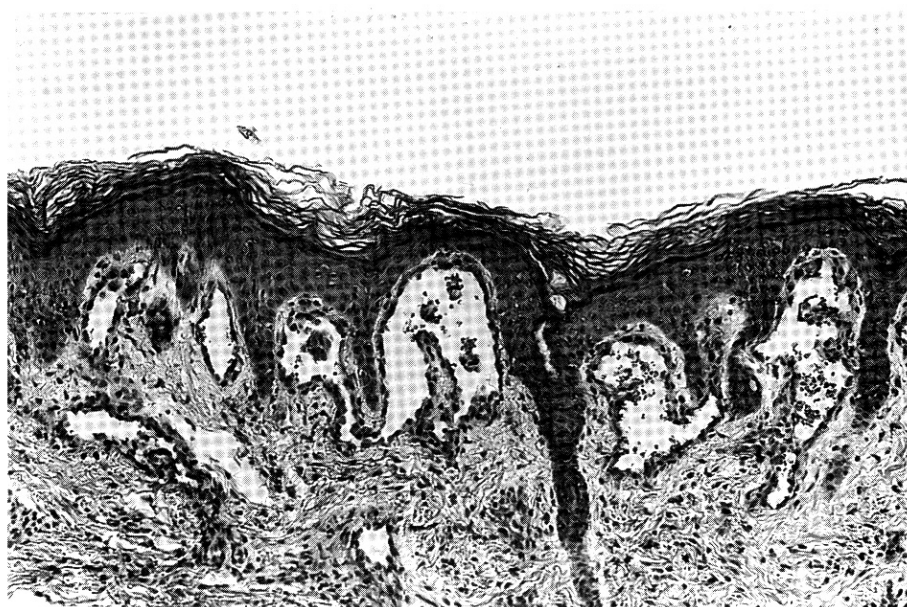
**Fig. 1.** Strawberry hemangiomas are noted on face, extremities, trunk (A, B), soles (C) and gingiva (D).

normalities, but high signal intensity along the subcutaneous fat was observed above the calvarium, suggestive of a cephalhematoma.

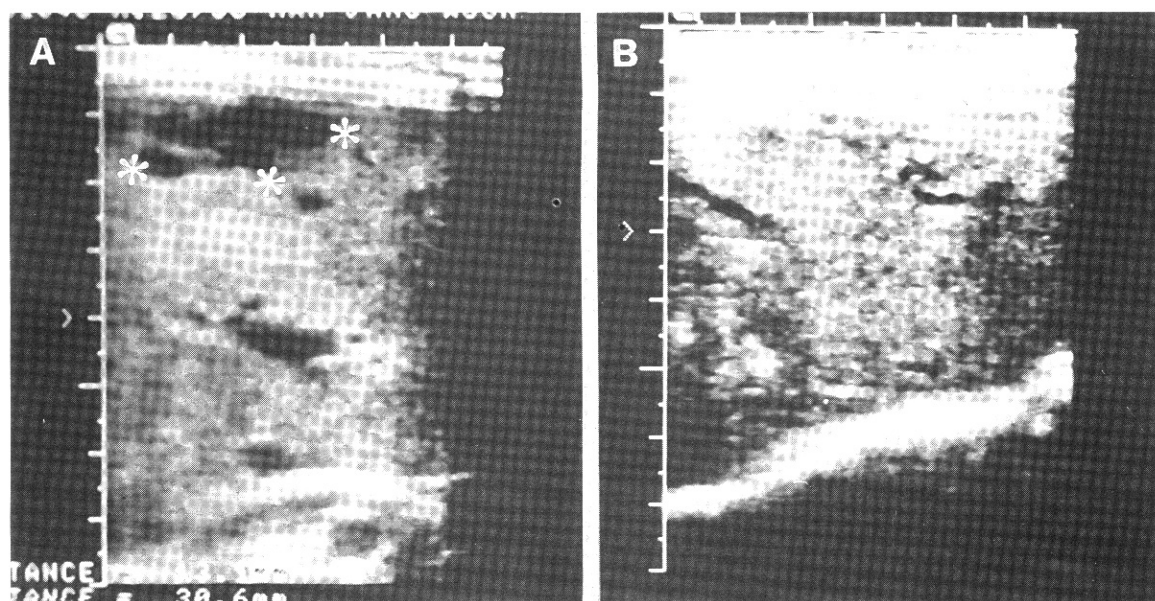
A skin biopsy was obtained from a lesion on the right lower extremity. Hematoxylin-eosin stain showed numerous dilated tortuous vessels in the upper dermis lined by normal-appearing en-

dothelial cells; a histopathologic pattern compatible with capillary hemangioma (Fig. 2).

Treatment with oral corticosteroid, prednisolone (1mg/kg/day), was initiated. After 1 month of treatment, the size of the cutaneous hemangioma was partly decreased and the hemangioma of oral mucosa and skin disappeared. After 2



**Fig. 2.** Numerous dilated tortuous vessels are seen in upper dermis lined by normal appearing endothelial cells (H&E,  $\times 100$ ).



**Fig. 3.** By the ultrasonographic examination on initial visit (A), the arteriovenous malformation (\*) and cavernous hemangioma are observed in the liver. After 2 months of treatment with oral prednisolone (B), the size of arteriovenous malformation is markedly decreased.

months, repeated abdominal ultrasonography revealed a marked decrease in the size of arteriovenous malformation. However, the hemangioma of liver was changed in size (Fig. 3).

## DISCUSSION

Cutaneous hemangiomas are present at birth or appear shortly thereafter in approximately 10% of all neonates<sup>10</sup>. While the lesions are usually solitary and regress spontaneously, patients occasionally may have diffuse, eruptive involvement of skin and viscera.

Eruptive neonatal hemangiomatosis usually presents as multiple strawberry hemangiomas of skin with numerous red to purple hemangiomas ranging in size from 2mm to 2cm diameter. The benign type of this disease does not involve mucous membranes or viscera, however, the diffuse type involves viscera and mucous membranes. The most common internal organs involved (in order) are the liver, brain<sup>11, 12</sup>, lungs, gastrointestinal tract, iris, retina, spleen, kidneys, mesentery<sup>3</sup>, heart and abdominal wall<sup>12</sup>. The more visceral involvements, the worse the prognosis. Holden and Alexander's criteria of diffuse neonatal hemangiomatosis<sup>4</sup> is as follows: 1) onset in the neonatal period, 2) three or more organs involved, 3) nonmalignancy of the hemangioma.

The lesions of benign neonatal hemangiomatosis rapidly increase in size and number, and begin to involute spontaneously within four months after their appearance.<sup>4, 5, 13, 14</sup> The major complications of the diffuse type are high output cardiac failure<sup>15</sup>, obstructive jaundice<sup>16</sup>, intestinal obstruction, portal hypertension, intraabdominal hemorrhage<sup>3</sup>, and platelet-trapping coagulopathy (Kasabach-Merritt's syndrome)<sup>4</sup>. High output cardiac failure is caused by arteriovenous shunting in the hepatic hemangioma. Rocchini et al<sup>9</sup> evaluated the hemodynamic abnormalities in five patients with hepatic hemangioendothelioma which showed increased cardiac output. Over 50% of the increased output was shunted through an arteriovenous malformation. Once complications are evident, the mortality rate is high, probably about 50%<sup>17</sup>. In a review of patients with diffuse neonatal hemangiomatosis, the mean survival age was 2<sup>3</sup>/<sub>4</sub> months and the age range at the time of

death was 1 day to 41 months<sup>3</sup>.

Our case was classified as diffuse type of eruptive neonatal hemangiomatosis because of the involvement of oral mucosa and liver though it does not fulfill all of the criteria of Holden and Alexander<sup>4</sup>. Cavernous hemangioma and arteriovenous malformation of the liver can possibly cause life-threatening complications such as heart failure or bleeding diathesis. Therefore, this patient was treated with oral prednisolone.

Many treatment modalities were proposed to reduce the mortality of the diffuse type. Systemic corticosteroid, irradiation<sup>8</sup>, and ligation or embolization of feeding vessels<sup>6</sup> are commonly used.

Treatment with systemic corticosteroid was proposed for cutaneous hemangiomas, however, only about 30% of all types responded<sup>18</sup>. Many cases of eruptive neonatal hemangiomatosis were reported which responded successfully to corticosteroid<sup>1, 7, 9, 19</sup>. Clinically it has been observed that high dose corticosteroid has inhibitory effects and that low dose has stimulating effects on the growth of hemangioma<sup>18</sup>. Also, immature and rapidly proliferating blood vessels are more sensitive to steroid<sup>4, 7, 19</sup>.

The mechanism of action of corticosteroids on hemangiomas is poorly understood. Increased vascular sensitivity to vasoconstriction is one mechanism that has been suggested. Also, steroid-induced thrombosis and inhibition of fibrinolysis resulting in obliteration of vascular channels has been proposed<sup>7, 19, 20</sup>. Estrogen receptor assays performed on hemangiomas suggest another mechanism of steroid action. An apparent increase in the numbers of these receptors were shown in some cases. These findings may partially explain the regression of some hemangiomas with corticosteroid therapy- possibly due to blockage of the estrogen receptors by the corticosteroid moiety<sup>21</sup>.

Generally, the effect of corticosteroid on the growth of hemangioma occurs within 3 to 21 days of initiation of therapy (2-5 mg/kg/day<sup>1, 3, 7</sup>). Actual shrinkage of hemangioma may occur if treatment is continued for 30 to 90 days<sup>4</sup>.

We gave systemic corticosteroid, 1 mg/kg/day to our patient for 2 months. After 1 month of treatment, the hemangiomas of skin and mucous membranes disappeared or reduced in size. The

arteriovenous malformation showed marked reduction in size after 2 months of treatment. Thus, we propose that systemic corticosteroids have a significant prophylactic effect for the complications of diffuse neonatal hemangiomatosis. Further studies however, and long-term follow up evaluations will be necessary as our patient, now 6 months old, was treated only for 2 months, and the size of the carvenous hemangioma in the liver has not changed.

## REFERENCES

1. Clemmensen O: A case of multiple neonatal hemangiomatosis successfully treated by systemic corticosteroid. *Dermatologica* 159:495-499, 1979.
2. Atherton DJ, Rook A: Eruptive neonatal hemangiomatosis. In Rook A, Wilkinson DS, Edling FJG, et al(eds): *Textbook of Dermatology*, 4th ed, Blackwell Scientific Publications, London, 1986, pp 207-208.
3. Golitz LE, Rudikoff J, O'Meara OP: Diffuse neonatal hemangiomatosis. *Pediatr Dermatol* 3:145-152, 1986.
4. Holden KR, Alexander F: Diffuse neonatal hemangiomatosis. *Pediatrics* 46:411-421, 1970.
5. Stern JK, Wolf JE, Jarratt M: Benign neonatal hemangiomatosis. *J Am Acad Dermatol* 4:442-445, 1981.
6. Johnson DH, Vinson AM, Wirth FH, et al: Management of hepatic hemangioendotheliomas of infancy by transarterial embolization. *Pediatrics* 73:546-549, 1984.
7. Stillman AE, Hansen RO, Hallinan V, et al: Diffuse neonatal hemangiomatosis with severe gastrointestinal involvement. *Clin Pediatr* 22:589-591, 1983.
8. Edgerton MT: The treatment of hemangiomas: With special reference to the role of steroid therapy. *Ann Surg* 183:517-532, 1976.
9. Rocchini AP, Rosenthal A, Issenberg HJ, et al: Hepatic hemangioendothelioma: Hemodynamic observations and treatment. *Pediatrics* 57:131-135, 1976.
10. Jacobs AH, Walton RG: The incidence of birthmarks in neonate. *Pediatrics* 58:218-222, 1976.
11. Burke EC, Winkelmann RK, Strickland MK: Disseminated hemangiomatosis: The newborn with central nervous system involvement. *Am J Dis Child* 108:418-424, 1964.
12. Geller JD, Topper SF, Hashimoto K: Diffuse neonatal hemangiomatosis: A new constellation of findings. *J Am Acad Dermatol* 24:816-818, 1991.
13. Held JL, Haber RS, Silvers DN, et al: Benign neonatal hemangiomatosis: Review and description of a patient with unusually persistent lesions. *Pediatr Dermatol* 7:63-66, 1990.
14. Ha BS, Won YH, Chun IK, et al: A case of benign neonatal eruptive hemangiomatosis. *Kor J Dermatol* 26:960-966, 1988.
15. Keller L, Bluhm JF: Diffuse neonatal hemangiomatosis: A case with heart failure and thrombocytopenia. *Cutis* 23:295-297, 1979.
16. Wishnick MM: Multinodular hemangiomatosis with partial biliary obstruction. *J Pediatr* 92:960-962, 1978.
17. Kennedy CTC, Fleming P, Duncan A: Eruptive cutaneous and visceral neonatal hemangiomatosis. *Br J Dermatol* 123 (suppl): 83-85, 1990.
18. Sasaki GH, Pang CY, Wittliff JL: Pathogenesis and treatment of infant skin strawberry hemangiomas: Clinical and in vitro studies of hormonal effects. *Plast Reconstr Surg* 73:359-370, 1984.
19. Goldberg SJ, Fonkalsrud E: Successful treatment of hepatic hemangioma with corticosteroids. *JAMA* 208:2473-2474, 1969.
20. Esterly NB: Kasabach-Merritt syndrome in infants. *J Am Acad Dermatol* 8:504-513, 1983.
21. Barnhill RL, Wolf JE: Angiogenesis and the skin. *J Am Acad Dermatol* 16:1226-1242, 1987.