

Sweet's Syndrome with Myelodysplastic Syndrome Progressing to Acute Myelogenous Leukemia

Seung Ho Chang, M.D., Jai Il Youn, M.D., Yoo Shin Lee, M.D.

Department of Dermatology, College of Medicine, Seoul National University, Seoul, Korea.

Sweet's syndrome is an important cutaneous sign of underlying myeloproliferative disorder. The majority of cases have occurred with acute leukemia, primarily of the myelogenous type. We described a case of Sweet's syndrome in a patient with myelodysplastic syndrome that preceded acute myelogenous leukemia by 9 months. (Ann Dermatol 3:(1) 54-57, 1991)

Key Words: Sweet's syndrome, Myelodysplastic syndrome, AML

Acute febrile neutrophilic dermatosis (ND), described by Sweet in 1964, consists of multiple tender, red plaques, often accompanied by fever and neutrophilic leukocytosis. Cutaneous biopsy specimens contain dermal infiltrates of mature neutrophils. Response to systemic steroids is dramatic. The etiology and pathogenesis of Sweet's syndrome is undetermined.¹

Since Matta et al¹ reported the first association of Sweet's syndrome with leukemia in 1973, it has received considerable attention as a cutaneous sign of underlying myeloproliferative disorder. It has been recommended that patients with Sweet's syndrome receive close clinical following.

REPORT OF A CASE

A 51 year old woman visited our clinic with a 2 day history of painful skin lesions accompanied by fever.

The patient reported a 10 year history of easy fatigability. One year prior, she was hospitalized for an anemia workup, at which time, a diagnosis of myelodysplastic syndrome, probable refractory anemia, was made. She was treated conservatively with iron supplementation. During the

preceding month, she abruptly developed like symptoms and body ache. Two days prior, she abruptly developed painful symmetrical erythematous plaques accompanied by high fever.

On physical examination, there were tender well circumscribed 0.6 to 2.5 cm erythematous plaques on the scalp, face (Fig. 1) and lateral and posterior neck (Fig. 2). Several of the lesions were vesicular. Aside from bilateral conjunctivitis, the remainder of the physical examination was within normal limits. The patient's temperature fluctuated from normal to 39.5°C with the resolution and reappearance of the skin lesions.

Laboratory results were remarkable for a hemoglobin of 6.2g/dL, hematocrit of 19.5% and white blood count $11.7 \times 10^3/\text{mm}^3$. The ferritin, serum iron and total iron binding capacity (TIBC) were within normal limits. Examination of the peripheral blood smear showed mild anisocytosis but was otherwise unremarkable.

Microscopically, biopsy of one of the face lesions showed neutrophilic and lymphohistiocytic infiltrates in the upper dermis with small capillary proliferation, consistent with the diagnosis of Sweet's Syndrome (Fig. 3).

The initial clinical diagnosis was Herpes Simplex in an immune compromised patient and Acyclovir treatment was initiated.

Anti-viral treatment was discontinued after the skin biopsy disclosed Sweet's syndrome. On a regimen of topical steroids and analgesic, her skin

Received October 10, 1990

Accepted for publication November 19, 1990

Reprint request to: Jai Il Youn, M.D. Department of Dermatology, College of Medicine, Seoul National University, 28 Yunkun-Dong, Chongno-Ku, Seoul 110-744, Korea

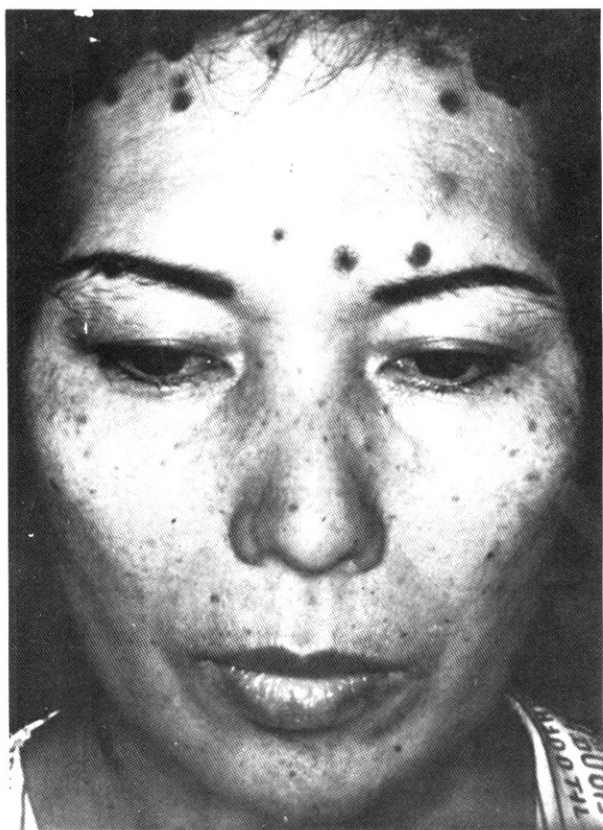

Fig. 1. Symmetrical pea to walnut sized erythematous round plaques with several vesicles on forehead and both cheeks.

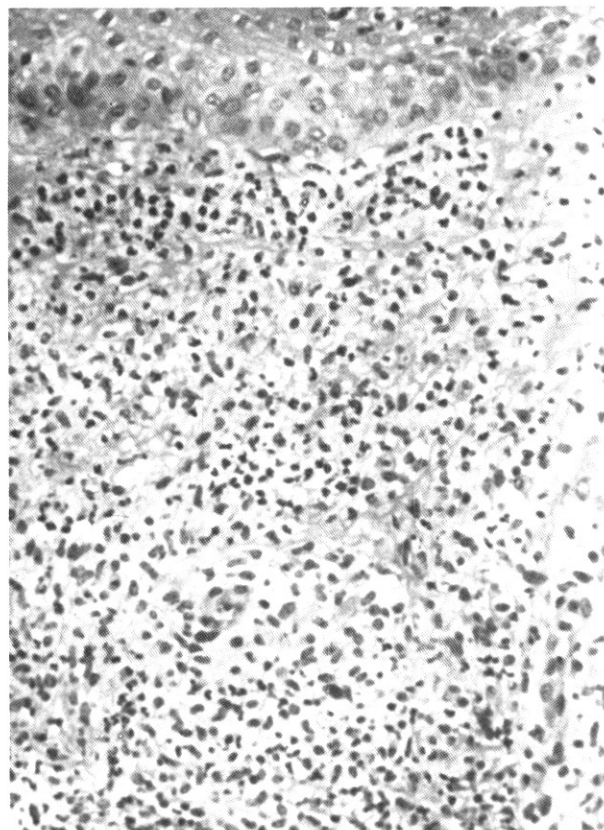


Fig. 3. There are nodular infiltrates of neutrophil and lymphohistiocyte in upper dermis. (H & E, $\times 40$)

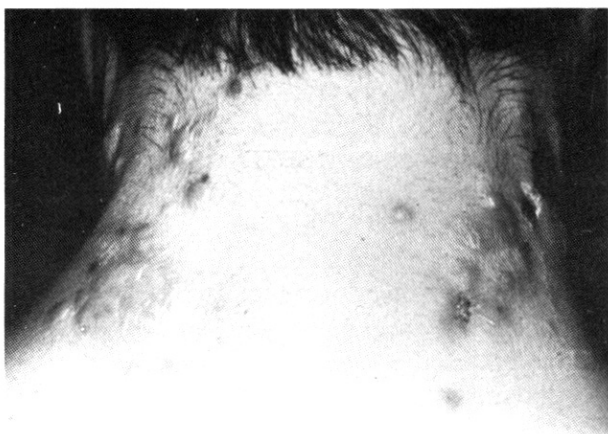


Fig. 2. Pea to walnut sized erythematous round plaques with several vesicles on neck.

bone marrow findings (Table 1). Following induction chemotherapy, she died of acute respiratory distress syndrome 3 months after admission.

DISCUSSION

In the myeloid leukemias and myeloproliferative disorders, cutaneous manifestations, apart from hemorrhagic phenomena, are two types; specific leukemic cell infiltration, often referred to as leukemic cutis and nonspecific infiltration lesions, histologically called leukemids. Over the past decade, two types of inflammatory reactions associated with myeloproliferative disorders have received considerable attention in the literature²⁻⁵; atypical bullous pyoderma gangrenosum and atypical Sweet's syndrome. These two forms of neutrophilic dermatoses have been reported in cases of acute⁵⁻⁹ and chronic myelogenous leukemia¹⁰⁻¹¹, myeloid metaplasia¹², polycythemia

lesions gradually resolved. Nine months later, the patient was readmitted with a productive cough. Acute Myelogenous Leukemia (AML M2) was diagnosed on the basis of peripheral blood and

Table 1. Follow up of laboratory findings

	CBC WBC-Hb-Hct (10 ³ /mm ³) (g/dL) (%)	DDX MB*-Neutro-Lympho (%)	PBS	BM Findings
June '86	2.9-9.1-27.7	0-41-50	W.N.L.	hypercellular marrow myeloid hyperplasia
June '87	11.7-6.2-19.5 3.3-6.0-18.7	0-86-10 0-71-27	W.N.L. —	not done
Sept. '87	2.3-5.7-18.2	0-50-44	—	not done
May '88	25.3-6.5-20.3	75-9-9	—	hypercellular marrow packed with blast cells (AML M2)

*MB: Myeloblast

vera¹³, and occasionally nonmyeloid malignancies such as multiple myeloma¹⁴, diffuse histiocytic lymphoma¹⁵, hairy cell leukemia¹⁶. The carcinomas were all single cases originating in testis¹⁷, rectum¹⁸, prostate¹⁹ and vagina²⁰. Nearly 10% of all reported cases of Sweet's syndrome have been associated with acute myelogenous leukemia (AML). In Korea, Kim *et al*²¹ reported a case of Sweet's syndrome in acute myelogenous leukemia. There have now been 6 cases of myelodysplastic syndrome^{22, 23} reported in association with Sweet's syndrome.

Two clinical forms of Sweet's Syndrome have been described: idiopathic neutrophilic dermatosis which shows no association with hematologic disease and leukemic neutrophilic dermatosis which is associated with underlying hematologic disease. In comparison with idiopathic neutrophilic dermatosis, leukemic neutrophilic dermatosis more frequently occurs in oral mucosa and at the site of previous trauma.

Secondary features such as vesicle formation, present in this case, and ulceration are likewise more common in the disease associated form. Laboratory studies may be useful in distinguishing idiopathic from neutrophilic dermatosis. As would be expected, the presence of anemia or an atypical peripheral blood smear with left shifted white blood count differential supports Sweet's syndrome related to myelodysplasia or leukemia.

The white blood cell count in and of itself may not be a useful discriminator. Klock *et al*⁵ suggested that severe leukocytosis is a common finding in patients with leukemic or preleukemic state. Cooper *et al*²² observed lower white blood cell counts in patients with leukemic neutrophilic dermatosis than in patients with the non disease related type. A recurrence of Sweet's syndrome may herald the onset of more obviously leukemic state. Both forms of the disease respond dramatically to steroid treatment and therefore response to therapy is not a discriminating feature.

According to Jones *et al*¹⁴, of the 54 malignancies reported in association with Sweet's syndrome, 21 had already been diagnosed the time of presentation with the dermatosis as a result of initial investigation. Only in 13 cases was the neoplasm diagnosed later. In all of these cases, there were, in fact, features suggestive of the malignancy present at an early stage, prior to resolution of the rash. Jones *et al*¹⁴ found no documented cases of malignancy developing after complete resolution of the dermatosis in patient with no clinical evidence of neoplasm. Based on these observations, they suggested that follow-up is not necessarily required in all cases of Sweet's syndrome, and conversely, anemia, the persistence of leukocytosis or an elevated erythrocyte sedimentation rate, and a prolonged course or recurrence of the dermatosis are features that

warrant careful follow-up. Guidelines for following have not been established, although the interval between the presentation with Sweet's syndrome and diagnosis of malignancy has been reported from 2 weeks to 7 years¹⁴

REFERENCES

1. Matta M, Malak J, Tabet E, Kurban AK: Sweet's syndrome; systemic associations. *Cutis* 12:561, 1973.
2. Perry HO, Winkelmann RK: Bullous pyoderma gangrenosum and leukemia. *Arch Dermatol* 106:901, 1972.
3. Burton JL: Bullous pyoderma of leukemia. *Br J Dermatol* 95:209, 1976.
4. Soderstrom RM: Sweet's syndrome and acute myelogenous leukemia. *Cutis* 28:255, 1981.
5. Klock JC, Oken RL: Febrile neutrophilic dermatosis in acute myelogenous leukemia. *Cancer* 37:922, 1976.
6. Raimer SS, Duncan WC: Febrile neutrophilic dermatosis in acute myelogenous leukemia. *Arch Dermatol* 114:413, 1987.
7. Spector JJ, Zimble H, Levine R, et al: Sweet's syndrome; Association with acute leukemia. *JAMA* 244:1131, 1980.
8. Lewis SJ, Poh Fitzpatrick MB, Walther RR: Atypical pyoderma gangrenosum with leukemia. *JAMA* 239:935, 1978.
9. Chmel H, Armstrong D: Acute febrile neutrophilic dermatosis; Sweet's syndrome. *South Med J* 71:1350, 1978.
10. Krilov LR, Jacobson M, Shende A: Acute febrile neutrophilic dermatosis presenting as facial cellulitis in a child with juvenile chronic myelogenous leukemia. *Pediatr Infect Dis J* 6:77, 1987.
11. Lewis JE: Bullous pyoderma gangrenosum with chronic myelogenous leukemia; Report of a case. *Cutis* 25:82, 1980.
12. Horan MP, Redmond J, Gehle D, et al: Postpolycythemic myeloid metaplasia, Sweet's syndrome and acute myeloid leukemia. *J Am Acad Dermatol* 16:458, 1987.
13. Shore RN: Pyoderma gangrenosum, defective neutrophil chemotaxis, and leukemia. *Arch Dermatol* 112:1792, 1976.
14. Jones JB, Hutchinson PE: Sweet's syndrome and malignancy: a case associated multiple myeloma and review of the literature. *Br J Dermatol* 121:123, 1989.
15. Schwartz RA, French SW, Rubenstein DJ, et al: Acute neutrophilic dermatosis with diffuse histiocytic lymphoma. *J Am Acad Dermatol* 10:350, 1984.
16. Gisser SD: Acute febrile neutrophilic dermatosis in a patient with hairy cell leukemia. *Am J Dermatopathol* 5:283, 1983.
17. Shapiro L, Baraf CS, Richheimer LL: Sweet's syndrome; report of a case. *Arch Dermatol* 103:81, 1971.
18. Hilder RJ, Simmons LB, Damm SR: Sweet's syndrome; a report of case. *J Assoc Milit Dermatol* 5:17, 1979.
19. Leibowitz MR, Rippey JJ, Bezwoda WR, et al: Unusual aspects of febrile neutrophilic dermatosis. *Aft Med J* 62:375, 1982.
20. Nguyen KQ, Hurst CG, Pierson DL, et al: Sweet's syndrome and ovarian carcinoma. *Cutis* 32:152, 1983.
21. Kim SW, Kwon KS, Chung TA: A case of acute febrile neutrophilic dermatosis in acute myelogenous leukemia. *Korean J Dermatol* 20: 598, 1982.
22. Cooper PH, Innes DJ, Greet KE: Acute febrile neutrophilic dermatosis and myeloproliferative disorders. *Cancer* 51:1518, 1983.
23. Lazarus AA, McMillan M, Miramadi A: Pulmonary involvement in Sweet's syndrome preleukemia and leukemia phases of acute myelogenous leukemia. *Chest* 90:922, 1986.