

# Treatment of Chronic Idiopathic Onychodystrophy with Intake of Carotene-rich Food

Jin Young Jung, M.D., Mi Ryung Roh, M.D., Kee Yang Chung, M.D., Ph.D.

*Department of Dermatology and Cutaneous Biology Research Institute,  
Yonsei University College of Medicine, Seoul, Korea*

**Background:** Onychodystrophy refers to the various abnormalities in nail morphology due to changes in the attachment of the nail plate, changes in nail surface or color. The treatment principle of onychodystrophy largely relies on the discovery and verification of the cause. However, preventive treatment methods offer little help to the patient due to poor compliance, and the effect of corticosteroid is only temporary.

**Objective:** To evaluate the clinical efficacy of carotene-rich food intake in chronic idiopathic onychodystrophy.

**Methods:** Ten patients with chronic idiopathic onychodystrophy were recommended to drink one or two cups of carrot juice daily.

**Results:** Patients showed improvement of onychodystrophy after drinking carrot juice twice a day for at least 4 weeks. No specific adverse effects were noted.

**Conclusion:** Since there are no reliable treatment methods for chronic idiopathic onychodystrophy, we suggest a simple and compliant treatment method consisting of taking carotene-rich food, such as carrot juice, for patients with chronic idiopathic onychodystrophy.  
(Ann Dermatol (Seoul) 20(1) 6~10, 2008)

---

*Key Words:* Carotene-rich food, Carrot juice, Chronic idiopathic onychodystrophy

## INTRODUCTION

Onychodystrophy refers to various abnormalities in nail morphology due to changes in the attachment of the nail plate, changes in nail surface or color. They are associated with a variety of conditions such as psoriasis, onychomycosis, lichen planus, alopecia areata, endocrine disorders, and drug photosensitivity, etc. Local contact with irritants and trauma are the most common causes<sup>1</sup>, but chronic idiopathic onychodystrophy is often seen without any associated conditions. Treatment

modalities include avoidance of predisposing causes and trauma, keeping nails short, and drug therapy such as topical and intralesional corticosteroid. Intralesional corticosteroid injection produces the most reliable results but the response is only temporary and severe pain upon injection prohibits its use. Other modalities do not yield consistent and reliable results. Hsu and Huang<sup>2</sup> previously reported on two patients with prolonged histories of chronic idiopathic onycholysis that dramatically improved after 12 weeks ingestion of papaya juice, which is rich in carotene. However, we have not been able to find any studies on the effect of carotene on nail formation and disorders. The present study was carried out to evaluate the clinical efficacy of ingestion of carrot juice, which is an easily obtainable and rich source of carotene, in a larger number of patients with chronic idiopathic onychodystrophy.

---

Received July 18, 2007

Accepted for publication February 19, 2008

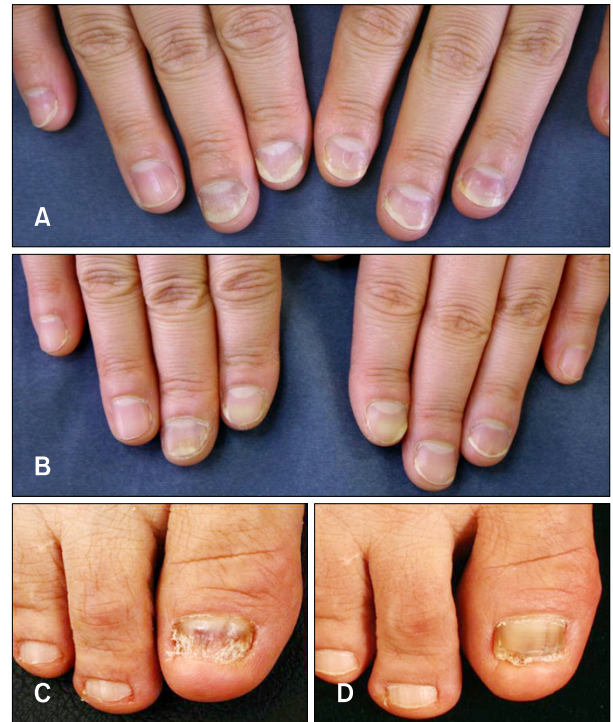
**Reprint request to:** Kee Yang Chung, M.D., Ph.D., Department of Dermatology and Cutaneous Biology Research Institute, Yonsei University College of Medicine, 134, Shinchon-dong, Seodaemoon-gu, Seoul 120-752, Korea. Tel: 82-2-2228-2080, Fax: 82-2-393-9157, E-mail: kychung@yuhs.ac

## MATERIALS AND METHODS

Patients with chronic idiopathic onychodystrophy visiting the outpatient clinic were evaluated. A complete clinical and mycological examination of each patient was done and onychodystrophy associated with any cause was excluded. Ten patients with chronic idiopathic onychodystrophy were selected for the study and a total of 85 nails were evaluated. We instructed patients to make a cup of carrot juice using about 200 g of raw carrot. The patients were recommended to drink one or two cups of carrot juice daily. The results were assessed on the basis of clinician's observation and were graded on a 5-point scale as follows: 0 meant no improvement, 1 meant <25%, 2 meant 25 to 50%, 3 meant 50 to 75%, and 4 meant 75 to 100% improvement<sup>3</sup>. Side effects during the course of the treatment were observed.

## RESULTS

Ten patients with chronic idiopathic onychodystrophy included 4 males and 6 females whose ages ranged at the time of presentation from 5 to 61 years (mean, 36.3). The average duration of nail changes was 3.64 years. None had any family history of similar changes and no systemic abnormalities



**Fig. 1.** (A) A 40-year-old female presented with distal separation of nail plates in all fingers. (B) Two months after drinking two cups of carrot juice daily, onycholysis and trachyonychia improved strikingly in all fingernails. (C) A 61-year-old female complained of nail atrophy, pterygium and trachyonychia on her first toenail. (D) Two months later, the onychodystrophy had improved remarkably.

**Table 1.** Clinical characteristics and responses to ingestion of carrot juice in patients with chronic idiopathic onychodystrophy

Patient	Sex/Age (years)	Duration of CIO	Site (number of involved nails)	Types of CIO	Treatment duration (months)	Treatment response (grade)
1	F/40	1 year	FN (5)	Onycholysis, trachyonychia	4	4
2	M/32	13 years	FN (10)	Onycholysis	2	3
3	F/56	3 years	FN (10)	Koilonychia, onychoschizia	2	2
4	M/11	2 years	FN (10)	Onycholysis, trachyonychia	4	1
5	M/46	1 year	FN (10) TN (2)	Onychoschizia, trachyonychia	1	1
6	F/46	2 years	FN (10)	Beau's line, nail atrophy	2	1
7	F/61	2 years	TN (1)	Trachyonychia	6	4
8	F/5	5 years	FN (6) TN (10)	Beau's line	2	3
9	F/59	5 months	FN (10)	Onycholysis, onychorrhexis	1	2
10	M/7	7 years	FN (1)	Koilonychia, trachyonychia	2	4

CIO: chronic onychodystrophy, FN: fingernail, TN: toenail

were detected in any of the cases. The number of involved nails varied from 1-20 (average 9.5 nails).

We summarized their clinical characteristics and responses to ingestion of carrot juice in Table 1. Out of the 10 patients, 3 experienced 75-100% improvement (Fig. 1) and more than 50% improvement was seen in 5 patients.

The response rate of each nail (a total of 85 nails) was analyzed in Fig. 2. More than 75% improvement was seen in 21.2% of the nails and 20% each showed 50 to 75% and 25 to 50% improvements, respectively. 36.4% showed less than 25% improvement.

The treatment duration varied from 1 month to 6 months depending on the patients' compliance. Interestingly, one case showed initial improvement but recurred when the patient reduced the intake of carrot juice from 2 cups to 1 cup a day. Two months after going back to 2 cups per day, remarkable improvement was seen in all fingernails. However, when she again reduced the amount of juice to 1 cup a day, onycholysis recurred. After she restarted to drink 2 cups of carrot juice daily, onychodystrophy was improved again. In other patients, we could not see recurrences because they wanted to maintain the intake of carrot juice.

## DISCUSSION

Onychodystrophy implies various pathologic processes of the nails including infectious and noninfectious disorders such as onychomycosis, psoriasis, and allergic and irritant dermatitis. Nail changes may also be a clue to other dermatological or systemic diseases. However, chronic idiopathic onychodystrophy is often seen without any associated conditions and onycholysis and onychorrhexis are two of the most common manifestations. Onycholysis refers to the detachment of the nail from its bed at its distal end and/or its lateral attachments. Onychorrhexis is the nail change that shows superficial longitudinal ridges and furrows with frequent distal splitting. The two are often seen together in patients with onychodystrophy<sup>4</sup>. The treatment principle of onychodystrophy largely relies on the discovery and verification of the cause. However, the preventive treatment methods offer little help to the patients due to poor compliance, and the effect of corticosteroid is only temporary.

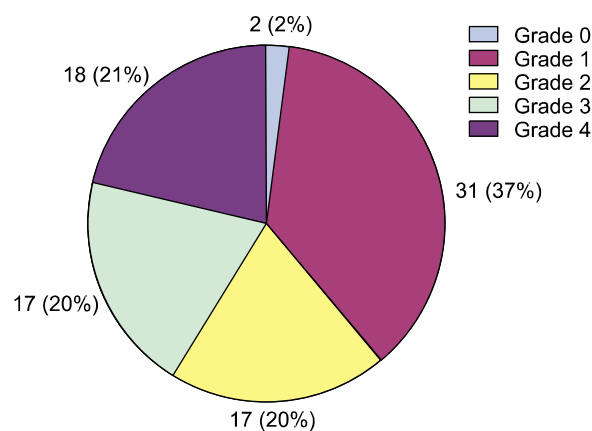


Fig. 2. Response rate of each nail with onychodystrophy after intake of carrot juice (a total of 85 nails in 10 patients).

Therefore, a reliable treatment modality with consistent effect for onychodystrophy is in need.

According to the US Department of Agriculture's database, 200 g of raw carrot contains about 16 mg of  $\beta$ -carotene. We recommend patients to make a cup of carrot juice using 200 g of carrot. In our patients, drinking two cups of carrot juice was more effective than drinking one cup and the result suggests that more than 32 mg of  $\beta$ -carotene was needed for the improvement of the nail changes.

The possibility of spontaneous improvement seems to be small as the nail changes persisted for a prolonged period without any spontaneous improvement and the recovery correlated significantly with the onset of drinking carrot juice. Such a dramatic improvement had never occurred spontaneously nor been achieved by any previous treatment measures.

Carotenoids are natural pigments that are synthesized by plants and are responsible for the bright colors of various fruits and vegetables. There are several dozen carotenoids in the food that we eat and most of these carotenoids have antioxidant effects.  $\beta$ -carotene has been best studied as it is the most common carotenoid in fruits and vegetables. Carotenoid concentrations in fruits and vegetables vary with plant variety, degree of ripeness, time of harvest, and growing and storage conditions. Apricot, cantaloupe, carrot, pumpkin and sweet potato are sources of  $\alpha$ -carotene and  $\beta$ -carotene. Pink grapefruit, tomato and watermelon are sources of lycopene,  $\zeta$ -carotene,  $\beta$ -carotene, phytofluene

and phytoene. Mango, papaya, peach, prune, squash and orange are sources of lutein, zeaxanthin,  $\alpha$ - and  $\beta$ -cryptoxanthin,  $\alpha$ -,  $\beta$ - and  $\zeta$ -carotene, phytofluene and phytoene, whereas green fruits and vegetables such as green beans, broccoli, kiwi, and peas are sources of lutein, zeaxanthin,  $\alpha$ - and  $\beta$ -carotene<sup>5</sup>.

Epidemiologic studies have shown an inverse relationship between presence of various cancers and dietary carotenoids or blood carotenoid levels. However, several trials using  $\beta$ -carotene supplements did not show protective effects against cancer or cardiovascular diseases. On the contrary, the high risk population (smokers and asbestos workers) in these trials showed an increase in cancer and angina<sup>6,7</sup>. It appears that carotenoid can promote health when taken at dietary levels, but may have adverse effects when taken in high dose by subjects who smoke or who have been exposed to asbestos. In nonmelanoma skin cancers primarily consisting of basal cell and squamous cell carcinomas, the effect of  $\beta$ -carotene on cancer prevention is inconsistent<sup>8</sup>. The beneficial effect of carotene-rich food in nail abnormalities, as seen in our patients, may be due to a combination of different carotenoids. It may be the task of ongoing and future studies to define the populations that can benefit from carotenoids and to define the proper dose and length of treatment.

Biologic mechanisms of such protection are currently unclear but several possibilities exist: certain carotenoids 1) can convert to retinoids, 2) can modulate the enzymatic activities of lipoxygenases (proinflammatory and immunomodulatory molecules), 3) can have antioxidant properties which are well above those seen with vitamin A, 4) can activate the expression of genes which encode the message for production of connexin 43, which is an integral component of the gap junctions required for cell to cell adhesion<sup>9</sup>.

Regarding the effect on skin diseases,  $\beta$ -carotene has been successfully used to treat photosensitivity in patients with erythropoietic protoporphyria but it only slightly increases the sunburn threshold in normal humans<sup>10</sup>. Benefits are not seen typically until a few months after therapy is initiated and dosages of up to 180 mg/day is recommended. It is therefore possible that photoprotection is mediated through an alternative mechanism other than a direct sunscreen effect<sup>10</sup>.

The reported side effects after ingestion of carotene rich food are visible yellowing of the skin, diarrhea and orange or rusty discoloration of the stool. The side effects are tolerable and are not indications for discontinuing treatment<sup>11</sup>.

Hsu and Huang<sup>2</sup> previously reported that intake of carotene rich-food in two patients with prolonged histories of chronic idiopathic onycholysis showed dramatic improvement of onycholysis in 3 months. As far as we know, there have been no studies regarding the effect of carotene on nail disorders. However, from the results of Hsu and Huang<sup>2</sup> and the improvements seen in our patients, we propose that carotene may have a role in normal epithelial differentiation and keratinization of the nail plate or photoprotection of the nail bed. Since there are no reliable treatment methods, we suggest a simple and compliant method consisting of taking carotene-rich food in patients with chronic idiopathic onychodystrophy. A further study with carotene-rich food supplements or quantitative intake of specific carotenoids to verify their effect on nail formation is needed.

## REFERENCES

1. Daniel CR. Onycholysis: an overview. *Semin Dermatol* 1991;10:34-40.
2. Hsu MML, Huang YR. Chronic onycholysis dramatically responds to enhanced intake of carotene-rich food. *Br J Dermatol* 2002;147:389-391.
3. Grover C, Bansal S, Nanda S, Reddy BS. Efficacy of triamcinolone acetonide in various acquired nail dystrophies. *J Dermatol* 2005;32:963-968.
4. Paul K. Onycholysis of the fingernails: evaluation and management. *J Am Acad Dermatol* 1985; 12:552-560.
5. Paiva SA, Russell RM.  $\beta$ -carotene and other carotenoids as antioxidants. *J Am Coll Nutr* 1999; 18:426-433.
6. Wang XD, Russell RM. Procarcinogenic and anticarcinogenic effects of  $\beta$ -carotene. *Nutr Rev* 1999;57:263-272.
7. Tavani A, La Vecchia C.  $\beta$ -carotene and risk of coronary heart disease. A review of observational and intervention studies. *Biomed Pharmacother* 1999;53:409-416.
8. Frieling UM, Schamberg DA, Kupper TS, Munt-

- wyler J, Hennekens CH. A randomized, 12-year primary-prevention trial of beta-carotene supplementation for nonmelanoma skin cancer in the physician's health study. *Arch Dermatol* 2000; 136:179-184.
9. Bendich A. Biologic functions of dietary carotenoids. *Ann NY Acad Sci* 1993;691:61-67.
10. Marsden RA, Dawber RP. Erythropoietic protoporphyria with onycholysis. *Proc Roy Soc Med* 1977; 70:572-574.
11. Sayre RM, Black HS. Beta-carotene dose not act as an optical filter in skin. *J Photochem Photobiol* 1992;12:83-90.