

Combined Mastocytoma-hemangioma in a Patient with Urticaria Pigmentosa

Na Reu Seung, M.D., Min Hee Kang, M.D., Eun Joo Park, M.D., Chul Woo Kim, M.D.,
Hee Jin Cho, M.D., Kwang Ho Kim, M.D., Ph.D., Kwang Joong Kim, M.D., Ph.D.

Department of Dermatology, College of Medicine, Hallym University, Anyang, Korea

A patient with long-standing urticaria pigmentosa presented with a pea-sized reddish to purplish papule on the posterior part of the right ear. Histopathologic examination revealed numerous dilated vascular structures in the upper dermis and mast cell infiltrations throughout the whole dermis, consistent with combined mastocytoma-hemangioma. The mast cells were strongly positive with Giemsa stain.

(Ann Dermatol (Seoul) 20(3) 153~156, 2008)

Key Words: Hemangioma, Mastocytoma

INTRODUCTION

Mast cells are specialized secretory cells distributed in connective tissues throughout the body. In the skin, mast cells are present in the papillary dermis, near the dermo-epidermal junction, in the sheath of epidermal appendages, and around the blood vessels and nerves of the subpapillary plexus¹. Mast cells synthesize various kinds of mediators, some of which are preformed and stored in the granules, while others are synthesized and released without storage¹. Among the mediators of mast cells, heparin, tumor necrosis factor α (TNF- α), transforming growth factor β (TGF- β), basic fibroblast growth factor (bFGF), tryptase, vascular permeability factor (VPF), and vascular endothelial growth factor (VEGF) have been suggested to contribute to various aspects of neovascularization²⁻⁵. In addition, some reports have shown the increased number of mast cells and angiogenic mediators from mast cells are increased in hemangiomas and

vascular malformations^{6,7}. However, the simultaneous occurrence of mastocytoma and hemangioma is rarely reported. We describe a case of combined mastocytoma-hemangioma that occurred in a patient with urticaria pigmentosa.

CASE REPORT

A 53-year-old woman was presented to our clinic to evaluate an asymptomatic skin lesion on the right ear that had developed two years before. Her past medical history was contributory to urticaria pigmentosa since childhood which had been treated by PUVA (Fig. 1). Bone marrow biopsy, which was performed before the skin lesion developed, revealed hypercellularity (90%) and hyperplasia (50%) of mast cells. Mast cells in bone marrow were positive for specific esterase, c-kit (CD117). Complete blood count and blood chemistry studies were normal ranged except for a slight thrombocytopenia. There was no family history for skin cancer or mastocytosis. On the physical examination, there was a 0.5×0.7 cm reddish to purplish soft papule on the posterior part of right ear (Fig. 2). But the Darier's sign was unsuspicious. Excisional biopsy was performed, and the specimen was fixed in 10% formalin and routinely embedded into paraffin for H&E and Giemsa staining. The H&E stained section revealed flattened rete ridge without basal

Received May 17, 2007

Accepted for publication March 12, 2008

Reprint request to: Kwang Joong Kim, M.D., Ph.D.,
Department of Dermatology, Hallym University Sacred
Heart Hospital, 896, Pyeongchon-dong, Dongan-gu, An-
yang 431-070, Korea. Tel: 82-31-380-3763, Fax: 82-31-
386-3761, E-mail: kkj51818@hallym.or.kr

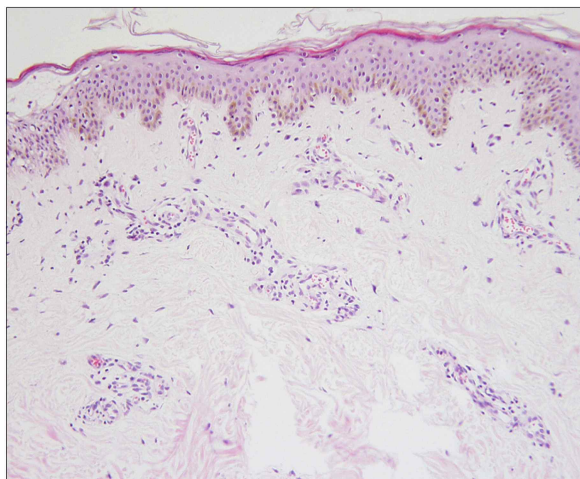


Fig. 1. Biopsy specimen of the skin lesion of urticaria pigmentosa before hemangioma developed. Hyperpigmented basal layer and scattered cuboidal mast cells in the dermis, especially at the perivascular area (Hematoxylin-Eosin stain; original magnification, $\times 400$).

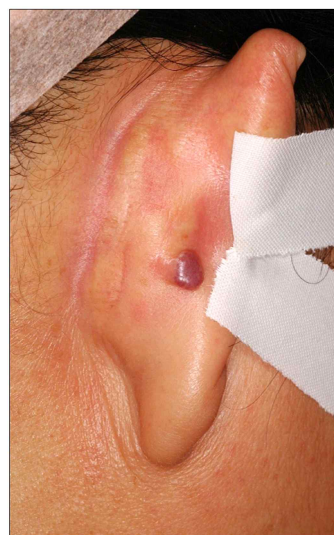


Fig. 2. A 0.5×0.7 cm sized reddish to purplish soft papule on the posterior part of the right ear.

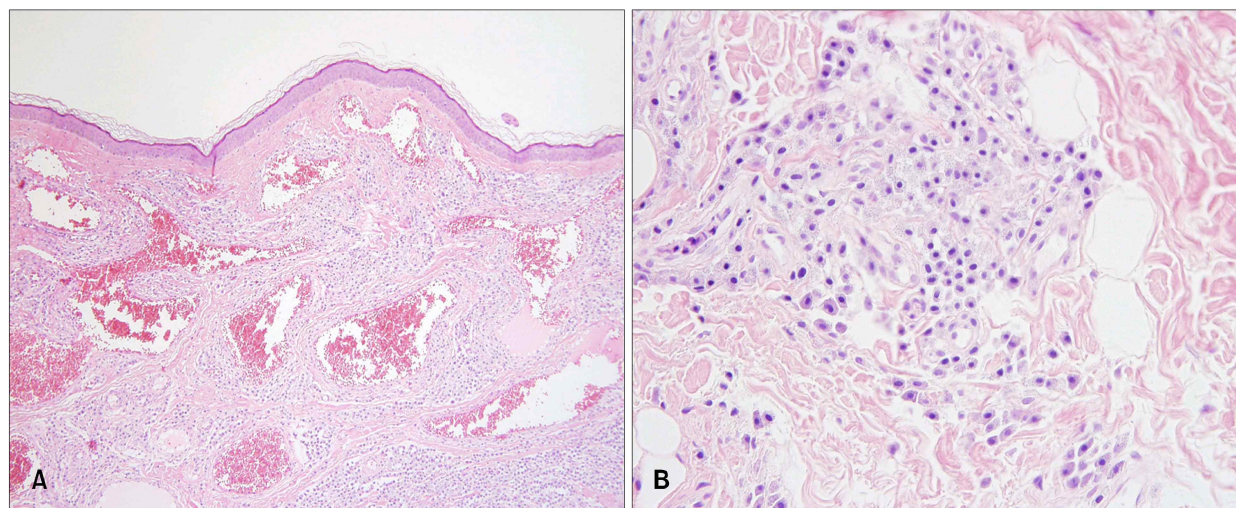


Fig. 3. Excisional biopsy specimens of the skin lesion showed (A) flattened rete ridge without basal hyperpigmentation, multiple dilated endothelial cell-lined vascular structures containing red blood cells in the upper dermis, and densely infiltrated mast cells throughout the whole dermis including the intercapillary stroma (Hematoxylin-Eosin staining; original magnification, $\times 100$). (B) At the higher magnification view, the infiltrated mast cells were shown as round to cuboidal cytoplasm with central ovoid nuclei (Hematoxylin-eosin stain; original magnification, $\times 400$).

hyperpigmentation in the epidermis. In the upper dermis, multiple dilated endothelial cell-lined vascular structures containing red blood cells were shown, and mast cells were densely infiltrated throughout the whole dermis including the inter-

capillary stroma (Fig. 3A). At the higher magnification view, the infiltrated mast cells were shown as round to cuboidal cytoplasm with central ovoid nuclei. They also had basophilic granules in the cytoplasm (Fig. 3B). In Giemsa staining, mast cells

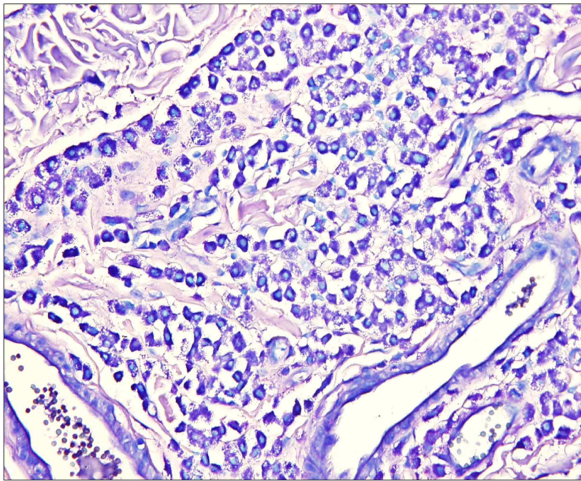


Fig. 4. Mast cells with abundant fine purple metachromatic cytoplasmic granules were observed (Giemsa stain; original magnification, $\times 400$).

with abundant fine purple metachromatic cytoplasmic granules were observed (Fig. 4). The clinicopathologic features suggested a synchronous development of mastocytoma and hemangioma and we diagnosed this lesion as combined mastocytoma-hemangioma. During one year follow-up after excision, there was no evidence of recurrence.

DISCUSSION

Mastocytosis is characterized by the abnormal growth and accumulation of neoplastic mast cells in one or more organs. The skin is the most common site for the abnormal accumulation of mast cells, known as cutaneous mastocytosis⁸. Clinical categories of cutaneous mastocytosis, in order of frequency of occurrence, include urticaria pigmentosa, mastocytoma, diffuse cutaneous mastocytosis, and telangiectasia macularis eruptiva perstans (TMEP)⁸. It has been reported that mastocytoma had developed in a patient in association with another form of cutaneous mastocytosis. Okun and Bhawan⁹ reported a combined melanocytoma-mastocytoma in a patient of nodular mastocytosis, and Wood et al.¹⁰ reported a case of fibrous mastocytoma in a patient with generalized cutaneous mastocytosis. Our patient had had urticaria pigmentosa since childhood and two years prior to examination, combined mastocytoma-hemangioma had developed as another

histopathologic features from those previously reported.

The pathogenesis of developing combined mastocytoma-hemangioma is not clear, but there is some evidence that some mast cell mediators could induce neovascularization. Increased numbers of mast cells are often associated with rapidly growing capillaries in some conditions such as chronic inflammation or tumors². An increased number of mast cells was found in the growing stages of strawberry hemangioma, and a significantly greater number of mast cells was found in angiolipomas than in classic lipomas^{6,11}. These examples lead us to suggest that mast cells might be associated with the growth of new vessels. It has been reported that some mast cell mediators might contribute to various aspects of neovascularization. Taylor and Folkman¹² showed that heparin could enhance angiogenesis induced by tumor extracts implanted in a chick embryo. It was revealed that heparin induced angiogenesis by significant migration of endothelial cells¹³. Heparin has also been found to have a very high binding affinity for endothelial cell growth factors, some of which are angiogenic¹⁴. Moreover, Qu et al.¹⁵ suggested that mast cells may be a significant source of tissue bFGF, one of the most potent angiogenic factors has been shown to induce angiogenesis, in angiogenic condition. Using specific antibodies, they demonstrated a marked spatial correlation between bFGF immunoreactivity and mast cells in cutaneous hemangioma. Such correlation indicates that mast cells could be a source of tissue bFGF during neovascularization. Boesiger et al.⁵ reported that human mast cells can produce and secrete VPFs and VEGFs, which are important regulators of neovascularization. It was revealed that mast cells can secrete VPF and VEGF upon activation via the Fc ϵ receptor (Fc ϵ RI). Moreover, they found that the IgE-dependent secretion of VPF and VEGF can be significantly increased in mast cells, which undergo IgE-dependent upregulation of their surface expression of Fc ϵ RI. In particular, they found that neoplastic mast cell lines can secrete greater amounts of VPF and VEGF than nonneoplastic mast cells. According to these findings, we suggest that the development of hemangioma could be induced by mast cell mediators such as heparin, basic fibroblast growth factor, vascular permeability factor, and vascular endothelial growth factor, which have

angiogenic properties.

REFERENCES

1. Chu DH, Haake AR, Holbrook K, Loomis CA. The structure and development of skin. In: Freedberg IM, Eisen AZ, Wolff K, Austen KF, Goldsmith LA, Katz SI, editors. *Fitzpatrick's dermatology in general medicine*. 6th ed. New York: McGraw-Hill, 2003:58-87.
2. Folkman J. Regulation of angiogenesis: a new function of heparin. *Biochem Pharmacol* 1985;34: 905-909.
3. Gordon JR, Galli SJ. Release of both preformed and newly synthesized tumor necrosis factor α (TNF- α)/cachectin by mouse mast cells stimulated via the Fc ϵ RI. A mechanism for the sustained action of mast cell-derived TNF- α during IgE-dependent biological responses. *J Exp Med* 1991;174:103-107.
4. Gordon JR, Galli SJ. Promotion of mouse fibroblast collagen gene expression by mast cells stimulated via the Fc ϵ RI. Role for mast cell-derived transforming growth factor β and tumor necrosis factor α . *J Exp Med* 1994;180:2027-2037.
5. Boesiger BJ, Tsai M, Maurer M, Umaguchi M, Brown LF, Claffey KP, et al. Mast cell can secrete vascular permeability factor/vascular endothelial cell growth factor and exhibit enhanced release after immunoglobulin E-dependent upregulation of Fc ϵ receptor I expression. *J Exp Med* 1998;188: 1135-1145.
6. Pasyk KA, Grabb WC, Cherry GW. Ultrastructure of mast cells in growing and involuting stages of hemangiomas. *Hum Pathol* 1983;14:174-181.
7. Glowacki J, Mulliken JB. Mast cells in hemangiomas and vascular malformations. *Pediatrics* 1982;70:48-51.
8. Inamadar AC, Palit A. Cutaneous mastocytosis: report of six cases. *Indian J Dermatol Venereol Leprol* 2006;72:50-53.
9. Okun MR, Bhawan J. Combined melanocytoma-mastocytoma in a case of nodular mastocytosis. *J Am Acad Dermatol* 1979;1:338-347.
10. Wood C, Sina B, Webster CG, Kurgansky D, Drachenberg CB, Reedy EA. Fibrous mastocytoma in a patient with generalized cutaneous mastocytosis. *J Cutan Pathol* 1992;19:128-133.
11. Shea CR, Prieto VG. Mast cells in angiolipomas and hemangiomas of human skin: are they important for angiogenesis? *J Cutan Pathol* 1994;21: 247-251.
12. Taylor S, Folkman J. Protamine is an inhibitor of angiogenesis. *Nature* 1982;297:307-312.
13. Azizkhan RG, Azizkhan JC, Zetter BR, Folkman J. Mast cell heparin stimulates migration of capillary endothelial cells in vitro. *J Exp Med* 1980;152:931-944.
14. Shing Y, Folkman J, Sullivan R, Butterfield C, Murray J, Klagsbrun M. Heparin affinity: purification of a tumor-derived capillary endothelial cell growth factor. *Science* 1984;223:1296-1299.
15. Qu Z, Liebler JM, Powers MR, Galey T, Ahmadi P, Huang XN, et al. Mast cells are a major source of basic fibroblast growth factor in chronic inflammation and cutaneous hemangioma. *Am J Pathol* 1995;147:564-573.