

A Case of Centrifugal Lipodystrophy with Apoptotic Process in the Fatty Tissue

Han Suk Cho, M.D., Eun Joo Park, M.D., Chul Woo Kim, M.D.,
Kwang Ho Kim, M.D., Kwang Joong Kim, M.D.

*Department of Dermatology, Hallym Sacred Heart Hospital, College of Medicine,
Hallym University, Anyang, Korea*

We report a typical case of centrifugal lipodystrophy. This rare disorder is also called lipodystrophia centrifugalis abdominalis infantilis or lipodystrophia centrifugalis abdominalis juvenilis. An 8-year-old-boy had a slightly depressed area with an erythematous to purplish border on the right lower abdomen and inguinum, which gradually spread centrifugally. Histopathologic examination showed periappendeal and perivascular inflammatory infiltrations involving the dermis and loss of subcutaneous fatty tissue. Immunohistochemical analysis by TUNEL stain revealed possible involvement of apoptosis in the degenerating fatty tissue. (*Ann Dermatol* 17(2) 92~94, 2005)

Key Words: Centrifugal lipodystrophy, Apoptosis

INTRODUCTION

Centrifugal lipodystrophy, first described by Imamura et al. in 1971, is a rare disorder which mainly occurs in Asian people¹. Centrifugal lipodystrophy is characterized by a loss of subcutaneous fatty tissue, commonly in the abdomen or inguinal areas, and centrifugal extension of the border area^{1,2}. The cause of this disease remains unknown, though several hypotheses including traumatic stimuli, infection, metabolic abnormality and genetic abnormalities have been presented^{1,2}. We report a case of centrifugal lipodystrophy showing the involvement of apoptosis in the degenerating fatty tissue and think that apoptosis of the fat cells is related to the

pathogenesis of this disease.

CASE REPORT

An 8-year-old boy presented with a 2-year history of a skin lesion on the right lower abdominal wall and inguinal area. The lesion, which gradually spread centrifugally from bruise after 2 years history of contusion was slightly depressed and had an erythematous to purplish border. The patient's past medical and family history was unremarkable. Laboratory studies, including a routine chemistry profile, complete blood count, urine analysis, C3, C4 and FANA were within normal limits. Physical examination revealed a localized, huge, depressed skin colored patch with an erythematous to purplish border on the right lower abdomen (Fig. 1). Underlying vessels in the skin and inguinal lymphadenopathy were found. A skin biopsy specimen taken from the center of the depressed area revealed periappendeal, perivascular inflammatory infiltrations on the mid-dermis with loss of subcutaneous fat cells (Fig. 2A). A biopsy specimen taken from the erythematous edge area also revealed periappendeal inflammatory infiltration on the lower dermis with decrease of subcutaneous fat cells infiltrated by lymphocytic

Received March 18, 2005

Accepted for publication June 21, 2005

Reprint request to: Kwang Ho Kim, Department of Dermatology, Hallym Sacred Heart Hospital, College of Medicine, Hallym University, 896 Pyeongchon-dong, Dongan-gu, Anyang-si, Gyeonggi-do, 431-070, Korea.
Tel. (031)380-3763, Fax: (031)386-3761
E-mail. dermakkh@yahoo.co.kr

* This paper was presented orally at the 4th China-Korea International Conference of Dermatology & Mycology in Guangzhou, China on November 3-4, 2004.

infiltration (Fig. 2B). An immunohistochemical study by TUNEL stain was positive in the mononuclear cells around the degenerating subcutaneous fatty tissue. Staining of the erythematous edge area was stronger than the depressed area (Fig. 3A, B). On the basis of these clinical and histological findings, the diagnosis of centrifugal lipodystrophy was made. The patient was treated with a topical corticosteroid application for 3 months, but this was ineffective. Moreover, the erythematous border spreaded to the left abdominal wall, and the underlying vessels was seen more distinctly.

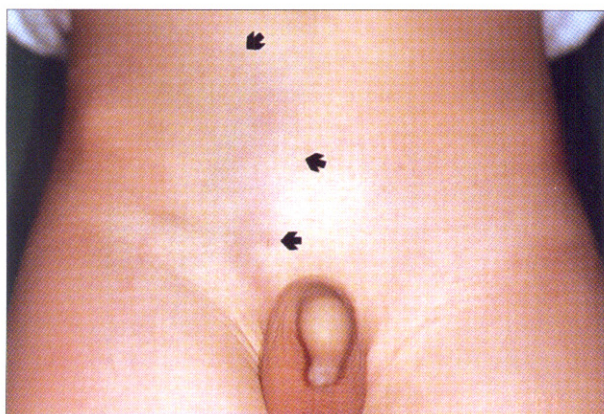

Fig. 1. Slightly depressed, huge, skin-colored patch with an erythematous to purplish border on the right lower abdomen and inguinal area.

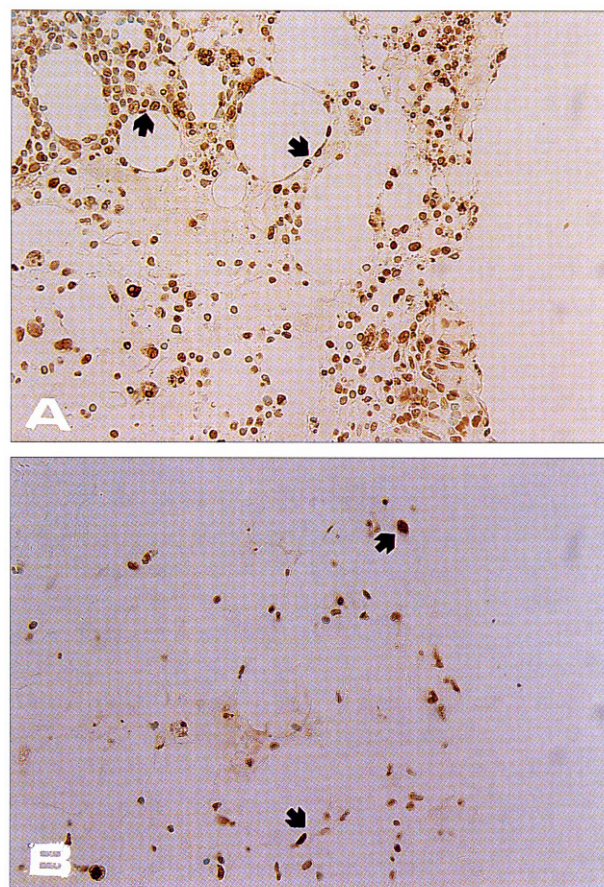
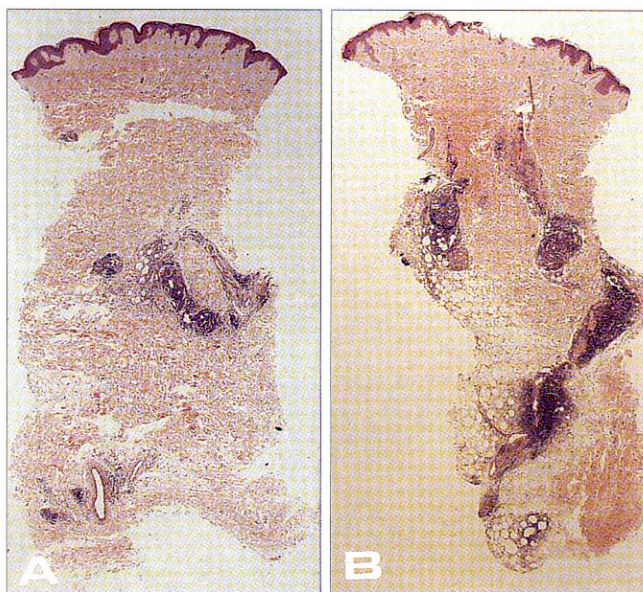


Fig. 3. Immunohistochemically, positive staining by TUNEL on the advancing edge area. (A) was stronger than on the depressed area. (B) (TUNEL, × 400).

Fig. 2. A. From the depressed area, perivascular inflammatory infiltrations on the mid dermis and loss of fatty tissue (H&E, × 40), B. From the edge area, periappendeal and perivascular inflammatory infiltrations on the mid and lower dermis and decrease of fatty tissue infiltrated by inflammatory cells (H&E, × 40).

DISCUSSION

The centrifugal lipodystrophy was first described by Imamura *et al.* in 1971 as lipodystrophia centrifugalis abdominalis¹. The characteristic features are (a) a depression of the skin resulting from the loss of subcutaneous fat which involves most of the abdomen and neighbouring region: (b) centrifugal enlargement of the depressed area: (c) slightly reddish and scaly changes in the skin of the surrounding area: (d) onset before 3 years of age: (e) no significant abnormalities in any other cutaneous location or in other organs^{3,5}. Usually centrifugal lipodystrophy regresses spontaneously with a tendency towards remission or eventual healing of the skin lesions at puberty, although the disease may remain until adulthood^{3,5}. Laboratory studies in centrifugal lipodystrophy frequently show a decrease of serum C3 levels⁶ and urine analysis sometimes reveals proteinuria⁷.

Histopathologically, centrifugal lipodystrophy shows a reduction of subcutaneous fat, with scant inflammatory changes in the well-depressed areas and a moderate or marked inflammatory infiltrate in the subcutaneous fat of the surrounding edge^{3,5,8}. The mechanism of centrifugal lipodystrophy also remains unknown, although several hypotheses have been presented; that the degeneration of fatty tissue is the primary change, and the inflammatory change observed in the periphery is a reactive change⁸⁻¹⁰. In the degenerating subcutaneous fatty tissue, positive staining for HLA-DR, bcl-2, Fas and TUNEL were observed, and these results showed the involvement of apoptosis in fatty tissue degeneration¹⁰. Topical or systemic corticosteroid application was suggested as a treatment method, but effective modalities have not yet been established^{5,8}.

We report a typical case of centrifugal lipodystrophy with apoptosis of degenerating fatty tissues. And we performed TUNEL staining to study the possible involvement of apoptosis in the degenerating fatty tissues. In the degenerating subcutaneous fatty tissue, positive staining for TUNEL in the

mononuclear cells was observed. And staining of the erythematous edge area was stronger than the depressed area. These findings suggest the possibility of the involvement of apoptosis in fatty tissue degeneration as a pathogenesis of centrifugal lipodystrophy.

REFERENCES

1. Imamura S, Yamada M, Ikeda T: Lipodystrophia centrifugalis abdominalis infantilis. *Arch Dermatol* 1971;104:291-298.
2. Mizoguchi M, Nanko S: Lipodystrophia centrifugalis abdominalis infantilis in dizygotic twins. *J Dermatol* 1982;9:139-143.
3. Llistosella E, Puig L, Perez F: Lipodystrophia centrifugalis abdominalis infantilis: A case report. *Ped Dermatol* 1997;14:216-218.
4. Hiraiwa A, Takai K, Fukui Y, Adachi A, Fujii H: Nonregressing lipodystrophia centrifugalis abdominalis with angioblastoma. *Arch Dermatol* 1990; 126:206-209.
5. Ahn HY, Myung KB, Kook HI: Two cases of lipodystrophia centrifugalis abdominalis juvenilis. *Kor J Dermatol* 1984;27:465-469.
6. Alper CA, Bloch KJ, Rosen FS: Increased susceptibility to infection in a patient with type II essential hypercatabolism of C3. *N Eng J Med* 1973;288:01.
7. Peters DK, Williams DG, Charlesworth JA, *et al*: Mesangiocapillary nephritis, partial lipodystrophy and hypocomplementemia. *Lancet* 1973;8:535.
8. Giam YC, Rajan VS, Hock OB: Lipodystrophia centrifugalis abdominalis infantilis. *Br J Dermatol* 1982;106:461-464.
9. Shimizu M: Lipodystrophia centrifugalis abdominalis infantilis in pregnancy. *Jpn J Clin Dermatol* 1998;40:1722-1723.
10. Okita H, Ohtsuka T, Yamakage A, Yamazaki S: Lipodystrophia centrifugalis abdominalis infantilis-Immunohistochemical demonstration of an apoptotic process in the degenerating fatty tissue. *Dermatol* 2000;201:370-372.