

A Case of Cactus Bristle Dermatitis in a Patient with Leprosy

Sang Min Lee, M.D., Yun Jeong, M.D., Kee Han Sung, M.D., Hyung Uk Choi, M.D.,
Sook Kyung Lee, M.D.

Department of Dermatology, Maryknoll Hospital, Busan, Korea

Plants and plant products can cause dermatitis in humans. Although physical injury to the skin from contact with cacti is a frequent event, the subsequent development of a clinically evident dermatitis is unusual. Acute dermatitis can evolve into a typical foreign-body granulomatous reaction. We report a case of cactus bristle dermatitis in a patient with leprosy. (*Ann Dermatol* 17(2) 71~74, 2005)

Key Words: Cactus bristle, Dermatitis, Leprosy

Cactus skin injuries are not limited to the natural habitat of cactus plants. They can occur anywhere due to the abundance of ornamental cacti in homes and botanical gardens. We describe a case of dermatitis resulting from contact with *Opuntia macbridei* in a patient with leprosy. Because the patient did not realize that she had been in contact with a cactus, we had difficulty with diagnosis during the initial examination.

CASE REPORT

A 60-year-old woman presented with a 1-month history of asymptomatic, 2-3 mm sized erythematous papules on the trunk and extremities. Similar skin lesions had occurred on her husband too, but had disappeared without treatment. Since 17 years of age, she had suffered from leprosy, of which we did not know the subtype. She had a grade I disability, with the presence of anesthesia but no damage. She repeatedly denied having a history of trauma to the involved area. Physical examination showed asymp-

tomatic, erythematous papular eruptions on the trunk and extremities (Fig. 1A). Fine, yellow, hair-like structures could be seen emanating from some of the papular lesions (Fig. 1B). Histologic examination of a biopsy specimen showed the foreign material embedded deep in the dermis (Fig. 2A). The fragments of foreign material were stained red with PAS stain, suggesting a possible vegetable origin (Fig. 2B).

Further questioning of the patient disclosed the existence of a cactus in her house. This cactus was identified as *Opuntia macbridei* (Fig. 3A). Microscopic examination of the cactus bristles (Fig. 3B) from her house showed that it was identical to that which was present in her skin. Finally we diagnosed her case as cactus bristle dermatitis. We removed the cactus bristles with tweezers and provided an anti-inflammatory agent and topical corticosteroids.

During the follow-up examination, the papular lesions became less erythematous and steadily decreased in size. 2 months after treatment, the papular eruptions had resolved.

DISCUSSION

Nowadays cactus are popular house plants, so skin lesions caused by physical injury from contact with cacti are not uncommon. The *Opuntia* genus of cactus, consisting of more than 31 species, is the only genus responsible for granulomas¹. Members of the *Opuntia* genus have bristles or glochidia 3-6 mm

Received January 29, 2005

Accepted for publication May 31, 2005

Reprint request to: Sang Min Lee, M.D., Department of Dermatology, Maryknoll Hospital, 12, 4ga, Daechung-dong, Jung-gu, Busan 600-094, Korea.

Tel. 82-51-461-2564, Fax: 82-51-467-3232

E-mail. yellowti@hanmail.net

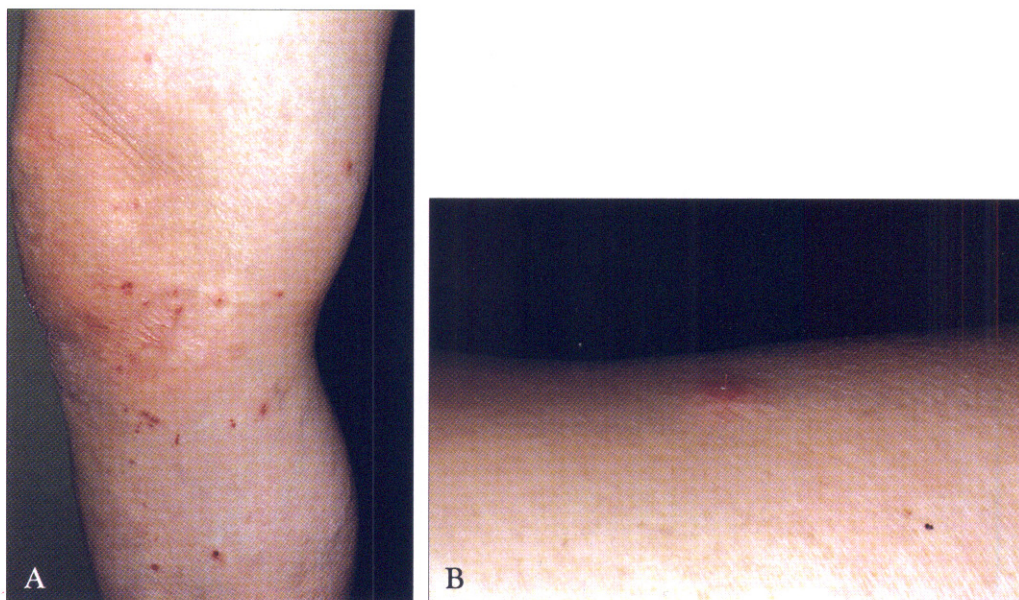


Fig. 1. (A) Erythematous papular eruptions on the right lower extremity. (B) Fine, yellow, hair-like structure in the center of a papule on the right arm.

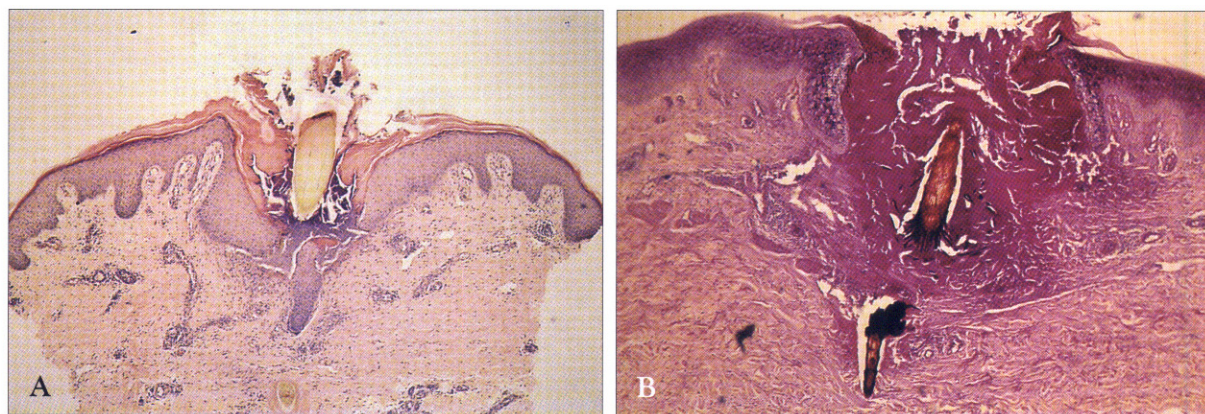


Fig. 2. (A) Biopsy specimen 1 month after cactus bristle implantation shows vertically oriented cactus barb perforating the epidermis and nodular inflammatory cell infiltrates surrounding the retained cactus barb in the dermis (H&E $\times 20$). (B) The fragments of foreign material with angulated barbs are stained red with PAS stain, suggesting a possible vegetable origin (PAS $\times 40$).

long². These bristles are capable of piercing the skin, even at the slightest contact, and can be transferred to other parts of the body by the hands or clothing, resulting in an eruption mimicking scabies in its distribution¹. The chief symptoms of cactus spine penetration to the skin are an immediate burning sensation, redness and swelling, which remain for about 1 to 3 days if the spines are removed³. On histologic finding, our patient's 1-month old lesions

had begun to show the foreign-body granulomatous reaction surrounded by retained barbs in the dermis. It is unknown if leprosy affects cactus granuloma formation. Although the mechanism of the granulomatous inflammatory response to cactus spines has not yet been determined, an allergic reaction to spine antigens, or mechanical irritation resulting in a foreign body granuloma, are the two main theories¹. Since granulomatous reactions are rare

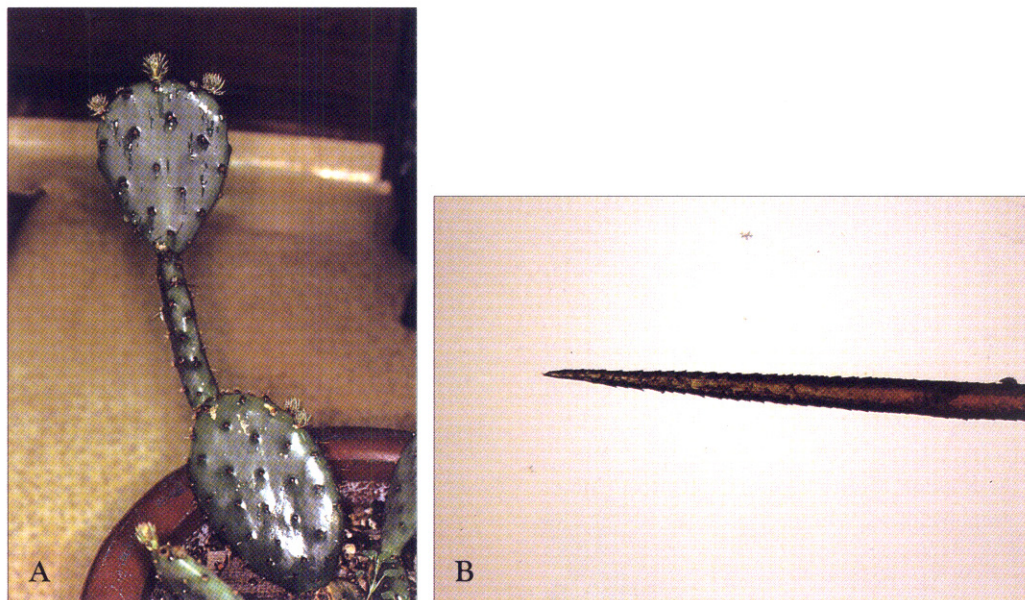


Fig. 3. (A) *Opuntia macbridei* which was present in her house. (B) Microscopic examination of the cactus bristle present in her house showed a fine bristle containing multiple, angulated barbs along its shaft ($\times 40$).

compared to the large number of cactus spine injuries, Schreiber and colleagues proposed an allergic mechanism for the inflammatory response¹. This theory is supported by positive delayed hypersensitivity intradermal skin test reactions with *Opuntia glochid* extracts in 4 of 6 patients who developed cactus granulomas⁴. The report by Snyder and Schwartz suggested that cactus granulomas represent a nonspecific, foreign body reaction². They observed a case demonstrating a mixed cellular granulomatous infiltrate with foreign body giant cell, as opposed to an organized epithelioid tubercle formation, which they expected in immunogenic granulomas⁵. Additional studies are needed to clarify the nature of the granulomatous response to cactus injuries.

Diagnosis of the cause of this eruption can be difficult, when a history of contact with an offending cactus is not initially elicited or forthcoming from the patient.

Moreover, it is not easy to appreciate cactus bristles clinically on a patient's skin, when the extent of contact is minimal and the number of clinical lesions is small. The key to diagnosis, when a history is not helpful, lies in the recognition of foreign material in the biopsy specimen². Because cactus spines contain a polysaccharide^{3,5}, positive staining with PAS is helpful in suggesting a possible plant

source for the foreign materia. In addition, cactus spines can be identified in many cases with xeroradiography⁶.

Treatment of this dermatitis is not easy. The magnitude of the problems caused by cactus spine injury is inversely proportional to the size of the spines⁷. Generally, it is easier to remove long and medium spines, than to remove small spines and spine fragments embedded in the skin. Various techniques for dislodging the bristles have been suggested, including mechanical removal with tweezers and stripping of the affected skin with adhesive tape or glue. The combination of tweezers and glue is by far the most effective method⁸. Tweezers are most effective in removing bunches of spines, while the glue is highly effective in removing individual, small spines⁸. The adhesive tape treatments, although initially effective in removing spines, actually made the situation worse 3 days later⁸. Although it removes some spines, the adhesive tape treatment actually pushed other spines deeper into the skin, resulting in increased retention and inflammation⁸. Topical corticosteroids and other nonspecific antiinflammatory measures can provide symptomatic relief until the inflammatory process resolves spontaneously².

In view of the widespread use of cacti as house

plants, it is possible that cactus bristle dermatitis is frequently misdiagnosed. Cactus bristles should be considered as one possible cause of a nonspecific dermatitis when there is a history of contact with cacti or when pathologic specimens show PAS-positive material with a foreign-body granulomatous reaction.

REFERENCES

1. Michael M. Schreiber, Seymour I. Shapiro, Carl Z. Berry: Cactus granulomas of the skin. *Arch Dermatol* 1971;104:374-379.
2. Robert A. Snyder, Robert Allen Schwartz: Cactus Bristle Implantation. *Arch Dermatol* 1983;119: 152-154.
3. Louis H. Winer, Robert H. Zeilenga: Cactus granulomas of the skin. *Arch Dermatol* 1955;72: 566-569.
4. Alexander Doctoroff, Allison T. Vidimos, James S Taylor: Cactus skin Injuries. *Cutis* 2000;55:290-292.
5. Epstein WL: Cutaneous granulomas. *Int J Dermatol* 1978;16:574-579.
6. Pond GD, Lindsey D: Localization of cactus, glass and other foreign bodies in soft tissues. *Ariz Med* 1977;34:700-702.
7. Douglas Lindsey, Wally E. Lindsey: Cactus spine injuries. *Am J Emerg Med* 1988;6:362-369.
8. Terry T. Martinez, Micky Jerome, Richard C. Barry, et al.: Removal of cactus spines from the skin. *Am J Dis Child* 1987;141:1291-1292.