

Three Cases of Verruca Plana Treated Successfully with 5% Imiquimod Cream

Hei Sung Kim, M.D., Hyun Jeong Park, M.D., Jun Young Lee, M.D., Baik Kee Cho, M.D.

*Department of Dermatology, St. Mary's Hospital, College of Medicine,
The Catholic University of Korea, Seoul, Korea*

Imiquimod is an immune-response modifier, currently approved by the FDA for topical treatment of external genital and perianal warts. Verruca plana (flat warts) is a common disease, which can cause substantial cosmetic problems. Three patients with verruca plana resistant to other therapies, including topical retinoic acid, were treated with 5% imiquimod cream. Complete resolution of the lesions occurred within a month of applying topical imiquimod cream. No serious side effects were observed after application of topical imiquimod cream. Due to the success of this treatment, we consider topical imiquimod cream to be a good treatment modality for verruca plana, especially in the cases resistant to conventional therapies. (*Ann Dermatol* 17(1) 38~40, 2005)

Key Words: Imiquimod, Verruca plana

INTRODUCTION

Imiquimod, an imidazoquinoline amine, is a new immune response modifier for local application and is currently approved as a treatment of choice for anogenital warts^{1,2}. Imiquimod exerts its action by stimulating the release of cytokines from local peripheral blood mononuclear cells and keratinocytes. Enhancement of Langerhans cell migration from skin to lymph nodes has been observed too^{3,4}.

Imiquimod might be effective on verruca plana, as the etiologic origin of anogenital warts and those of verruca plana are similar. The efficacy and safety of imiquimod has been demonstrated in patients with recalcitrant flat warts^{5,6}. Successful topical therapy of imiquimod on verruca plana has not been reported in Korea. Herein, the authors report three cases of verruca plana treated with 5% topical imiquimod cream, which has demonstrated excellent clinical

results without serious side effects.

CASE REPORT

Case 1

Crops of flat warts with predilection to the area below the eyebrows, were observed on the face of a 19-year-old female over a 1 month period (Fig. 1A). The patient had a long history of inflammatory acne and had been under therapy with oral, topical isotretinoin, and chemical peeling. Histopathologically, hyperkeratosis, acanthosis and vacuolization of the cells in the granular layer were observed, and were found to be consistent with verruca plana (Fig. 2). 5% topical imiquimod cream was prescribed for application three times per week before bed. After 2 weeks of therapy the flat warts had almost cleared. The patient did not experience any pain, stinging, redness or edema at the treatment site. Complete clearing of all flat warts occurred after 4 weeks of therapy with 5% topical imiquimod cream (Fig. 1B).

Case 2

A 26-year-old female presented with a 3-year history of multiple papular lesions on both arms, which had not responded to immunotherapy with dinitrochlorobenzene (DNCB). There was no other

Received November 24, 2004

Accepted for publication March 22, 2005

Reprint request to: Hyun Jeong Park, M.D., Ph.D.,
Department of Dermatology, College of Medicine, The
Catholic University of Korea, St. Mary's Hospital, 62
Youido-dong, Youngdeungpo-gu, Seoul 150-713, Korea.
Tel. 82-2-3779-1233, Fax: 82-2-783-7604
E-mail. htpark@catholic.ac.kr

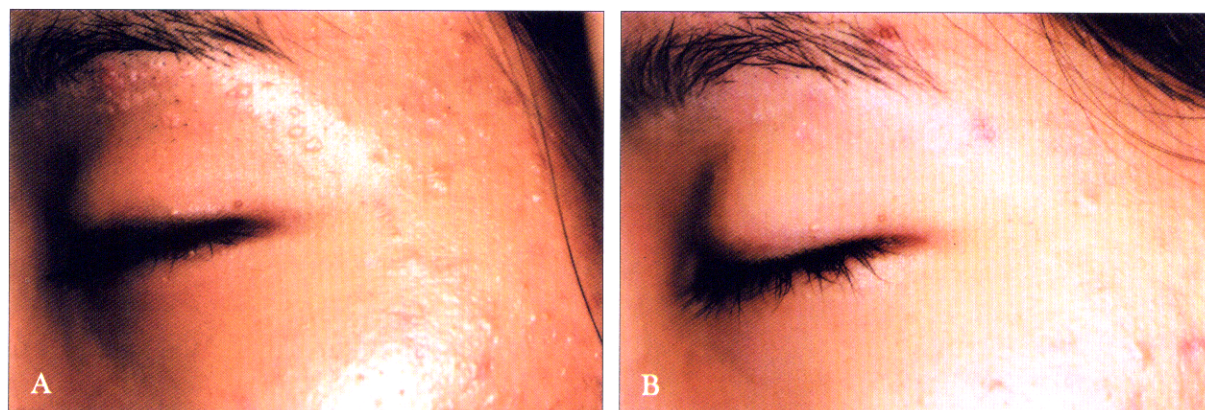


Fig. 1. (A) Flat warts at presentation. (B) Complete clearing of warts after 4 weeks of therapy.

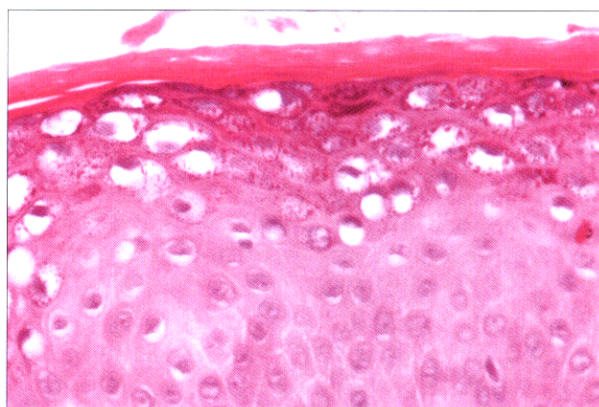


Fig. 2. Compact hyperkeratosis with loss of basket-woven appearance in the stratum corneum is observed together with diffuse vacuolization of the cells in the upper stratum malpighii (Haematoxylin and eosin; original magnification $\times 400$).

personal history to note. Initially, a daily application of 5% topical imiquimod cream was recommended. However, after a week of therapy, the patient complained of burning, erythema, crusting and scabbing of individual lesions, so the application of imiquimod cream was reduced to twice per week. Complete clearance of lesions occurred after 4 weeks of therapy. No other cutaneous or systemic side effects were observed during the rest of the treatment period.

Case 3

A 29-year-old male patient presented with an 8-month history of flat warts on the face. The patient had no specific past or family history. Histopathologic findings from a punch biopsy specimen were

consistent with verruca plana. 5% imiquimod cream was prescribed for application to the face three times per week at bedtime. Marked improvement was noted after one week of therapy, and the lesions completely disappeared after five weeks. The patient did not experience pain or edema at the treatment site. However, erythema and post-inflammatory hyperpigmentation of the lesion site was observed after one week and five weeks of therapy, respectively. After the termination of imiquimod, hyperpigmentation gradually improved, with normalization of skin color within 3 months.

DISCUSSION

Flat warts are benign lesions that occur predominantly in younger patients⁵. They usually disappear spontaneously, but occasionally are long lasting and thus require keratolytic therapy or cryotherapy, which may cause pain or residual scarring. Other treatments for flat warts, such as retinoic acid and immunotherapy with DNCB have been employed. Unfortunately, retinoic acid can sometimes be ineffective and is often not tolerated due to irritation and photosensitivity⁷. DNCB may cause allergic contact dermatitis and has been reported to be a carcinogen⁸.

Imiquimod is an immune-response modifier. In 1997, it was approved by the FDA for the topical treatment of external genital and perianal warts in adults. Imiquimod enhances the body's immune response to HPV infection. Specifically, imiquimod stimulates local peripheral blood mononuclear cells and keratinocytes to secrete cytokines, including

Table 1. Reported Cases of Verruca Plana in Immunocompetent Patients Treated with Imiquimod

	Site of the lesion	Duration	Treatment outcome	Side effects
Patient 1 ⁵ (M/42)	Back of the hands, fingers and lower arms	2 years	Complete disappearance after 6 weeks	None
Patient 2 ⁶ (F/21)	Forehead	2 years	Complete disappearance after 2 weeks	Sore muscles Submental lymphadenopathy
Our case 1 (F/19)	Face	1 month	Complete disappearance after 4 weeks	None
Our case 2 (F/26)	Both arms	3 years	Complete disappearance after 4 weeks	Burning, erythema, crusting and scabbing of the lesions
Our case 3 (M/29)	Face	8 months	Complete disappearance after 5 weeks	Erythema, Hyperpigmentation

interferon- α , tumor necrosis factor and interleukins 1, 6 and 8. These cytokines stimulate local immune effects that are cytotoxic against HPV without causing the tissue destruction characteristic of other treatment methods^{6,9}.

The most common side effect of imiquimod is erythema at the treatment site. This was observed in the 29-year-old male patient after just one week of therapy, but it rapidly improved within a week. The patient also experienced residual hyperpigmentation, which gradually resolved within 3 months of terminating the treatment with imiquimod. Other less commonly experienced adverse effects include local erosions, flaking, scabbing, induration, and edema. Systemic side effects such as flu-like symptoms, headache, and myalgias may appear⁶, but are rare.

Imiquimod represents a unique therapeutic agent in the armamentarium against cutaneous HPV infection. So far, 2 studies of topical imiquimod on flat warts in immunocompetent patients have been reported; one on the fingers and backs of the hands³ and the other on the face of an otherwise healthy female⁶. Both had a favorable outcome. Overall, the treatment was found to be safe, non-irritating, easy-to-use, and resulted in an excellent cosmetic outcome in all 3 of our patients (Table 1). In terms of side effects, imiquimod caused some itching, burning, irritation and pain, but was well-tolerated and spontaneous resolution was observed shortly after application. In conclusion, we believe that imiquimod is a highly suitable method for treating flat warts, especially those on the face, as treatment can be self administered by the patient.

REFERENCES

1. Edwards L, Ferenczy A, Eron L, et al.: Self-administered topical 5% imiquimod cream for external anogenital warts. HPV Study Group. Human Papilloma Virus. Arch Dermatol 1998;134:25-30.
2. Beutner KR, Spruance SL, Hougham AJ, et al.: Treatment of genital warts with an immune-response modifier (imiquimod). J Am Acad Dermatol 1998;38:230-239.
3. Miller RL, Gerster JF, Owens ML, et al.: Imiquimod applied topically: a novel immune response modifier and new class of drug. Int J Immunopharmacol 1999;21:1-14.
4. Suzuki H, Wang B, Shivji GM, et al.: Imiquimod, a topical immune response modifier, induces migration of Langerhans cells. J Invest dermatol 2000; 114:135-141.
5. Oster-Schmidt C: Imiquimod: A new possibility for treatment-resistant verruca plana. Arch Dermatol 2001;137:666-667.
6. Schwab R, Elston D: Topical imiquimod for recalcitrant facial flat warts. Cutis 2000;65:160-162.
7. Borbujo J, Olmos O, Zamora E, Diez Juan-Jose: Treatment of verruca plana with 15% glycolic acid. Int J Dermatol 2000;39:236-240.
8. Lee S, Cho CK, Kim JG, Chun SI: Therapeutic effect of dinitrochlorobenzene (DNCB) on verruca plana and verruca vulgaris. Int J Dermatol 1984; 23:624-626.
9. Eedy DJ: Imiquimod: a potential role in dermatology? Topical review. Br J Dermatol 2002;147: 1-6.